

Dolichocolon: A Narrative Review of an under-Recognized Disorder

Sajad Ahmad Salati^{1*}, MD 

¹Department of Surgery, College of Medicine, Qassim University, KSA

***Corresponding authors:**

Sajad Ahmad Salati, MD; Department of Surgery, College of Medicine, Qassim University, KSA
Email: docsajad@gmail.com

Received: 2025-07-10

Revised: 2025-09-30

Accept: 2025-09-30

Abstract

Dolichocolon is an anatomical variant that is often under-recognized but has significant clinical implications. It is characterized by an abnormally elongated and redundant colon, distinguishing it from megacolon, which involves an increase in the colon's diameter. This condition can cause a wide range of gastrointestinal symptoms, including persistent constipation, abdominal pain, and bloating, and may lead to potentially life-threatening complications such as volvulus. Imaging studies, including contrast studies, are essential for confirming the diagnosis and determining the extent of colonic involvement. Management strategies depend on the patient's clinical status and may be either conservative or surgical. Conservative treatments include lifestyle and dietary adjustments, while surgical options involve partial or total colectomy, performed via open or laparoscopic approaches. This narrative review aims to raise clinical awareness of dolichocolon by providing a comprehensive overview, covering its historical context, pathophysiology, clinical manifestations, diagnostic methods, multifaceted treatment approaches, and current gaps in management.

Keywords: Constipation; Colonic Diseases; Acute Abdomen; Colorectal surgery

Please cite this paper as:

Salati SA. Dolichocolon: A Narrative Review of an under-Recognized Disorder. *Iran J Colorectal Res.* 2025;13(3):76-83. doi: 10.30476/acrr.2025.109107.1272.

Introduction

Dolichocolon is a rare and under-recognized developmental variant characterized by an increased length and resultant redundancy of the colon. This redundancy can involve any part of the large intestine, but is most commonly observed in the sigmoid and transverse colon (1). The term 'dolichocolon' is derived from the Greek word 'dolichos' which means 'long' (1), and the condition is distinct from megacolon, which involves an increase in the diameter of the colon (Figure 1).

Dolichocolon is often discovered incidentally during autopsy or imaging. Its clinical

significance lies in its potential to disrupt normal colonic function and cause serious long-term effects that, if left untreated, may negatively impact a patient's quality of life (QOL) and overall health (2). The inadequate training of medical professionals and the scarcity of scientific literature on dolichocolon contribute to its misdiagnosis and underreporting. Therefore, to raise awareness among healthcare providers, this narrative review has been prepared to provide a comprehensive overview of the historical background, pathophysiology, clinical manifestations, diagnostic modalities, complications, and management of dolichocolon.

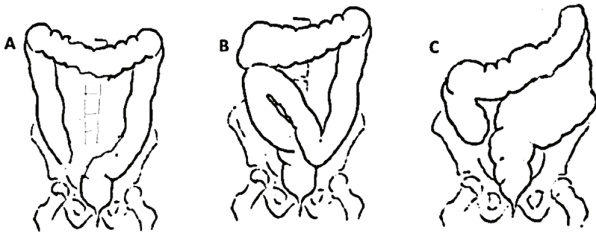


Figure 1: Schematic diagram of colonic morphology. A. Normal colon; B. Dolichocolon; C. Megacolon. (Image credit: Sajad Ahmad Salati)

Historical Background

In 1820, Monterossi created hand-drawn illustrations to depict the increased length of the colon that he observed during autopsies (3). Treves conducted dissections of bodies from patients who died of non-abdominal disorders and concluded that weight, height, or age had no effect on bowel length (4). He suggested that in full-term fetuses, the length of the intestines, especially the colon, was remarkably constant. However, Treves's theory of constancy in colonic length was later disproven by subsequent researchers. Black, through a series of studies, demonstrated that the position and length of the descending colon were variable, while the hepatic and splenic flexures remained fixed (5).

Kienbock was the first to visualize the redundant colon using bismuth contrast radiography (6). He documented an exceptionally long descending and sigmoid colon that originated at the splenic flexure and extended through the abdomen upward beneath the liver, passing distally over the ascending colon and cecum, and finally joining the rectum. In 1914, Lardennois and Aubourg employed a similar methodology to further characterize this redundancy and coined the term 'dolichocolon' to describe the condition (7). White also conducted radiological studies that documented colonic redundancy (8).

Bryant, in 1924, based on cadaveric studies,

conclusively demonstrated significant variation in the length of the small intestine and colon (9). He showed that the colon's length reaches adult proportions by the age of ten. He determined that the average length of the colon was 1.52 m, with a range of 1.25 to 2.00 m. Furthermore, he reported that between the ages of 20 and 80 years, the colon's length increases by almost 20 cm. Phillips et al. studied the colons of 35 cadavers to analyze the relationship between total colonic length, segmental lengths, and mobility at each site in relation to mesenteric attachments (10). They demonstrated that the overall colonic length depends on the length of the rectosigmoid segment and is independent of gender and height.

As shown in Figure 2, three criteria have been established over time to describe dolichocolon. In rare cases, dolichocolon may meet all three criteria (11, 12).

Epidemiology and Etiology

Dolichocolon is often asymptomatic and underdiagnosed, making it difficult to determine its true prevalence. Reported incidence rates in the literature vary widely, ranging from 1.9% to 28.5% in various case series (12). In a roentgenological study of colon morphology and function involving 1,614 cases, Kantor reported a 16.0% incidence in 1934 (13). Conversely, Moeller discovered redundant colons in 18 of 744 cases, corresponding to a 2.4% incidence (14). Larimore studied 562 adults and 116 neonates, finding the incidence to be equal in both age groups at 28.5% (15).

Bryant reported an incidence of 14% based on cadaveric study data (9). The precise cause remains unknown; however, dolichocolon is believed to be a developmental anomaly, with cases documented in fetuses, newborns, and infants (1, 12, 16). Genetic susceptibility is considered a potential contributing factor. Recently, Yik et al. demonstrated colonic redundancy in children with slow-transit

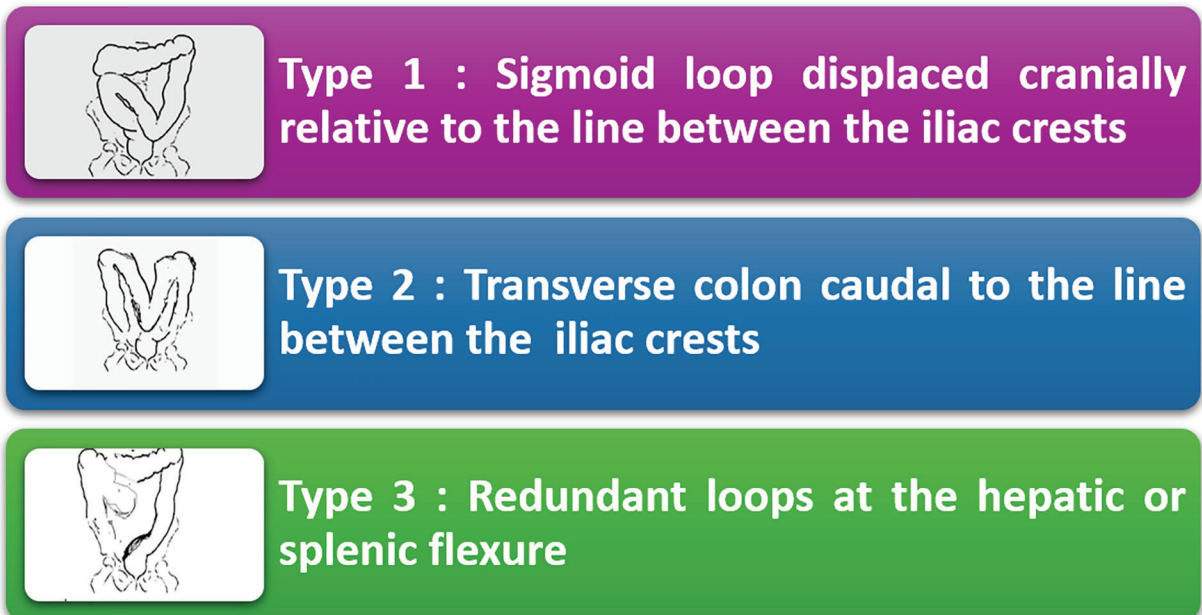


Figure 2: Characteristic criteria of dolichocolon. (Image credit: Sajad Ahmad Salati)

constipation or anorectal retention using nuclear transit scintigraphy (17).

The condition is not specific to any age group, gender, or body habitus, although the symptoms tend to become more noticeable in adults. Some researchers have suggested a relationship with chronic constipation, hypothesizing that straining and persistent fecal retention may eventually lead to colonic elongation. However, dolichocolon is often considered a primary congenital defect that increases the likelihood of chronic constipation (18).

Pathophysiology

The increased length of the colon in dolichocolon results in a prolonged transit time for stool (12, 17, 19, 20), leading to the following pathophysiological consequences:

Increased Water Reabsorption: More water is absorbed from the feces while it remains in the colon, making the fecal mass firmer and larger. As a result, defecation becomes more difficult, contributing to chronic constipation.

Reduced Propulsive Force: The redundant loops and kinks in the colon act as anatomical barriers, obstructing normal propulsive peristaltic waves and resulting in incomplete evacuation.

Increased Risk of Volvulus: An elongated colon is often associated with a failure of fixation of its mesentery to the parietal peritoneum. Consequently, the loose and highly mobile redundant colon carries a potential risk of volvulus, which can lead to intestinal obstruction and compromised blood supply. This is the most severe adverse outcome of dolichocolon and constitutes a surgical emergency.

Clinical Presentation

A significant number of dolichocolon cases are asymptomatic and discovered incidentally. However, symptomatic cases often present a distinctive triad of persistent constipation, abdominal discomfort, and bloating. The symptoms are briefly described as follows:

Chronic Constipation: Constipation is the most common symptom and may not respond to conventional medical treatments (18, 21). In 1962, Brumer and colleagues performed barium enema examinations on 106 patients with chronic constipation and found dolichocolon in approximately 30% of them, compared to only 2% of the 53 control subjects who exhibited a redundant colon (21). The study concluded that there is likely an association between this anatomical anomaly and constipation.

Chronic Abdominal Pain: Colicky pain may be experienced across the lower abdominal quadrants and is often nonspecific and intermittent. Possible causative factors include gas accumulation, fecal impaction, or muscular spasms as the colon strains to propel stool forward.

Abdominal Distension and Bloating: The accumulation of gas and feces in the redundant loops

can cause noticeable fullness in the abdomen.

Non-specific Symptoms: As commonly observed in cases of chronic constipation caused by various factors, fecal stasis in a redundant colon can lead to a range of non-gastrointestinal symptoms, including headache, nausea, weakness, and mild fever. Khalif et al. studied the alterations in colonic flora and intestinal permeability, discovering evidence of stimulation of both humoral and systemic cellular immunity in chronic constipation (22). This included increased levels of circulating immune complexes, T-cell activation, and increased concentrations of antibacterial antibodies IgG and IgM.

Chilaiditi Syndrome: Occurs when a redundant loop of the colon becomes interposed between the liver and the diaphragm, leading to abdominal pain, nausea, or symptoms that mimic various pulmonary or cardiac conditions (23).

Acute Abdomen: Dolichocolon can rarely manifest as bowel obstruction, caused by volvulus, fecalomas, or associated anatomical anomalies such as fibrotic bands (24-29). Brown et al. reported a 23-year-old female who presented to the emergency department with right lower quadrant abdominal pain and underwent an appendectomy for a normal-appearing retrocecal appendix (2). Further abdominal exploration revealed a significantly dilated and chronically adhered sigmoid and proximal ascending colon, as well as a dilated and tortuous transverse colon that descended into the inferior abdomen and pelvis (2). Izquierdo et al. (26) described a 23-year-old male with dolichosigmoid and a giant fecaloma manifesting as acute colonic obstruction accompanied by left hydronephrosis.

Urinary Tract Obstruction: Gielen et al. (16) reported a nineteen-day-old neonate who presented to the emergency department with severe constipation and discomfort. While hospitalized, the infant developed pyelonephritis. A follow-up kidney and bladder ultrasound revealed bilateral hydroureteronephrosis. A dolichocolon was discovered during a barium enema. Treatment with lactulose and enemas resulted in satisfactory resolution of both hydronephrosis and constipation.

Diagnostic Approach

The diagnosis of dolichocolon is primarily based on a combination of clinical suspicion and radiographic confirmation. To exclude other potential causes of chronic constipation and abdominal discomfort, a comprehensive medical history, physical examination, and confirmatory contrast studies are required (30).

a) Radiographic Imaging:

Plain Abdominal X-ray: A plain abdominal X-ray may reveal a large, redundant gut with a significant fecal or gas burden; however, this imaging modality is not definitive (30). In cases of volvulus, a plain X-ray typically shows an inverted U-shaped, gas-filled loop

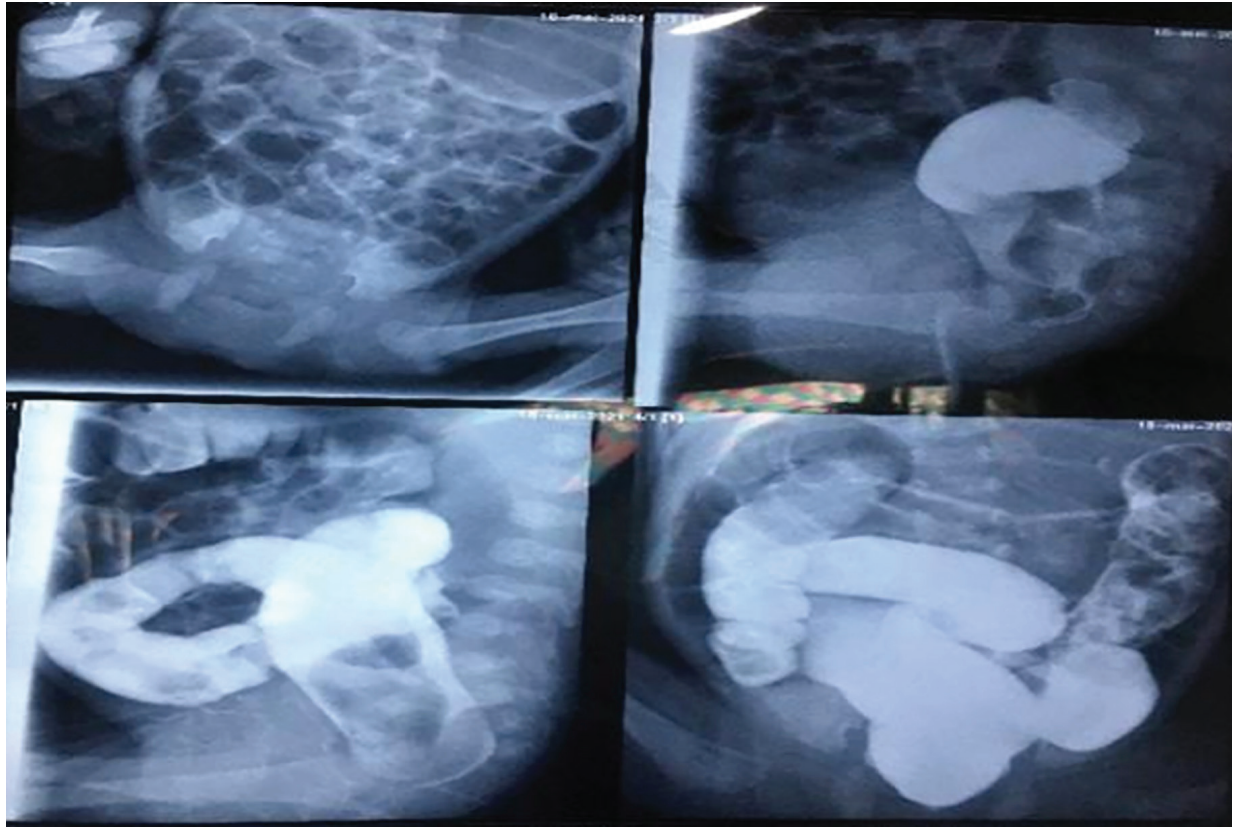

Figure 3: Full-term male neonate; the barium study revealed a dolichosigmoid. (Image credit: Reused from Elouardighi et al., doi:10.30574/wjbphs.2023.14.1.0170. under the terms of the Creative Commons Attribution License, which permits unrestricted use, distribution, and reproduction in any medium, provided the original work is properly cited.)

of dilated colon with a central linear opacity. This radiographic sign is known by several synonyms in the literature, including the “bent-tube,” “omega,” “kidney bean,” or “coffee bean” sign (31). Similarly, in Chilaiditi sign or syndrome, a redundant intestinal loop positioned between the liver and the diaphragm appears as a subdiaphragmatic gas shadow that can mimic pneumoperitoneum (32).

Barium Enema: This contrast study (Figure 3) offers a comprehensive anatomical map of the colon, illustrating its entire length and highlighting any areas of redundancy, looping, or constriction (1, 16, 33).

CT scan: In dolichocolon, a contrast-enhanced CT scan reveals redundancy of the colon (2), as shown in Figure 4.

CT colonography (also known as virtual colonoscopy): It is a relatively new type of CT scan that is becoming increasingly popular. It provides a comprehensive, three-dimensional view of the colon’s lumen and external anatomy, which is particularly useful for assessing the degree of redundancy and excluding other obstructive pathologies (1).

b) Colonoscopy: Colonoscopy can be technically challenging in patients with dolichocolon, although it remains a valuable diagnostic and therapeutic tool for many gastrointestinal disorders. Navigating the colonoscope and reaching the cecum can be difficult due to excessive looping and angulation. These challenges often necessitate the use of a longer endoscope and an experienced endoscopist. Trecca et

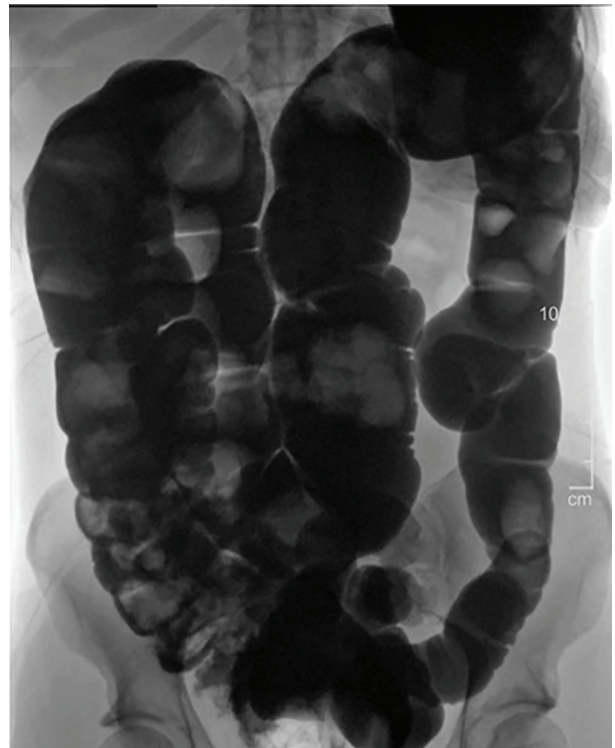

Figure 4: CT Diatrizoate meglumine (DM) enema with air contrast. DM flows retrograde from the rectum to the cecum without evidence of obstruction or mass. (Image credit: Reused from Brown et al. doi : 10.1093/jscr/rjad565. under the terms of the Creative Commons Attribution License, which permits unrestricted use, distribution, and reproduction in any medium, provided the original work is properly cited.)

al. (2020) reported the successful application of robotic colonoscopy in a case of severe dolichocolon (34).

c) Colonic Transit Study: In this functional assessment, the patient is requested to swallow radiopaque markers, followed by multiple abdominal X-rays taken over several days. By objectively measuring the transit time of the markers through the colon, slow-transit constipation associated with dolichocolon can be confirmed (12).

Management

The intensity of symptoms determine how dolichocolon is treated. The approach has remained largely unchanged for the past century, likely because the colon's structural redundancy has been regarded as a trivial observation, and no specific management protocols have been established.

Conservative Management

For asymptomatic individuals or those with mild symptoms that do not significantly impact quality of life (QOL), no specific treatment is necessary. However, a proactive approach is recommended to prevent complications (35). This includes:

Dietary Modifications: A high-fiber diet combined with adequate fluid intake helps soften stools and add bulk, thereby promoting easier bowel movements.

Lifestyle Changes: Engaging in regular physical activity can stimulate intestinal motility and reduce the risk of constipation.

Medical Management

For patients with more severe or refractory symptoms, the following options may be considered to stimulate colonic motility (36).

Laxatives: Over-the-counter laxatives, including bulk-forming agents and stool softeners, can be used to manage constipation.

Prokinetic drugs: Although not considered the primary therapeutic option, certain prokinetics, such as prucalopride, which is licensed for chronic idiopathic constipation, may occasionally be used in conjunction with the conservative methods previously described.

Biofeedback: Biofeedback helps patients learn to coordinate their pelvic floor muscles to improve defecation, thereby alleviating symptoms of constipation. During biofeedback therapy, a machine provides real-time visual or auditory feedback, enabling patients to better understand and control the activity of their abdominal and anal muscles, which enhances their ability to empty their bowels (37).

Surgical Management

Surgical intervention is considered the last resort, reserved for specific severe cases in which conservative treatments fail to produce the desired results and the QOL is severely impacted. Indications for surgery include recurrent volvulus, intractable or refractory constipation, and fecal impaction causing

obstruction. The clinical presentation, along with the location and extent of the dolichocolon, determines the precise surgical technique. A segmental colectomy is performed to remove the redundant portion, with the objective of restoring normal colonic length and function. The surgical approach may be either open or laparoscopic, depending on the patient's clinical presentation and the expertise available at the healthcare facility.

In 1960, Davis reported the outcomes of 14 children who underwent surgery for dolichocolon symptoms that did not improve with conservative treatment (38). Eight patients (57.14%) experienced excellent outcomes, three (21.42%) had good outcomes, and three (21.42%) had fair results; there were no failures. Hollender reported that 11 individuals with dolichocolon achieved good functional outcomes following various colonic resections (39). In 2006, Ripetti et al. reported daily evacuations and pain relief after surgical management in 15 patients with dolichocolon and intractable slow colonic transit constipation (40). The procedures included total laparoscopic colectomy (n=2), total open colectomy (n=6), and left laparoscopic hemicolectomy for left colonic slow transit (n=7). At a mean follow-up of 38 months, 14 of 15 patients attained daily evacuations, experienced pain relief, and showed significant improvements in psychological, emotional, and overall health domains.

Raahave et al. (2010) reported successful outcomes following surgical intervention in 35 patients with slow transit constipation associated with dolichocolon (19). The procedures performed included hemicolectomy (n=21), subtotal colectomy (n=11), and ileostomy (n=3). Abdominal pain was relieved, and defecation frequency improved significantly to 1-4 times per day. However, one patient died, and two experienced an anastomotic leak. Additionally, 11 patients required further surgery due to recurrent constipation. In 2021, Weber-Sanchez et al. reported outstanding results in five female patients, aged 16 to 46, who underwent laparoscopic sigmoidectomy for severe, chronic constipation secondary to dolichocolon (36). All patients achieved relief from abdominal pain and regular daily bowel movements without the need for medication.

In the 1960s, Lucien Deloyers, a renowned Belgian surgeon, introduced the "Deloyers Procedure," a novel surgical technique designed for cases where, after extensive colonic resection, it is difficult or impossible to anastomose the remaining colon stump to the rectum (41). He presented 11 cases, including three left-sided dolichocolons with chronic constipation. The procedure involves an extended left colectomy, mobilization of the right colon, followed by its counterclockwise rotation around the axis of the ileocolic vessels, and the creation of a well-vascularized, tension-free anastomosis. This approach allows the restoration of isoperistaltic intestinal continuity while preserving the ileocecal

valve. The postoperative course was uneventful, with no need for reintervention, and during follow-up, the number of stools per day ranged from one to three. The Deloyers Procedure has been validated as a safe and feasible alternative to total colectomy by numerous researchers (42).

Decompensated Dolichocolon

Shevchenko et al. investigated the morphological and quantitative characteristics of the decompensated stage of dolichocolon by examining the morphogenesis of changes in comparison with histologically normal colon tissue (43). They found that, at the decompensated stage, the colon exhibits signs of irreversible changes, including mucosal atrophy, submucosal thickening accompanied by edema and sclerosis, and hypertrophy of the muscular layer. Furthermore, a significant impairment of motor function is suggested by depletion of the lymphoid apparatus and a considerable reduction in nerve cells within the Auerbach's plexuses.

Shevchenko et al. conducted a similar study and achieved comparable results (44). They concluded that, to prevent decompensation and serious complications, updated objective clinical and morphological indications for surgical treatment are necessary.

Dolichocolon in Neonates

Dolichocolon can cause symptoms during the early neonatal period, necessitating differentiation from more common pediatric colorectal conditions such as Hirschsprung's disease. Elouardighi et al. (33) reported a series of seven neonates, five of whom were premature (between 29 and 36 weeks of gestation) and two full-term with intrauterine growth retardation. Four neonates were female, and three were male. During the first few days of life, the clinical presentation was characterized by constipation and abdominal distension. A barium enema was used to confirm the diagnosis of dolichocolon. All cases were managed conservatively. Gielen et al. (16) described a 19-day-old neonate with dolichocolon who presented with severe constipation and bilateral hydronephrosis, both of which responded to treatment with laxatives and enemas.

Relationship with Rectosigmoid Endometriosis

Constipation, bloating, and persistent stomach pain may be symptoms of both dolichocolon and rectosigmoid endometriosis. The relationship between these two conditions remains unclear. Raimondo et al. conducted a retrospective cohort study involving 113 cases of symptomatic rectosigmoid endometriosis who underwent magnetic resonance imaging (MRI) enema followed by complete surgical excision (45). Dolichocolon was identified in one-third of these patients and significantly impacted surgical outcomes. Specifically, a statistically significant difference ($P < 0.05$) was observed in the

persistence of constipation and bloating, with these symptoms more prevalent in the dolichocolon group compared to the non-dolichocolon group.

Prospects for the Future

The current incidence of dolichocolon is unknown, and no specific management protocols exist, due to a lack of population-based studies and the absence of objective definitions. Consequently, diagnoses generally rely on subjective clinical judgment.

Raahave et al. have recommended assessing prevalence using data from community programs, including colonoscopic cancer screening (12). In this context, tools for estimating colonic length and redundancy, such as electromagnetic capsule tracking systems and MRI, are noteworthy. Mark et al. measured colorectal length and its day-to-day variation using the 3D-Transit approach, which consists of electromagnetic capsules tracked as they move through the digestive tract, and compared these data with anatomical measurements obtained via MRI (46). They found that the 3D-Transit system enables reliable measurement of colorectal dimensions and could potentially be used in studies to improve classification and management protocols.

Sharif et al. argue that the colon length reported in the literature is inaccurate because previous measurements were either derived from cadaveric studies or unphysiological colon preparations (47). They measured the length of the unprepared colon in children with functional constipation (FC) and healthy controls using MRI, demonstrating that the colon was significantly longer in the FC group. They concluded that new objective diagnostic imaging endpoints, such as colon length, could improve understanding of the colon's morphology, physiology, and functional pathology. Additionally, Alqarni et al. emphasized that more physiologically relevant colon data can be obtained using non-invasive, non-destructive diagnostic imaging techniques like MRI (48). They highlighted the critical importance of standardized measurement procedures.

Deloyer's procedure has recently been performed laparoscopically for various colonic disorders (49-51). It is anticipated that this approach will also be adopted for dolichocolon to achieve a tension-free anastomosis following an extended left colectomy.

Conclusion

Dolichocolon is a complicated anatomical variation that is often underdiagnosed, underreported, misinterpreted, and frequently overlooked as a primary diagnosis. Although many individuals live asymptotically with this condition, it is the underlying cause of persistent, debilitating gastrointestinal symptoms in a significant proportion of patients. To prevent misdiagnosis and ineffective treatment, clinicians must develop a deeper understanding of this condition. Successful

management relies on a comprehensive diagnostic approach that combines advanced imaging techniques with a detailed medical history. Conservative treatments should always be the first line of therapy, with surgery reserved only for severe cases or life-threatening complications.

Several factors hinder the optimal management of dolichocolon. These include the absence of standardized diagnostic criteria, validated classification systems, and effective treatment strategies. Most definitions and measurements of the colon are based on cadaveric studies, which do not fully reflect the conditions in living patients.

References

- Seguritan R, Bibawy J, Giaimo T. Redundant: A case of complicated dolichocolon in a neonate. *Radiology case reports*. 2019;14(9):1159-62. Epub 2019/07/31. doi: 10.1016/j.radcr.2019.06.014. PubMed PMID: 31360279; PubMed Central PMCID: PMC6642229.
- Brown KK, Jolley MC, Kocay DA. Appendicitis mimicry of dolichocolon. *Journal of surgical case reports*. 2023;2023(10):rjad565. Epub 2023/10/19. doi: 10.1093/jscr/rjad565. PubMed PMID: 37854520; PubMed Central PMCID: PMC6642229.
- P M. Uber widernatürliche Biegungen des Dickdarms als Uhrfache des Todes neugeborener Kinder. *Deutsch Arch Physiol*. 1820;6:556-71.
- Treves F. Lectures on the Anatomy of the Intestinal Canal and Peritoneum in Man. *British medical journal*. 1885;1(1261):415-9. Epub 1885/02/28. doi: 10.1136/bmj.1.1261.415. PubMed PMID: 20751176; PubMed Central PMCID: PMC6642229.
- Black CE. XI. Displacements of the Colon. *Annals of surgery*. 1912;56(6):888-99. Epub 1912/12/01. doi: 10.1097/00000658-191212000-00011. PubMed PMID: 17862941; PubMed Central PMCID: PMC6642229.
- R. K. Ueber das Sigma elongatum mobile (Röntgenbefund). *Muench Med Wochen*. 1913;60:68-70.
- Lardennois G AP. Allongements segmentaires du gros intestin les dolichocolies. *Jour Radiol Electrol* 1914;1:65-74.
- FW W. The redundant colon. *Med Clin N Am*. 1924;8:1611-33.
- Bryant JTA, JotMS. OBSERVATION UPON THE GROWTH AND LENGTH OF THE HUMAN INTESTINE. 1924;167:499-519.
- Phillips M, Patel A, Meredith P, et al. Segmental colonic length and mobility. *Annals of the Royal College of Surgeons of England*. 2015;97(6):439-44. Epub 2015/08/15. doi: 10.1308/003588415x14181254790527. PubMed PMID: 26274737; PubMed Central PMCID: PMC6642229.
- Dilmaghani S, Lupianez-Merly C, Fetzer J, et al. Colon Volume by Computed Tomography and Scintigraphic Colonic Transit in Constipated Patients With or Without Redundant Colon. *Clinical gastroenterology and hepatology : the official clinical practice journal of the American Gastroenterological Association*. 2024;22(11):2327-9. e2. Epub 2024/05/03. doi: 10.1016/j.cgh.2024.04.009. PubMed PMID: 38697236.
- Raahave D. Dolichocolon revisited: An inborn anatomic variant with redundancies causing constipation and volvulus. *World journal of gastrointestinal surgery*. 2018;10(2):6-12. Epub 2018/03/02. doi: 10.4240/wjgs.v10.i2.6. PubMed PMID: 29492185; PubMed Central PMCID: PMC6642229.
- JL. K. Anomalies of the colon: Their roentgen diagnosis and clinical significance. *Radiology* 1934;23:651-62.
- PF M. The redundant colon. *Acta Radiol*. 1926;6:432-57.
- JW. L. The human large intestine in the newborn and in the adult. *Ann Clin Med*. 1926;5:439-63.
- Gielen L, Raaijmakers A, De Groote B, et al. Dolichocolon Presenting with Bilateral Hydronephrosis in a Neonate. *Case reports in pediatrics*. 2021;2021:6658525. Epub 2021/04/09. doi: 10.1155/2021/6658525. PubMed PMID: 33828868; PubMed Central PMCID: PMC6642229.
- Yik YI, Cook DJ, Veysey D, et al. How common is colonic elongation in children with slow-transit constipation or anorectal retention? 2012;47:1414-20.
- Dzhavadov EA, Kurbanov FS, Tkachenko Iu N. Dolichocolon as a reason of chronic constipation. *Khirurgiia*. 2010(7):25-7. Epub 2010/08/21. PubMed PMID: 20724974.
- Raahave D, Christensen E, Loud FB, et al. Correlation of bowel symptoms with colonic transit, length, and faecal load in functional faecal retention. *Danish medical bulletin*. 2009;56(2):83-8. Epub 2009/06/03. PubMed PMID: 19486620.
- Matar A, Abdelnaem N, Burton D, et al. Redundancy of the Transverse Colon: Documentation of Length and Prolonged Retention. *Clinical gastroenterology and hepatology : the official clinical practice journal of the American Gastroenterological Association*. 2025;23(12):2342-4. e1. Epub 2025/05/13. doi: 10.1016/j.cgh.2025.01.048. PubMed PMID: 40354915; PubMed Central PMCID: PMC6642229.
- Brummer P, Seppala P, Wegelius U. Redundant colon as a cause of constipation. *Gut*. 1962;3(2):140-1. Epub 1962/06/01. doi: 10.1136/gut.3.2.140. PubMed PMID: 13873956; PubMed Central PMCID: PMC6642229.
- Khalif IL, Quigley EM, Konovitch EA, et al. Alterations in the colonic flora and intestinal permeability and evidence of immune activation in chronic constipation. *Digestive and liver disease : official journal of the Italian Society of Gastroenterology and the Italian Association for the Study of the Liver*. 2005;37(11):838-49. Epub 2005/09/20. doi: 10.1016/j.dld.2005.06.008. PubMed PMID: 16169298.
- Moaven O, Hodin RA. Chilaiditi syndrome: a rare entity with important differential diagnoses. *Gastroenterology & hepatology*. 2012;8(4):276-8. Epub 2012/06/23. PubMed PMID: 22723763; PubMed

Ongoing research into the anatomy, pathophysiology, and complex mechanics of dolichocolon is essential to achieve a clearer understanding and to develop more specialized and effective treatment protocols for affected patients.

Authors' Contribution

S.A.S: Design, Acquisition, Drafting of the manuscript and reviewed the final version to be published.

Conflict of interest: No conflict of interest.

- Central PMCID: PMCPMC3380266.
24. Ibrahim R, Houmani A, Nasrallah J, et al. Large bowel obstruction in an adolescent caused by dolichocolon and a fibrotic band of Toldt: A rare case report. *International journal of surgery case reports*. 2025;134:111702. Epub 2025/07/23. doi: 10.1016/j.ijscr.2025.111702. PubMed PMID: 40694929; PubMed Central PMCID: PMCPMC12305333.
 25. Jimena SA. Bowel Obstruction Associated with Dolichocolon. *Arch Hepat Res* 2024;10(1):001-4.
 26. Izquierdo R FM, Michelangeli S, Liscar A, et al. Dolichosigmoid with giant fecaloma as a cause of intestinal obstruction in a young patient. *Rev Venez Cir*. 2025;78(1):72-4.
 27. Mera-Martínez PF R-GJ, Portillo-Mino JD. Megadolichocolon with an unusual presentation in an elderly patient: a case report. *Colomb J Surg*. 2024;35(4):695-8.
 28. Semionkin EI KA, Yudina EA, Lukanin RV, et al. Megadolichocolon in adult. Case report. *Bulletin of Pirogov National Medical & Surgical Center*. 2025;20(2):156-8.
 29. Şimşek Z, Üsküdar O, Deveci M, et al. Acute colonic pseudo-obstruction in acromegalic patient with dolichomegacolon mimicking colonic volvulus. *The Turkish journal of gastroenterology : the official journal of Turkish Society of Gastroenterology*. 2012;23(3):307-8. Epub 2012/07/17. PubMed PMID: 22798128.
 30. Rinebold E, Lee E, Zaniewska K, et al. A rare case of cecal volvulus in a pediatric patient with dolichocolon. *Journal of Pediatric Surgery Case Reports*. 2022;83:102340. doi: 10.1016/j.epsc.2022.102340.
 31. Stavride E, Plakias C. Coffee bean sign: Its meaning and importance. *Clinical case reports*. 2020;8(10):2086-7. Epub 2020/10/23. doi: 10.1002/ccr3.3064. PubMed PMID: 33088563; PubMed Central PMCID: PMCPMC7562879.
 32. Walczak DA, Walczak P, Pawłowska B, et al. Chilaiditi sign in a plain abdominal X-ray - why is it worth remembering? *Przegląd gastroenterologiczny*. 2020;15(1):82-3. Epub 2020/03/28. doi: 10.5114/pg.2020.93635. PubMed PMID: 32215134; PubMed Central PMCID: PMCPMC7089854.
 33. Elouardighi I ZL, El iaziji NA, Barkat A. Dolichocolon in low-birth-weight infants in 7 cases. *World J Biol Pharm Health Sci* 2023;14(01):55-61.
 34. Trecca A, Catalano F, Borghini R. Robotic colonoscopy in a case of severe dolichocolon and the first case of robotic ileoscopy. *Techniques in coloproctology*. 2020;24(6):603-4. Epub 2020/04/06. doi: 10.1007/s10151-020-02205-w. PubMed PMID: 32248364.
 35. Rao SS, Rattanakit K, Patcharatrakul T. Diagnosis and management of chronic constipation in adults. *Nature reviews Gastroenterology & hepatology*. 2016;13(5):295-305. Epub 2016/04/02. doi: 10.1038/nrgastro.2016.53. PubMed PMID: 27033126.
 36. Weber-Sanchez A W-AP, Garteiz-Martine D. Severe chronic constipation due to dolichosigmoid resolved by laparoscopy: a case series report. *EC Gastroenterology and Digestive System* 2021;8(8):34-41.
 37. Chiotakakou-Faliakou E, Kamm MA, Roy AJ, et al. Biofeedback provides long-term benefit for patients with intractable, slow and normal transit constipation. *Gut*. 1998;42(4):517-21. Epub 1998/06/09. doi: 10.1136/gut.42.4.517. PubMed PMID: 9616314; PubMed Central PMCID: PMCPMC1727071.
 38. Davis DA. A new concept in the treatment of symptomatic redundant colon or dolichocolon. *Western journal of surgery, obstetrics, and gynecology*. 1960;68:101-6. Epub 1960/03/01. PubMed PMID: 13814434.
 39. Hollender LF, Muller AM, Viville C, et al. Dolichocolon in adults: surgical indications. *Acta gastro-enterologica Belgica*. 1965;28(7):550-67. Epub 1965/07/01. PubMed PMID: 5844749.
 40. Ripetti V, Caputo D, Greco S, et al. Is total colectomy the right choice in intractable slow-transit constipation? *Surgery*. 2006;140(3):435-40. Epub 2006/08/29. doi: 10.1016/j.surg.2006.02.009. PubMed PMID: 16934606.
 41. L. D. Suspension of the right colon permits without exception preservation of the anal sphincter after extensive colectomy of the transverse and left colon (including rectum). *Technic -indications- immediate and late results*. *Lyon Chir*. 1964;60:404-13.
 42. Costalat G, Garrigues JM, Didelot JM, et al. Subtotal colectomy with ceco-rectal anastomosis (Deloyers) for severe idiopathic constipation: an alternative to total colectomy reducing risks of digestive sequelae. *Annales de chirurgie*. 1997;51(3):248-55. Epub 1997/01/01. PubMed PMID: 9297887.
 43. Shevchenko T, Borota A, Shvorob D, et al. Comparative morphometric characteristics of the dolichocolon decompensated stage. *The Siberian Journal of Clinical and Experimental Medicine*. 2023. doi: 10.29001/2073-8552-2022-461.
 44. Shevchenko T, Borota A, Shvorob D, et al. Morphological and morphometric characteristics of the subcompensated dolichocolon. *Journal of Anatomy and Histopathology*. 2022;11:62-9. doi: 10.18499/2225-7357-2022-11-2-62-69.
 45. Raimondo D, Mattioli G, Casadio P, et al. Frequency and clinical impact of Dolichocolon in women submitted to surgery for rectosigmoid endometriosis. *Journal of gynecology obstetrics and human reproduction*. 2020;49(4):101697. Epub 2020/02/06. doi: 10.1016/j.jogoh.2020.101697. PubMed PMID: 32018043.
 46. Mark EB, Poulsen JL, Haase AM, et al. Assessment of colorectal length using the electromagnetic capsule tracking system: a comparative validation study in healthy subjects. *Colorectal disease : the official journal of the Association of Coloproctology of Great Britain and Ireland*. 2017;19(9):O350-o7. Epub 2017/07/09. doi: 10.1111/codi.13810. PubMed PMID: 28688203.
 47. Sharif H, Hoad CL, Abrehart N, et al. Colon length in pediatric health and constipation measured using magnetic resonance imaging and three dimensional skeletonization. *PloS one*. 2024;19(1):e0296311. Epub 2024/01/03. doi: 10.1371/journal.pone.0296311. PubMed PMID: 38165858; PubMed Central PMCID: PMCPMC10760671.
 48. Alqarni F, Akbar T, Fatani H, et al. Experimental Measurements of the Length of the Human Colon: A Systematic Review and Meta-Analysis. *Diagnostics (Basel, Switzerland)*. 2024;14(19). Epub 2024/10/16. doi: 10.3390/diagnostics14192190. PubMed PMID: 39410595; PubMed Central PMCID: PMCPMC11475704.
 49. Guerra A FO, Alexander O. Laparoscopic Deloyers procedure as a salvage technique for colorectal anastomosis: an alternative to total colectomy. *2023;38(2):217-219. Rev colomb Gastroenterol*. 2023;38(2):217-9.
 50. Sciuto A, Grifasi C, Pirozzi F, et al. Laparoscopic Deloyers procedure for tension-free anastomosis after extended left colectomy: technique and results. *Techniques in coloproctology*. 2016;20(12):865-9. Epub 2016/12/09. doi: 10.1007/s10151-016-1562-z. PubMed PMID: 27928685.
 51. Choi BJ, Kwon W, Baek SH, et al. Single-port laparoscopic Deloyers procedure for tension-free anastomosis after extended left colectomy or subtotal colectomy: A 6-patient case series. *Medicine*. 2020;99(31):e21421. Epub 2020/08/07. doi: 10.1097/md.00000000000021421. PubMed PMID: 32756144; PubMed Central PMCID: PMCPMC7402770.