


## Melanosis Coli: Diagnosis, Clinical Significance, and Prognosis in Colorectal Screening

Sahil Sabharwal<sup>1</sup>, MD,  Kemmian Johnson<sup>2</sup>, MD; Brandyn Young<sup>3</sup>, BS; Sarah Assem<sup>1</sup>, MD; Ragesh Thandassery<sup>2</sup>, MD

<sup>1</sup>Department of Internal Medicine, University of Arkansas for Medical Sciences, Northwest Regional Campus, Fayetteville, Arkansas, United States

<sup>2</sup>Department of Gastroenterology, University of Arkansas for Medical Sciences, Little Rock, Arkansas, United States

<sup>3</sup>University of Arkansas for Medical Sciences, College of Medicine, Fayetteville, Arkansas, United States

### \*Corresponding authors:

Sahil Sabharwal, MD; Department of Internal Medicine, University of Arkansas for Medical Sciences, Northwest Regional Campus, 1125 N College Ave., Postal code: 72703, Fayetteville, Arkansas, United States. Tel: +479 7138000; Email: sahilabh12@gmail.com

Received: 2024-10-29

Revised: 2024-12-29

Accepted: 2024-12-29

### Abstract

Melanosis coli is a generally benign condition characterized by brown-black pigmentation of the colonic mucosa. It is classically associated with the prolonged use of anthraquinone laxatives, with senna and cascara being the most commonly utilized agents. The accumulation of the pigment lipofuscin within macrophages in the colonic lamina propria has been observed with long-term use of anthranoid laxatives. This phenomenon is consistent with the classic discoloration of the colon for which this condition is known, often observed during colonoscopy. The following case report focuses on a 55-year-old woman with a medical history that includes hypertension, uterine hypertrophy, menorrhagia, migraine, and constipation, who presented for a screening colonoscopy. It addresses the challenges in diagnosing melanosis coli and discusses its clinical significance based on a review of the relevant literature. This case review and literature search summarize information regarding the management and prognosis of melanosis coli in the context of colorectal cancer screening and the detection of adenomas.

**Keywords:** Colonoscopy, Melanosis Coli, Screening Colonoscopy

Please cite this paper as:

Sabharwal S, Johnson K, Young B, Assem S, Thandassery R. Melanosis Coli: Diagnosis, Clinical Significance, and Prognosis in Colorectal Screening. *Iran J Colorectal Res.* 2024;12(4):128-132. doi: 10.30476/acrr.2025.105685.1240.

### Introduction

Melanosis coli is a generally benign condition characterized by brown-black pigmentation of the colonic mucosa. It is classically associated with the prolonged use of anthraquinone laxatives, with senna and cascara being the most commonly used agents in this category. Their widespread use for constipation is attributed to their potent action in

stimulating peristalsis, which enhances the propulsion of contents through the colon. Accumulation of the pigment lipofuscin within macrophages in the colonic lamina propria has been observed with long-term use of anthranoid laxatives. This finding is consistent with the classic discoloration of the colon for which this condition is known, often observed during colonoscopy (1). Patients without symptoms may also typically present with gastrointestinal complaints that

are unrelated to the disease process.

One of the most commonly diagnosed causes of melanosis coli is chronic constipation with subsequent overuse of over-the-counter laxatives. Melanosis coli has also been observed in individuals with irritable bowel syndrome and other functional gastrointestinal disorders, which may lead to chronic use of laxatives (2). Additionally, some individuals misuse laxatives in an attempt to manage eating disorders, such as anorexia and bulimia. Generally, melanosis coli is considered benign and tends to improve or resolve when laxative use is discontinued in most cases. Recently, there has been increased interest in melanosis coli due to concerns regarding its association with a higher incidence of adenomas and, in one case, colorectal carcinoma (3-5).

Melanosis coli pigmentation typically does not interfere with normal physiological functions and is therefore asymptomatic. However, it serves as a valuable diagnostic aid during colonoscopic examinations. In these procedures, the contrast between adenomas or polyps and the surrounding colonic mucosa is enhanced, as the regions of depigmentation appear against the much darker coloration of the mucosa. This distinction improves the sensitivity for detecting small polyps (6), which often go unnoticed but are associated with adenomas. Although most of these lesions are

benign and linked to colorectal adenomas, further investigation is warranted regarding their association with colorectal carcinoma. There is limited research on whether melanosis coli is related to an increased risk of cancer (7).

The following case report discusses the challenges in diagnosing melanosis coli and highlights its clinical significance based on a review of the relevant literature. This case review and literature search summarize information regarding the management and prognosis of melanosis coli in the context of colorectal cancer screening and the detection of adenomas.

### Case Presentation

The patient is a 55-year-old woman with a history of hypertension, uterine hypertrophy, menorrhagia, migraines, and constipation, presenting for a screening colonoscopy. She recently had a positive fecal immunochemical test (FIT), which prompted the need for colonoscopy. For her constipation, she has been taking polyethylene glycol at a standard over-the-counter dose of 17 grams daily on an as-needed basis for approximately six months. During the examination, the quality of the colon preparation was good (Figures 1-9), and the scope was advanced until direct visualization of the cecum was achieved.

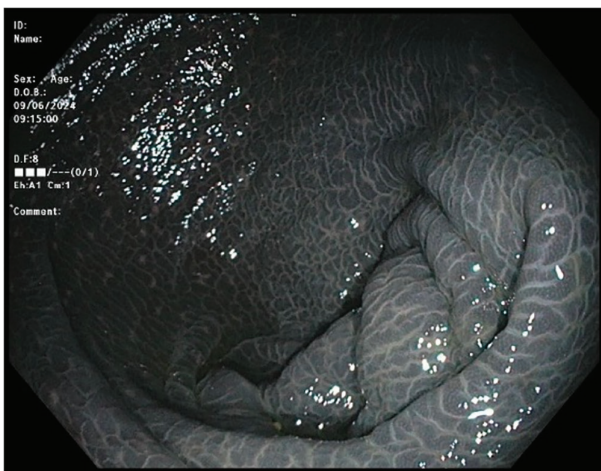


Figure 1: Extensive melanosis coli is observed in the cecum.

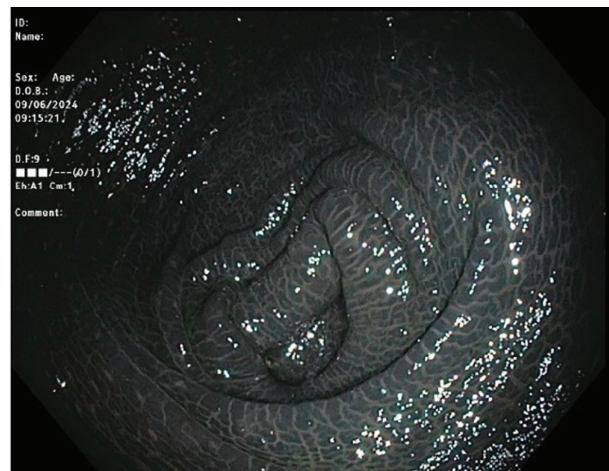


Figure 2: Extensive melanosis coli is observed in the proximal ascending colon.

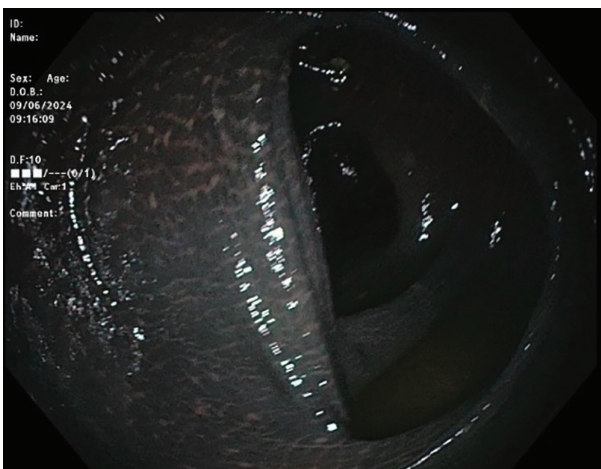
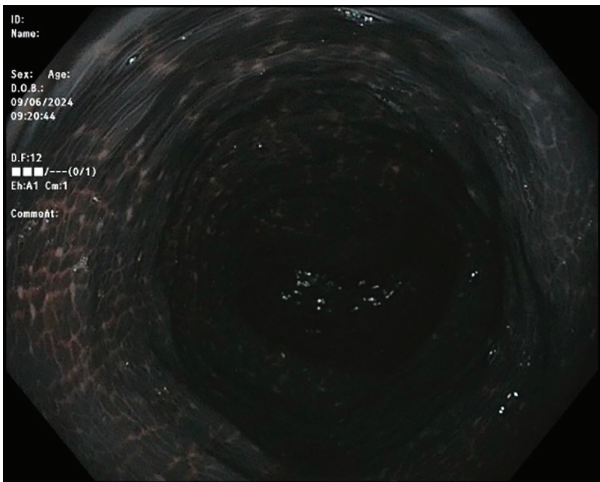


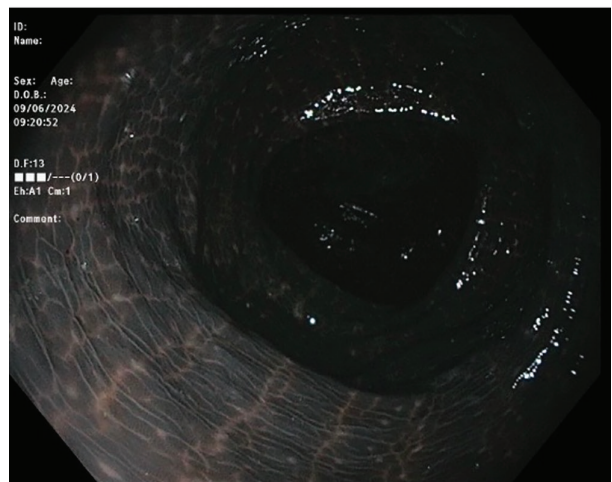
Figure 3: Extensive melanosis coli is observed in the distal portion of the ascending colon.

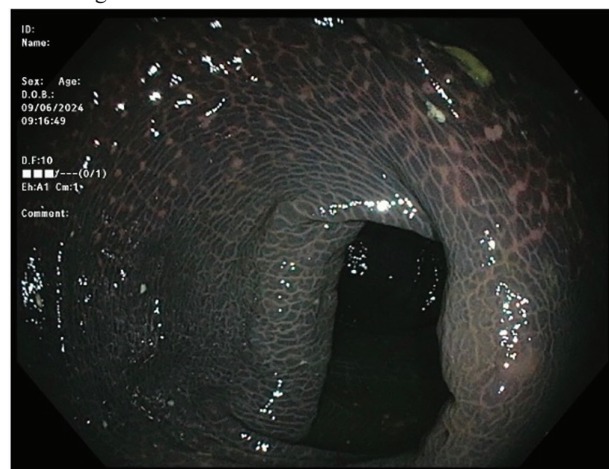

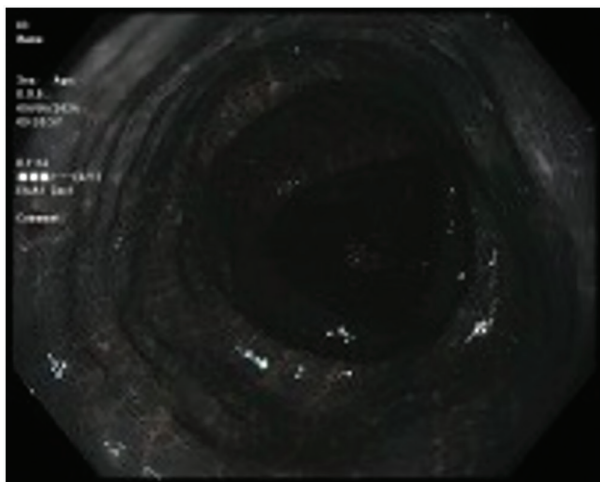
Figure 4: Extensive melanosis coli is observed in the mid-transverse colon.



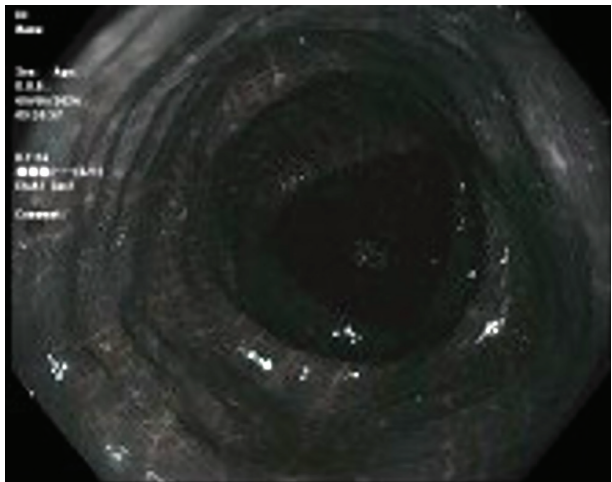
**Figure 5:** Extensive melanosis coli is observed in the distal transverse colon.



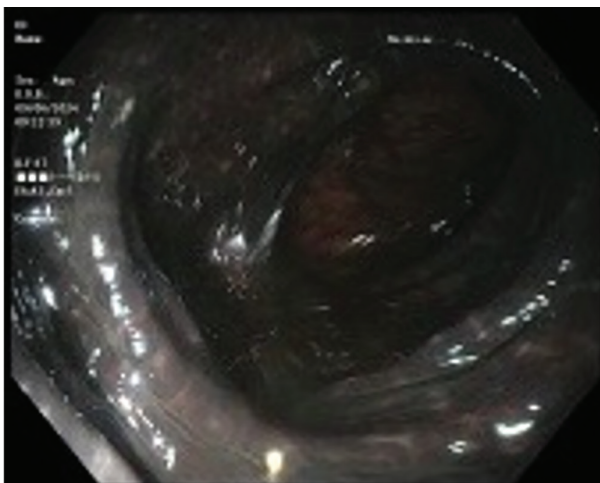
**Figure 6:** Extensive melanosis coli is observed in the proximal descending colon.



**Figure 7:** Extensive melanosis coli is observed in the proximal descending colon.



**Figure 8:** Extensive melanosis coli is observed in the sigmoid colon.



**Figure 9:** Extensive melanosis coli is observed at the sigmoid flexure.

Extensive melanosis coli was observed throughout the colonoscopy (Figures 1-9). However, the remainder of the colonoscopy was unremarkable. The patient has been scheduled for a repeat colonoscopy in 10 years.

## Discussion

Melanosis coli is most commonly associated with

the use of anthraquinone laxatives; however, some studies indicate an increased incidence of adenoma detection, while others suggest that this may be an artifact resulting from a contrast effect rather than a genuine carcinogenic process. We challenge this perspective by identifying associations with polyethylene glycol use, which raises the possibility that additional pathways—such as anthraquinone-induced apoptosis or lifestyle factors—may be involved. Although average-risk patients are appropriately monitored with screening intervals of 10 years, further investigations are needed to clarify whether melanosis coli increases individuals' vulnerability to neoplasia or merely enhances the visibility of lesions.

Because this patient had no significant risk factors—such as multiple polyps, a substantial family history, or findings of advanced adenomas—she was advised to undergo a repeat colonoscopy in ten years. Although melanosis coli is generally considered a benign condition, there may be occasions when it is reasonable to increase the frequency of colonoscopy surveillance in the presence of other risk factors for colorectal polyps and low-grade adenomas (2). This presentation may be attributed to the association of melanosis

coli with chronic laxative abuse. Reducing or discontinuing the use of anthranoid laxatives for an extended period, along with implementing alternative strategies for managing constipation, may help diminish pigmentation in the colon.

The patient was advised to reduce or discontinue the use of laxatives. Recommendations also included adjusting dietary fiber intake, increasing fluid consumption as needed, and incorporating regular exercise to promote consistent bowel movements.

Melanosis coli is characterized by the darkening of the colonic mucosa due to the accumulation of lipofuscin within macrophages. Some reports suggest that this condition is associated with an increased incidence of adenoma detection during colonoscopy. Additionally, several studies have demonstrated that melanosis coli enhances the contrast between lighter-appearing adenomatous polyps and the darker mucosal tissue, thereby improving the visualization of adenomas (2, 6). Since colonic melanosis is primarily asymptomatic, it is often discovered incidentally during routine colonoscopy performed for other reasons. The dark pigmentation of the colonic mucosa is the main clinical manifestation observable through ocular examination of the colon. This coloration is typically uniform and often involves pigmentation throughout the entire colon (8).

The pathogenesis of melanosis coli is primarily attributed to the chronic use of cathartic laxatives, which induces apoptosis in the colonic epithelium. Although not always present, this process leads to an increased accumulation of lipofuscin-pigment-laden macrophages within the lamina propria (1). Lipofuscin is a golden-brown pigment that accumulates intracellularly as a secondary effect of apoptosis. It resides in the cytoplasmic compartment of the macrophage. The progressive accumulation of this pigmentation occurs over an extended period, ultimately leading to a pronounced darkening of the colonic mucosa (9). The scattering of pigment-laden macrophages usually occurs within the lamina propria of the biopsy specimen.

Polyps and adenomas associated with melanosis coli may be easier to detect because the darkly pigmented mucosa offers a strong contrast against non-pigmented lesions (6). However, this characteristic does not particularly indicate an increased risk of malignancy.

Melanosis coli is occasionally misdiagnosed in patients with other gastrointestinal conditions. For instance, a diagnosis of inflammatory bowel disease or ischemic colitis may be made in the absence of a history of laxative use. The degree of pigmentation in melanosis coli can result in an overestimation of disease severity, potentially leading to unnecessary treatments (10).

Hyperpigmentation can also lead to delays in the detection and treatment of coexisting conditions that are typically easily recognizable, such as polyps and

adenomas. Although melanosis coli discoloration can sometimes facilitate the identification of these adenomas, a missed diagnosis of melanosis may lead to obscured diagnoses and, consequently, delayed treatment (2).

Colonoscopy remains the gold standard confirmatory test for the diagnosis of melanosis coli. It facilitates optimal visualization of the characteristic pigmentation of the colonic mucosa. When feasible, diagnosis can be enhanced through high-definition colonoscopy, biopsy, histopathological analysis, and chromoendoscopy. These techniques are particularly useful in differentiating melanosis coli from the other colonic disorders that exhibit variable pigmentation, along with identifying relevant inflammatory markers detectable through biopsy and subsequent histopathological analysis. Kassim et al. found a statistically significant correlation between melanosis coli and the diagnosis of hyperplastic polyps and low-grade adenomas, which warrants colonoscopic surveillance (11).

Characteristics such as age, female sex, inpatient setting, a diagnosis of melanosis, a personal history of polyps, and positive fecal occult blood tests are all significant factors influencing the polyp detection rate (7).

In most cases of melanosis coli, no specific therapeutic measures are required. The colonic pigmentary change is usually reversible and resolves within a few months to a year after discontinuing laxative use. Therefore, conventional treatment is non-surgical and focuses on lifestyle and dietary modifications.

When an adenoma or any other neoplastic lesion is identified, polypectomy may be necessary. The characteristics associated with the lesions are far more significant in guiding clinical decisions than the presence of melanosis.

The prognosis for this condition is very favorable, as it is benign and reversible in nature. However, some literature indicates an increased incidence of polyps and low-grade adenomas in patients with melanosis coli. This finding suggests benefits of more frequent colonoscopic follow-up. A study published by Liu et al. in 2017 reported a significantly higher incidence of colorectal polyps among patients with melanosis coli compared to age- and sex-matched control patients. Melanosis coli is a colonic pathology that can easily progress to an adenoma. While there is no evidence suggesting a specific risk for colorectal cancer, these patients should be carefully monitored over a reasonable timeframe.

As a single case report, the generalizability of the findings is limited. Melanosis coli often presents asymptotically, making diagnosis frequently an incidental finding in clinical practice. This can lead to potential underdiagnosis and an inaccurate estimation of the true prevalence of the condition. Furthermore, variations in laxative use among individuals, along

with potential biases in self-reported consumption due to reliance on memory recall, can complicate the analysis of cause-and-effect associations. Enhanced visualization of polyps, resulting from the contrast effect in melanosis coli, is plausible. Additional confounding factors may include dietary practices, genetically influenced traits, and various colonic conditions related to colonic pigmentation or adenoma development that have not been considered in this study.

Further studies would be beneficial in more definitively establishing the role of melanosis coli in the development of adenomas and polyps. Researchers should explore more sensitive methods for the early diagnosis of melanosis coli to prevent later complications associated with the disease. Modern imaging techniques, utilizing machine learning algorithms and pattern recognition, may facilitate earlier detection of patients with melanosis coli. The further development of these powerful and effective screening tools will be particularly important for enhancing patient management and preventing colorectal pathologies (9).

## Conclusion

By presenting this case, we address the

## References

- Ezike, K., Okwudire-Ejeh, I., Salu, I., Nnabuchi, C., Aghahowa, M. E., Ani, F. O., & Isaac, H. M. (2023). Biopsy-proven melanosis coli initially diagnosed as candidiasis on colonoscopy: A report of two cases from North Central Nigeria. *Cureus*.
- Kuriyama, A. (2021). Melanosis coli. *JMA Journal*.
- Blackett, J. W., Rosenberg, R., Mahadev, S., Green, P. H. R., & Lebowohl, B. (2018). Adenoma Detection is Increased in the Setting of Melanosis Coli. *Journal of clinical gastroenterology*, 52(4), 313–318. <https://doi.org/10.1097/MCG.0000000000000756>
- Tsobanidou C.h (2005). Melanosis coli in two patients with colorectal neoplasia. *Journal of B.U.ON. : official journal of the Balkan Union of Oncology*, 10(1), 131–133.
- Nusko, G., Schneider, B., Ernst, H., Wittekind, C., & Hahn, E. G. (1997). Melanosis coli--a harmless pigmentation or a precancerous condition?. *Zeitschrift fur Gastroenterologie*, 35(5), 313–318.
- Blackett, J. W., Rosenberg, R., Mahadev, S., Green, P., & Lebowohl, B. (2016). Adenoma detection is increased in the setting of melanosis coli. *Journal of Clinical Gastroenterology*.
- Abu Baker, F., Mari, A., Feldman, D., Suki, M., Gal, O., & Kopelman, Y. (2018). Melanosis coli: A helpful contrast effect or a harmful pigmentation? *Clinical Medicine Insights: Gastroenterology*.
- Kew, S., & Chakravarthi, S. (2013). Images in clinical medicine: Melanosis coli. *The New England Journal of Medicine*.
- Lo, C. M., Chen, C. C., Yeh, Y. H., Chang, C., & Yeh, H. J. (2020). Quantitative analysis of melanosis coli colonic mucosa using textural patterns. *Applied Sciences*.
- Zapatier, J., Schneider, A., & Parra, J. (2010). Overestimation of ulcerative colitis due to melanosis coli. *Acta Gastroenterologica Latinoamericana*.
- Kassim, S. A., Abbas, M., Tang, W., Wu, S., Meng, Q., Zhang, C., Naeem, S., Li, X., & Chen, R. (2019). Retrospective study on melanosis coli as risk factor of colorectal neoplasm: A 3-year colonoscopic finding in Zhuhai Hospital, China. *International Journal of Colorectal Disease*.

challenges associated with diagnosing melanosis coli and summarize information regarding the management and prognosis of this condition. Melanosis coli has recently garnered diagnostic interest due to its association with an increased prevalence of adenomas observed during colonoscopy; therefore further studies on this topic are warranted.

## Authors' Contribution

All authors contributed to the concept and design of the work; S.S. prepared the figures, while S.S. and B.Y. wrote the main manuscript. All authors reviewed the final version, approved the work for publication, and agreed to be accountable for all aspects of the work.

## Third Party Material/Consent for Publication:

All of the material is owned by the authors and/or no permissions are required. Patient consent was obtained.

**Source of funding:** This study did not receive any funding.

**Conflict of interest:** None declared.