

Role of Laparoscopy in Pediatric Adhesive Intestinal Obstruction: Our Experience in a Tertiary Care Centre

Sheetal Upreti^{1*}, MS, MCh; Sanjay Kumar Pal², MS; Gaurav Saxena², MS, DNB; Sujoy Neogi², MS DNB; Simmi K Ratan², MS, MCh; Prafull Kumar², MS, MCh; Chiranjiv Kumar², MS, MCh

¹Department of Pediatric Surgery, Postgraduate Institute of Child Health, Noida, India

²Department of Pediatric Surgery, Maulana Azad Medical College, India

*Corresponding authors:

Sheetal Upreti, MS, MCh; 508/3, Tower 5, Department of Pediatric Surgery, Postgraduate Institute of Child Health, Noida, India. PIN CODE 201303. Tel: +91 9811084875; Email: sheetal.upreti@gmail.com

Received: 2024-07-28

Revised: 2024-10-21

Accept: 2024-11-19

Abstract

Background: Postoperative adhesive intestinal obstruction is a common complication following laparotomy, which may require operative intervention in certain cases. This study aims to evaluate the feasibility and safety of laparoscopic adhesiolysis in pediatric patients.

Methods: A retrospective study was conducted over a one-year period from January 2023 to January 2024, involving children with adhesive intestinal obstruction who were managed at a single unit in the Department of Pediatric Surgery at Maulana Azad Medical College, New Delhi. The data collected included patient demographics, details of conservative treatment, types of surgery performed, and postoperative outcomes. Surgical conversions and complications were also documented.

Results: Twelve patients (58.3% male, 41.7% female) were included in the study. Initial conservative management was attempted for all patients; however, three (25%) ultimately required surgical intervention. All surgeries were performed via laparoscopic adhesiolysis without conversion to open surgery. Additionally, one patient underwent laparoscopic excision of Meckel's diverticulum. Oral intake was initiated within 24 hours postoperatively, and all patients were discharged within 48 hours. The mean operative time was 56.2 minutes, the time to the first feed was 18.4 hours, and the average hospital stay was 42.5 hours. No postoperative complications were observed.

Conclusion: Laparoscopic adhesiolysis may be a safe and effective treatment for pediatric adhesive intestinal obstruction, providing minimal morbidity and facilitating early recovery. This approach presents a viable alternative to open surgery in selected cases.

Keywords: Adhesive obstruction, Adhesiolysis, Laparoscopy

Please cite this paper as:

Upreti S, Pal SK, Saxena G, Neogi S, Ratan SK, Kumar P, Kumar C. Role of Laparoscopy in Pediatric Adhesive Intestinal Obstruction: Our Experience in a Tertiary Care Centre. *Iran J Colorectal Res*.

Introduction

Postoperative adhesive intestinal obstruction is a common complication following laparotomy and accounts for a significant proportion of hospital

admissions. The reported incidence of adhesive obstruction ranges from 1% to 5%.¹ This rate is higher in cases following neonatal laparotomy, with estimates around 6% to 8%.² Although conservative management with close observation is the preferred

initial approach for these cases, surgical intervention is required in approximately 35% to 45% of instances.¹ There is no clear consensus regarding the surgical approach—whether to use laparotomy or laparoscopy for management. While numerous studies in adults demonstrate the feasibility and safety of laparoscopic adhesiolysis, there is a lack of data concerning the pediatric population. In our study, we conducted a retrospective follow-up of cases of adhesive obstruction in which laparoscopic adhesiolysis was performed. The aim of this study was to evaluate the feasibility and safety of laparoscopic adhesiolysis in the pediatric population.

Patients and Methods

This retrospective study was conducted over a one-year period (from 2023 to 2024) in a single unit within the Department of Pediatric Surgery at Maulana Azad Medical College, New Delhi, India. The study reviewed children with adhesive intestinal obstruction and followed their management. Children under the age of 12 who were admitted with a diagnosis of adhesive obstruction in the past year and who initially received conservative treatment were included in the study. Patients exhibiting hemodynamic instability, requiring inotropic support, or showing signs of bowel ischemia or perforation that necessitated urgent surgery upon admission were excluded. Data collected included demographic information, details of conservative management, types of surgery performed, and operative findings. Instances of conversion to open surgery, when necessary, were also documented. The postoperative course was monitored in terms of length of hospital stay, duration of postoperative nasogastric decompression, timing of first feeds after surgery, time to bowel movement or passage of flatus, and any occurrences of recurrence. Data were recorded as mean values. Signed consent forms were obtained from the guardians of all enrolled patients. Reason: Improved clarity, readability, and technical accuracy while correcting grammatical and punctuation errors.

Results

Patient Characteristics

A total of 12 patients were identified over the past year. Among them, there were 7 boys (58.3%) and 5 girls (41.7%). According to departmental policy, children exhibiting no signs of bowel ischemia were initially managed conservatively for 48 hours. Conservative management included intravenous fluid replacement, placement of a nasogastric tube for drainage, monitoring of electrolytes, and close observation of vital signs and abdominal symptoms, including abdominal girth. All patients had previously undergone surgery and presented with symptoms of intestinal obstruction. The past surgical procedures

included stoma closure (33%), appendectomy (50%), trauma surgery (8%), and perforation repair (8%). Of the 12 patients, 3 did not respond to conservative management, necessitating surgical intervention. Among those who underwent surgery, two patients had post-appendectomy adhesive obstructions, while the third child had previously undergone multiple laparotomies for traumatic perineal injury and had received a Mitrofanoff procedure for bladder drainage (Figure 1).

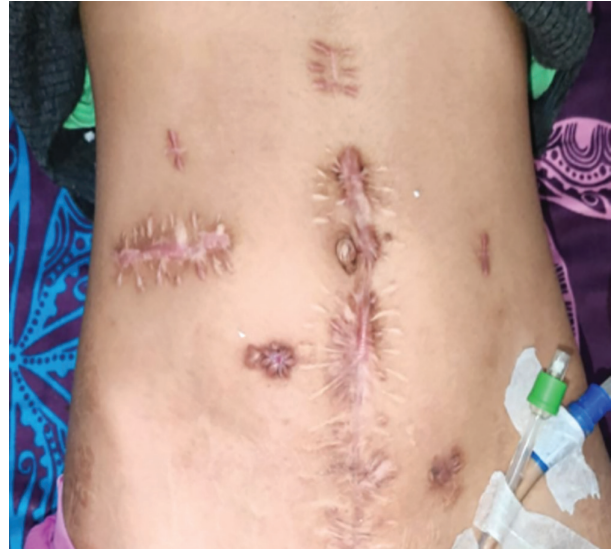


Figure 1: Shows a clinical image of the abdomen of a child who was previously undergone surgery for a traumatic perineal injury.

Management

All patients who failed conservative management were scheduled for laparoscopic adhesiolysis (Figure 2). All three patients were successfully managed with laparoscopy, and none required conversion to an open procedure. In one post-appendectomy patient, Meckel's diverticulum was identified during adhesiolysis and was excised laparoscopically. An extracorporeal anastomosis was performed using linear staplers after the bowel was extracted through the umbilical port site; the incision was extended by only 2 cm for this purpose. All patients were initially managed with a nasogastric tube, which was subsequently assessed for removal on the next postoperative day.

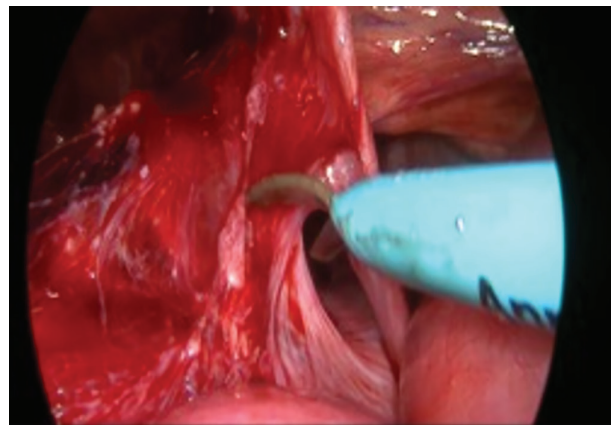


Figure 2: Shows an image of laparoscopic adhesiolysis.

Outcome

All children were allowed to resume oral intake after the removal of the nasogastric tube within 24 hours of the procedure and were discharged within 48 hours. The mean operative time was 56.2 minutes. The mean time to initiate feeds was 18.4 hours, and the mean hospital stay was 42.5 hours. The mean time to the first flatus or bowel movement was 24 hours. In all patients, the nasogastric tube (NG) was removed within 24 hours of surgery, with no need for reinsertion or instances of vomiting in any of the cases. There were no complications related to wound infection, intra-abdominal collection, or sepsis. Patients were followed up in the outpatient clinic after discharge for 6 weeks, with no recurrence observed.

Discussion

The efficacy and safety of laparoscopic adhesiolysis have been established in the adult population. Numerous studies support the use of laparoscopy in adults, leading to an increasing number of cases being successfully managed with laparoscopic adhesiolysis. Although there is a limited amount of literature regarding the pediatric population, the trend is gradually shifting towards minimally invasive procedures. This study highlights the safety and efficacy of laparoscopic adhesiolysis in pediatric patients requiring surgical intervention. All patients who required surgery were successfully managed laparoscopically.

There have been several studies examining laparoscopic adhesiolysis in pediatric patients. Tan et al. followed 10 children who required adhesiolysis after undergoing a previous laparotomy.³ Two children needed revision surgeries, while no conversions to open surgery were performed. They described the adhesiolysis procedure in three steps: first, separating the adhesions from the parietal wall; second, detaching the omentum from the underlying bowel; and finally, the bowel from distal to proximal to free any inter-bowel adhesions. They concluded that extensive adhesiolysis can be performed laparoscopically. In our study, we followed three patients who required laparoscopic adhesiolysis. One of the patients had multiple scars from previous surgeries (specifically, a patient treated for perineal trauma). Despite this, laparoscopy was feasible and safe for this patient, with no intraoperative iatrogenic injuries reported.

Lee et al. conducted a study analyzing a population database for pediatric adhesive obstruction.⁴ Approximately 11% of the patients in the study underwent laparoscopic adhesiolysis. Additionally, a trend toward an increased use of laparoscopy for adhesiolysis was observed over time. The complication rates were found to be lower, with a reduced economic burden for patients undergoing

laparoscopic adhesiolysis compared to those who had open surgery. Similarly, a meta-analysis conducted by Apelt et al.⁵ revealed that pediatric surgeons proficient in advanced laparoscopic techniques demonstrate both safety and high effectiveness when treating pediatric small bowel obstruction using minimally invasive methods. They concluded that laparoscopy should be considered the preferred approach for managing this condition in children. Miyake et al. found in their meta-analysis that laparoscopy for adhesive intestinal obstruction is associated with fewer postoperative complications compared to laparotomy.¹ Patwardhan et al. conducted a study identifying cases in a statewide database involving patients under 18 years of age. In their study, 30% of the patients underwent laparoscopic adhesiolysis, which resulted in decreased overall complications.² Although our study was conducted with a small number of patients, it reflected that the use of laparoscopy for adhesiolysis was associated with fewer complications and a shorter hospital stay.

Laparoscopic adhesiolysis is associated with reduced morbidity.¹⁻⁵ As observed in one of our patients with multiple surgeries for traumatic perineal injury, laparotomy would have resulted in significant morbidity and the potential for iatrogenic injuries. This child also had a Mitrofanoff channel in place for bladder drainage. Laparoscopic adhesiolysis proved to be extremely beneficial, as adhesions could be safely removed under good magnification. However, placing the first port can be challenging due to adhesions, which may lead to inadvertent injuries. Utilizing an open technique to place the first port, away from the scarred area, may help overcome this obstacle. Various studies have demonstrated that favorable outcomes with the laparoscopic approach can be achieved by more experienced surgeons.⁵ Diagnostic laparoscopies to identify pathology and the cause of obstruction consistently prove to be superior to large laparotomy incisions.⁶ In cases of dense adhesions and complex pathology, the procedure can always be converted to open surgery.

The limitations of this study include its retrospective design and the small number of participants. Only three patients required surgical intervention and were included in the study. Although these patients were successfully treated with minimal morbidity and a short length of hospital stay, the small study population limits the generalizability of the findings. Future prospective studies with a larger number of participants are needed to validate the results of the present study.

Conclusion

In our study, we found laparoscopic adhesiolysis to be both safe and feasible for cases of adhesive obstruction that require surgical intervention.

Acknowledgment: None

Conflict of interest: None declared.

Source of funding: Nil

Authors' Contribution

All authors are guarantors and participated in the

study design, analysis and interpretation of data, as well as drafting and reviewing it critically; All authors read and approved the final manuscript and provided an agreement to be accountable for all aspects of the work in ensuring that questions related to the accuracy or integrity of any part of the work are appropriately investigated and resolved.

References

1. Miyake H, Seo S, Pierro A. Laparoscopy or laparotomy for adhesive bowel obstruction in children: a systematic review and meta-analysis. *Pediatr Surg Int.* 2018;34:177-82.
2. Patwardhan UM, Floan GM, Calvo RY, Acker SN, Choi PM, Prieto JM, Bansal V, Sise MJ, Thangarajah H, Fairbanks TJ, Lazar DA. A Comparative Study of Laparoscopic versus Open Management of Index Small Bowel Obstruction in Children. *J Pediatr Surg.* 2024;59(3):416-20.
3. Tan HL, Mammen A, Hutson JM. Initial experience with laparoscopic adhesiolysis in children. *Pediatr Surg Int.* 1994;9:561-3.
4. Lee J, Tashjian DB, Moriarty KP. Surgical management of pediatric adhesive bowel obstruction. *J Laparoendosc Adv Surg Techn.* 2012;22(9):917-20.
5. Apelt N, Featherstone N, Giuliani S. Laparoscopic treatment for adhesive small bowel obstruction: is it the gold standard in children too?. *Surg Endosc.* 2013;27:3927-8.
6. Liu M, Cheng F, Liu X, Zheng B, Wang F, Qin C et al. Diagnosis and surgical management strategy for pediatric small bowel obstruction: Experience from a single medical center. *Front Surg.* 2023;10:1043470.