

Ileal Pouch-Anal Anastomosis for Diffuse Benign Cavernous Vascular Malformation, A Case Report

Evan D. Adams^{1*}, MD;  Michael Kozak², MD; Charles Browning^{1,3}, MD; Danielle A. Hutchings³, MD; Phillip R. Fleshner^{1,2}, MD

¹Cedars-Sinai Medical Center, Department of General Surgery, Los Angeles, USA

²Cedars-Sinai Medical Center, Department of Pathology and Laboratory Medicine, Los Angeles, USA

³Cedars-Sinai Medical Center, Division of Colorectal Surgery, Los Angeles, USA

*Corresponding authors:

Evan D. Adams, MD; Cedars-Sinai Medical Center, Department of General Surgery, 8700 Beverly Blvd, North Tower, Suite 8215, Los Angeles, CA 90048, USA. Tel: +1-916-548-5670; Fax: +1-205-272-6872; Email: Evan.Adams@cshs.org

Received: 2024-06-11

Revised: 2024-07-21

Accept: 2024-09-08

Abstract

This is a case report of a rarely described pan-colonic benign cavernous vascular malformation. A 34-year-old man presented with recurrent gastrointestinal bleeding starting early in life. He was found to have multiple vascular proliferations in his rectosigmoid, cecum, liver, and small bowel mesentery on axial imaging and endoscopic evaluation. He underwent total proctocolectomy with ileal pouch-anal anastomosis (IPAA). Pathological analysis of the vascular proliferations was consistent with diffuse benign cavernous malformations. The patient recovered well postoperatively and has not had recurrent bleeding. This is the first known case of total proctocolectomy with IPAA for diffuse benign cavernous vascular malformation. Colorectal surgeons should be aware of this safe and effective treatment option for patients with pan-colonic vascular lesions.

Keywords: Vascular malformation, Ileal pouch-anal anastomosis, diffuse benign cavernous vascular malformation

Please cite this paper as:

Adams ED, Kozak M, Browning C, Hutchings DA, Fleshner PR. Ileal Pouch-Anal Anastomosis for Diffuse Benign Cavernous Vascular Malformation, A Case Report. *Iran J Colorectal Res.* 2024;12(3):96-99. doi: 10.30476/acrr.2024.102952.1221.

Introduction

Vascular malformations, occasionally referred to as the misnomer hemangioma, arise due to a deficiency in endothelial smooth muscle. As opposed to a hemangioma, which grows due to rapid cell proliferation, vascular malformations expand as a result of progressive hydrostatic pressure.¹ Colonic vascular malformations are a rare clinical entity. They can either be localized, appearing as polypoid or nonpolypoid lesions, or diffuse. They are predominantly cavernous.²⁻⁵ They involve all

layers of the rectal wall, and can infiltrate adjacent organs via direct contact.⁶⁻⁸ There is a described female propensity, perhaps related to hormone exposure. They may precipitate Kasabach Merritt syndrome.⁹ Because of the fragility of these lesions, intra-luminal disruption causes massive, potentially life-threatening hemorrhage.

The distribution of colonic disease follows embryologic barriers, originating and occurring most frequently at the dentate line. The frequency decreases with the proximal distribution.^{10, 11} In one large series, cecal involvement was seen in only 1 out of 17

cases.¹¹ Surgical intervention has been the mainstay for perilous hemorrhage. Due to the continuous, transmural nature and rectosigmoid distribution, sphincter preserving resection, preferably via low anterior resection or proctectomy with coloanal anastomosis is the described surgical treatment.^{5, 7, 12} Nonsurgical options include endoscopic treatment for local disease,¹³⁻¹⁵ tranexamic acid infusion,¹⁶ and radiation.⁴ Ileal pouch-anal anastomosis (IPAA) has been described as a viable option when a proctectomy was required for recurrent bleeding following a total colectomy with an ileorectal anastomosis but has not been described as a primary surgical therapy.¹⁷

We present the first known case of total proctocolectomy with IPAA for diffuse benign cavernous vascular malformation. Colorectal surgeons should be aware of this safe and effective treatment option for patients with pan-colonic vascular lesions.

Case Presentation

The patient is a 34-year-old man who presented initially with a lifelong history of recurrent bright red rectal bleeding. He was well-appearing and not bleeding on presentation. Multiple endoscopic evaluations had been performed in the year prior. These demonstrated continuous, circumferential purple lesions extending from the rectum to the sigmoid colon (5-20cm). Additionally, there were prominent vascular masses in the descending colon, transverse colon, and hepatic flexure of similar

appearance. Endoluminal ultrasound demonstrated hypoechoic lesions with increased mucosal thickness. Sigmoid biopsy was consistent with benign vascular proliferation involving colonic mucosa. CT scan demonstrated similar multifocal lesions involving the transverse colon, rectum, sigmoid, mesentery, and small hemangiomas within the liver. Wireless capsule endoscopy (WCE) did not show any small bowel abnormalities.

Intervention

Due to the distribution of the disease, the patient underwent total proctocolectomy with laparoscopic IPAA. A lower midline incision was required for extraction due to the mass effect of the vascular lesions. Intraoperative findings are shown in Figure 1, and included significant, engorged masses in the colon, mesentery, and liver. The non-colonic lesions were most prominent in areas in direct contact with the colon (such as the edge of the liver). Intraoperative flexible pouchoscopy showed no evidence of disease within the anal canal or pouch.

Pathologic Analysis

Gross assessment of the specimen revealed multifocal tortuous, violaceous lesions, the largest of which measured up to 9 cm in greatest dimension. On histological evaluation, the lesions consisted of cavernous vascular spaces filled with blood and lined by cytologically benign appearing endothelium. The lesions showed transmural involvement of the colon and the pericolic adipose tissue (Figure 2).

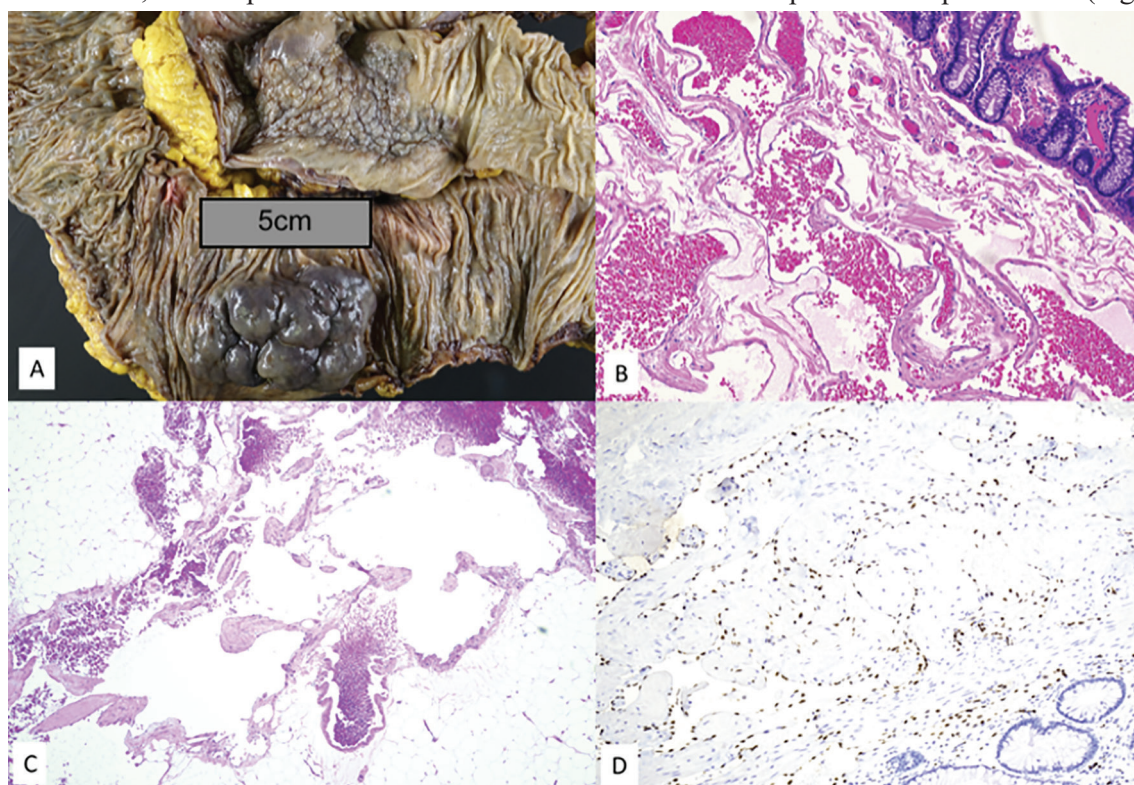


Figure 1: Intraoperative images demonstrating diffuse cavernous benign malformations impacting the small bowel, colon, liver, and rectum. Endoscopic images following ileal pouch-anal anastomosis are also shown. A: Liver, B: Small Bowel, C: Ligament of Treitz, Mesentery, D: Retroperitoneum, Mesentery, E: Appendix and Cecum, F: Transverse Colon, G: Splenic Flexure, H: Rectosigmoid and colonic mesentery, I: Ileal pouch-anal anastomosis endoscopic view. Grossly clear of vascular malformation

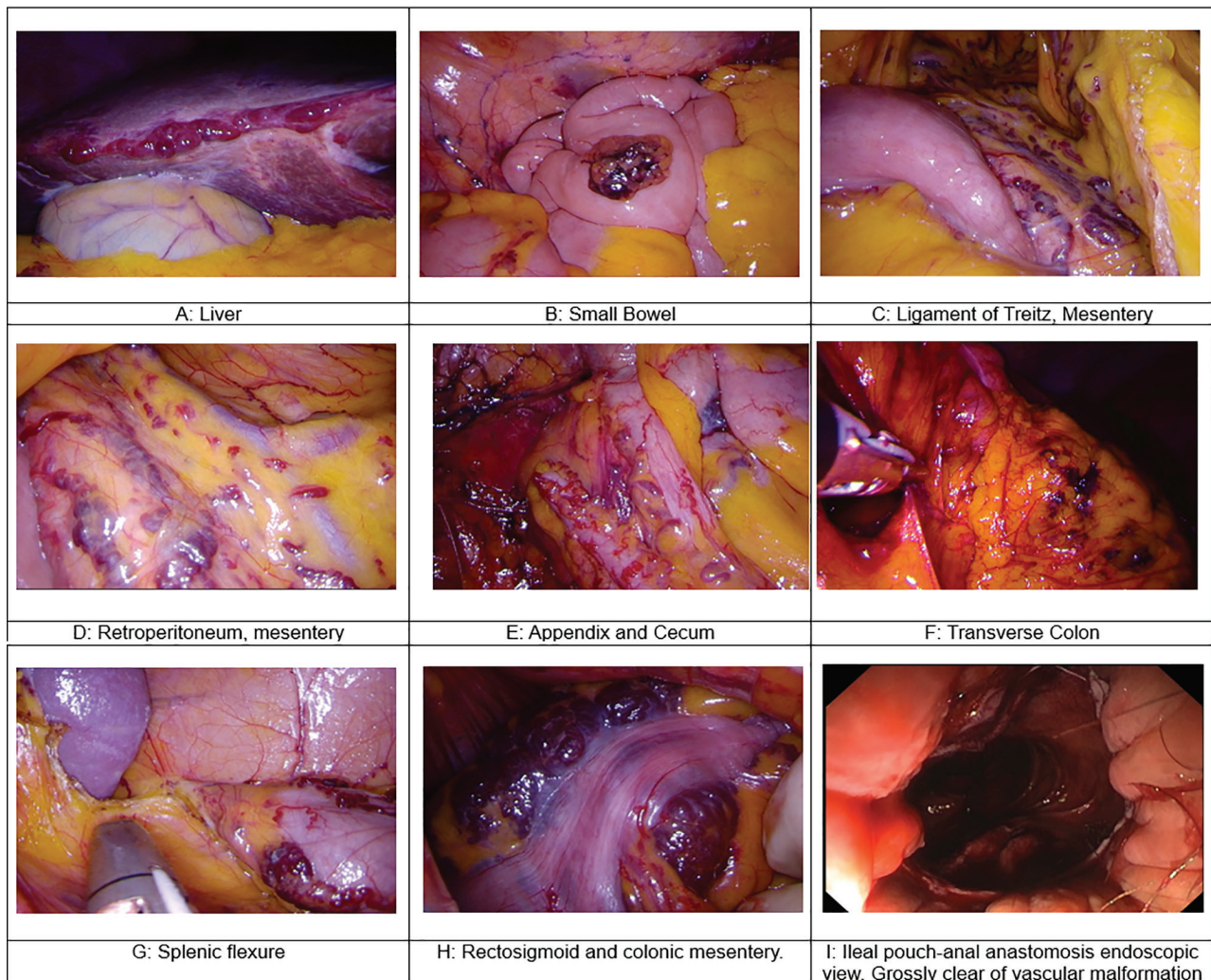


Figure 2: Gross examination of the colon [A] reveals a tortuous, violaceous, mucosal based mass (6.8×4.2 cm, raised to a height of 1.5 cm) in the right colon and a patch of mucosa in the left colon with cobblestone appearance (9.1×4.9 cm). On histologic examination, the lesions consist of histologically benign cavernous vascular proliferations extending from the submucosa [B] to the pericolic adipose tissue (Magnification 4×) [C]. Erythroblast transformation-specific [ETS]-related gene immunohistochemical staining (Magnification 4×) [D] highlights the nuclei of endothelial cells lining the vascular spaces (Magnification 10×).

ERG (Erythroblast transformation-specific [ETS]-related gene) immunohistochemical staining highlighted the nuclei of the lesional cells confirming vascular origin (Figure 2); while D2-40, a marker of lymphatics, was negative. GLUT-1 (glucose transporter protein type-1) immunostain, which commonly labels infantile hemangiomas, was negative. Next-generation sequencing (NGS) using the Ion Oncomine Comprehensive Panel Plus (OCAPlus) did not show any clinically significant variants or alterations associated with specific vascular lesions or known clinical syndromes (including Klippel-Trenaunay and Osler-Rendu-Weber). Taken together, the findings were consistent with diffuse benign cavernous vascular malformation.

Recovery

The patient was discharged on postoperative day four after an uneventful recovery. On day 16 after surgery, he presented with abdominal pain and underwent drainage of a noninfected presacral fluid collection. Three months later he underwent routine

ileostomy reversal after pouchogram. He is doing well in surveillance.

Discussion

Familiarity with these entities is pertinent to the colorectal surgeon, as surgery is the mainstay of treatment. Mortality associated with massive gastrointestinal bleeding is as high as 50%.³ Due to its clinical rarity, an estimated 80% of patients suffer morbidity from treatment delays and unnecessary surgeries.¹⁸⁻²⁰ Misdiagnosis as inflammatory bowel disease, portal hypertension, and refractory hemorrhoids have been reported.^{18, 21}

Several unique features regarding our case make it noteworthy. First, the distribution of disease including the cecum is rare in diffuse benign cavernous vascular malformations. It is not clear what factors may influence the distribution of disease. Many of these secondary locations, such as the mesentery and liver edge, may have spread via direct contact with colonic lesions. The decision to proceed with IPAA

was based on this pan-colonic distribution. Second, to the best of our knowledge, this is the first use of a single-stage total proctocolectomy with IPAA for diffuse benign cavernous vascular malformation.

Conclusion

This is the first report of primary IPAA for diffuse colonic cavernous vascular malformation. This surgical approach should be considered in patients with these vascular lesions with any proximal colonic involvement, given the near-universal involvement of the distal rectum up to the dentate line.

Consent

There is no identifiable patient information contained in this report. The patient consented to participate

References

- Mulliken JB, Glowacki J. Hemangiomas and vascular malformations in infants and children: a classification based on endothelial characteristics. *Plast Reconstr Surg.* 1982;69(3):412-422. doi:10.1097/00006534-198203000-00002
- Yoo S. Hemangiomas and vascular malformations. *Fundam Pediatr Surg.* 2011;1(212):819-828. doi:10.1007/978-1-4419-6643-8_105
- Borum ML. Cavernous colorectal hemangioma: A rare cause of lower gastrointestinal bleeding and a review of the literature. *Dig Dis Sci.* 1997;42(12):2468-2470. doi:10.1023/A:1018896024906
- Chaimoff C. On the treatment of hemangioma of the rectum. *Dis Colon Rectum.* 1990;33(2):167. doi:10.1007/BF02055555
- Demircan O, Sönmez H, Zeren S, Coşar E, Bicakci K, Ozkan S. Diffuse cavernous hemangioma of the rectum and sigmoid colon. *Dig Surg.* 1998;15(6):713-715. doi:10.1159/000018665
- Tan TC, Wang JY, Cheung YC, Wan WY. Diffuse cavernous hemangioma of the rectum complicated by invasion of pelvic structures. Report of two cases. *Dis Colon Rectum.* 1998;41(8):1062-1066. doi:10.1007/BF02237403
- Sylla P, Deutsch G, Luo J, et al. Cavernous, arteriovenous, and mixed hemangioma - Lymphangioma of the rectosigmoid: Rare causes of rectal bleeding - Case series and review of the literature. *Int J Colorectal Dis.* 2008;23(7):653-658. doi:10.1007/s00384-008-0466-4
- Topalak O, Gönen C, Obuz F, Seçil M. Diffuse cavernous hemangioma of the rectosigmoid colon with extraintestinal involvement. *Turk J Gastroenterol.* 2006;17(4):308-312. <http://www.ncbi.nlm.nih.gov/pubmed/17205413>.
- Mehrjardi AZ, Fakhari S, Rajabi MA. Cavernous hemangioma of colon and pregnancy: A case report. *Acta Med Iran.* 2018;56(4):272-277.
- Allred HW. Hemangiomas of the colon, rectum, and anus. *Mayo Clin Proc.* 1974;49(10):739-741. <http://www.ncbi.nlm.nih.gov/pubmed/4422392>.
- Wang HT, Gao XH, Fu CG, Wang L, Meng RG, Liu LJ. Diagnosis and treatment of diffuse cavernous hemangioma of the rectum: Report of 17 cases. *World J Surg.* 2010;34(10):2477-2486. doi:10.1007/s00268-010-0691-1
- Malage S et al. Rectal Arteriovenous Malformation: A Report of Two Cases, Review of Literature, and Management Algorithm. *Iran J Color Res.* 2022;10(3):103-109.
- Willert RP, Chong AK. Multiple cavernous hemangiomas with iron deficiency anemia successfully treated with double-balloon enteroscopy. *Gastrointest Endosc.* 2008;67(4):765-767. doi:10.1016/j.gie.2007.07.044
- Fishman SJ, Smithers CJ, Folkman J, et al. Blue rubber bleb nevus syndrome: Surgical eradication of gastrointestinal bleeding. *Ann Surg.* 2005;241(3):523-528. doi:10.1097/01.sla.0000154689.85629.93
- Zeng Z, Wu X, Chen J, Luo S, Hou Y, Kang L. Safety and feasibility of transanal endoscopic surgery for diffuse cavernous hemangioma of the rectum. *Gastroenterol Res Pract.* 2019;2019. doi:10.1155/2019/1732340
- Cotzias E, Rehman SF, Zadeh RA, Smith D. Conservative management of diffuse cavernous haemangioma of the sigmoid and rectum. *Ann R Coll Surg Engl.* 2020;102(1):E1-E3. doi:10.1308/rcsann.2019.0088
- Singland JD, Penna C, Parc R. [Colorectal cavernous hemangiomatosis treated by total colectomy and ileo-anal anastomosis]. *Ann Chir.* 1997;51(4):382-384. <http://www.ncbi.nlm.nih.gov/pubmed/9297865>.
- Amarapurkar DN, Jadliwala M, Punamiya S, Jhawer P, Chitale A, Amarapurkar A. Cavernous hemangiomas of the rectum: Report of three cases. *Am J Gastroenterol.* 1998;93(8):1357-1359. doi:10.1111/j.1572-0241.1998.447_q.x
- Levy AD, Abbott RM, Rohrmann J, Frazier AA, Kende A. Gastrointestinal hemangiomas: Imaging findings with pathologic correlation in pediatric and adult patients. *Am J Roentgenol.* 2001;177(5):1073-1081. doi:10.2214/ajr.177.5.1771073
- Oner Z, Altaca G. Diffuse cavernous rectal hemangioma--clinical appearance, diagnostic modalities and sphincter saving approach to therapy: report of 2 and a collective review of 79 cases. *Acta Chir Belg.* 1993;93(4):173-176. <http://www.ncbi.nlm.nih.gov/pubmed/8237232>.
- Wang CH. Sphincter-saving procedure for treatment of diffuse cavernous hemangioma of the rectum and sigmoid colon. *Dis Colon Rectum.* 1985;28(8):604-607. doi:10.1007/BF02554157

in research when they preoperatively enrolled in a prospective Inflammatory Bowel Disease database approved by our institutional IRB.

Contribution

Dr. Phillip Robert Fleshner is the senior author of this work. Drs. Danielle A. Hutchings and Michael Kozak contributed significant writing, technical analysis, and intellectual content to the manuscript. Dr. Charles Browning and Evan Adams provided manuscript drafting and editing and contributed to the intellectual content.

Funding: No funding was obtained for this study.

Conflict of interest: None declared.