

A Review of the Role of Natural Orifice Specimen Extraction Surgery in Laparoscopic Colorectal Surgery

Fábio Guilherme Campos^{1*}, MD;  Leonardo Alfonso Bustamante-Lopez², MD, PhD; Univaldo Etsuo Sagae³, MD; Carlos Augusto Real Martinez⁴, MD

¹Colorectal Surgeon at Hospital das Clínicas; Associate Professor of Surgery at University of São Paulo Medical School (USP), Brazil

²Post-Doctoral Research Fellow of Colorectal Surgery at Adventure Health Central Florida, Sanford, Florida, USA

³Colorectal Surgeon in Gastroclínica Cascavel (Cascavel, Paraná), Brazil

⁴Colorectal Surgeon, at University of Campinas (UNICAMP) and São Francisco University (USF) at Bragança Paulista. São Paulo, Brazil

*Corresponding author:

Fábio Guilherme Campos, MD; Rua Padre João Manoel, 222. Cj 120 – São Paulo (SP) 01411-001, Brazil. **Tel:** +55 11 30647010; **Fax:** +55 11 30610108
Email: fgmcampos@terra.com.br

Received: 2024-02-07

Revised: 2024-03-27

Accepted: 2024-03-31

Abstract

The inclusion of minimally invasive techniques in colorectal surgery brought many advantages to patient's recovery. However, conventional techniques for laparoscopic-assisted colectomy (LAC) still require a small abdominal incision for specimen extraction. The present manuscript aimed to review the technical details, results, and advantages of colorectal resections using different approaches to extract the resected specimen, including the abdominal wall, the vagina, or the rectum. To analyze this data, we searched the literature for recent and important results concerning the use of different approaches to extract the specimen in minimally invasive colorectal procedures. Besides the proven feasibility and safety associated with Natural Orifice Specimen Extraction Surgery (NOSES) in colorectal surgery, some unresolved issues remain to be unified and standardized. These issues are mainly represented by surgical techniques and indications. Morbidity is not a common problem, although potentially there may be complications affecting the quality of life. So far, the most important indication remains the management of intestinal endometriosis, as it is not a malignant disease and the specimen is not too large. Nevertheless, surgical experience and appropriate counseling are fundamental requirements when dealing with cancer patients. Eventual complications should be discussed with patients.

Keywords: Laparoscopy; Colorectal neoplasms; Minimally invasive surgical procedures; natural orifice endoscopic surgery; incisional hernia

Please cite this paper as:

Campos FG, Bustamante-Lopez LA, Sagae UE, Real Martinez CA. A Review of the Role of Natural Orifice Specimen Extraction Surgery in Laparoscopic Colorectal Surgery. *Iran J Colorectal Res.* 2024;12(1):16-22. doi: 10.30476/acrr.2024.101615.1204.

Introduction

The recent revolution of surgical techniques has witnessed an enormous effort towards “minimally invasive” procedures. Laparoscopic surgery to treat colorectal diseases has emerged to be a less aggressive surgical procedure, by reducing

general complications and improving cosmetics and postoperative comfort, among many other advantages (1). Besides that, an auxiliary abdominal incision may be sometimes necessary to accomplish three main objectives: to retrieve the surgical specimen, to complete the operative planning (such as anastomosis) and to seek operative safety. Although

this incision may negate some advocated advantages of a minimally invasive procedure, it allows retrieval of the surgical specimen with minimum trauma in the scenario of a well-planned incision or even natural-orifice transluminal endoscopic surgery (2).

The choice of the best approach depends on many factors. For example, vertical abdominal incisions are faster but are associated with greater rates of incisional hernias. Moreover, incisions situated above the umbilical line may cause more pain than those situated below (3). In recent years, Natural Orifice Specimen Extraction Surgery (NOSES) has been recommended with the premise to extend the benefits of MIS, by improving postoperative outcomes and alleviating recovery even more (4).

These objectives should be obtained with the removal of surgical specimens through a natural orifice and the avoidance of an abdominal incision. However, to analyze the advantages of avoiding a mini-laparotomy, the surgeon must argue if the expected short-term benefits do occur (pain reduction, cosmesis, fewer complications, etc) by confronting them with reported outcomes such as adverse complications.

The present paper will review and discuss the development, safety, and effectiveness of colorectal resections using different approaches to perform specimen extraction.

Abdominal Incisions used During Right Colectomy

During the early phases of laparoscopic surgery, most surgeons used to perform a small midline incision to extract the specimen and perform an extracorporeal anastomosis after right colon resection. After colon devascularization and mobilization, a supra, trans-umbilical incision is performed in an extension required to allow specimen retrieval followed by intestinal anastomosis (5).

Along this experience, however, it was easily perceived that mesenteric traction could occur during exteriorization of the colon, leading to postoperative ileus. Additionally, incisional infection and hernias were not rare complications. A review of 370 patients undergoing routine postoperative radiological exams for oncological purposes showed 54 (39.1%) postoperative ventral hernia (POVH), 42/72 (58.3%) at midline extraction site, and 12/66 (18.8%) at off-midline extraction sites ($P < 0.0001$). Surgical site infections and patients positive for tumor metastasis were associated with higher POVH rates. Most (74%) POVHs were identified within 18 months after surgery ($P < 0.0001$) (6).

Abdominal Incisions Used During Left Colectomy or Anterior Resection

Left colon or rectosigmoid resections are the most common operations, as these segments must be resected to treat neoplasia or diverticular disease. Table 1 demonstrates the possible auxiliary incisions and approaches used during these procedures. Analysis of these options must consider some aspects such as specimen diameter and volume, as inflammatory or neoplastic masses should not be macerated or inadequately manipulated during extraction (7).

After a left colorectal resection, most surgeons prefer a transverse suprapubic incision because it may be associated with less pain and infection. When performing a Pfannenstiel incision, it is not always necessary to cut the medial border of the rectus muscle. Moreover, its extension may be amplified if necessary (8).

Suprapubic transverse incisions (or in the left lateral quadrant) are usually performed during combined operations with manual assistance from the beginning of the procedure (*hand-assisted surgery*). In this circumstance, it is necessary to use a larger incision (about 8 cm) to allow hand introduction or fixation of a plastic device to protect the abdominal wall. However, left quadrant incisions may complicate the position of an abdominal stoma during the patient's evolution. Moreover, one must pay attention to identifying the epigastric vessels (9).

In cases dealing with not-too-large specimens, its extraction after enlargement of the incision on the right iliac fossa (12 mm trocar) may be an interesting alternative, particularly to resect segments of benign chronic diverticular disease (10).

An infra-umbilical vertical incision may provide fast access to the abdominal cavity and it is the preferential approach to convert an operation due to intraoperative bleeding or other complications not manageable via laparoscopy.

The choice of specimen extraction incision may affect incisional hernia (IH) incidence. In a study including 4276 Korean patients from a single center (11), 73 (2.7%) patients were clinically and radiologically diagnosed with IH after a median follow-up of 41 months. This complication was even greater among patients with midline versus transverse incisions (3.5% vs. 1.7%, $P = 0.003$). The authors identified old age, female gender, obesity, co-morbid cardiovascular disease, and perioperative bleeding requiring transfusion as risk factors. These observations were confirmed by a systematic review

Table 1: Auxiliary incisions used in laparoscopic left colon resections

Location of Incision	Type of incision
Left inferior quadrant	Transverse or para-median
Supra-pubic	Pfannenstiel or Chernley
Median line	Vertical incision (infra-umbilical)
Vagina	Apex of vagina
Rectum	Endorectal

and meta-analysis of 17 comparative studies, where IH was significantly higher in the midline compared to off-midline groups (transverse or Pfannenstiel) (12). Moreover, these last data may be considered heterogeneous and of poor quality.

NOSES: Definition and Classification

Colorectal surgery has undergone many improvements during recent decades, most of them developed to improve outcomes after open or minimally invasive surgeries (MIS). In this process of evolution, the introduction of laparoscopic and robotic surgery was fundamental as they have overcome several limitations associated with conventional approaches.

Since it was recognized that surgical trauma affects patient's complications, recovery, and prognosis, the old concept associating great incisions and great surgeons has finally been restricted to the history of Medicine. Additionally, great incisions may also have important cosmetic and psychological impacts on the patient's life.

Thus, the exploration of MIS is an attempt to minimize surgical trauma and achieve similar therapeutic goals. Single-incision laparoscopic surgery (SILS) and the NOSES were developed in the context of the increasing trend to perform less invasive procedures as a natural evolution of MIS (13). Both approaches aimed to improve wound-related complications (infection and hernias), postoperative comfort, and cosmesis.

The opportunity to perform intracorporeal anastomosis and extract the specimen via a different approach avoided an abdominal incision. In colorectal surgery, NOSES may be applied to resect all segments. It is defined as an intra-abdominal specimen resection, extraction via a small abdominal incision or a hollow organ (rectum, vagina, or mouth), and intracorporeal intestinal tract reconstruction (14, 15).

The first NOSES attempts in colorectal surgery used the vagina and the anus to extract colorectal segments (16, 17). An international NOSES consensus has established a classification according to the procedure for specimen extraction (transanal and transvaginal) or location of the tumor (18). These options to extract benign and malignant diseases were feasible and considered interesting alternatives to induce less trauma and improve outcomes when compared with conventional specimen extraction. They may also improve prognosis and quality of life without affecting sexual function (19).

Vaginal Approach

The transvaginal route is classical in gynecology since the vagina is easy to access and has good elasticity, vascular supply, and healing properties. For this reason, it is considered an ideal option for the removal of bulky lesions. In the beginning, the transvaginal approach was used only when the

vaginal overture was necessary for other reasons, but progressively it was chosen only as an alternative to deliver the specimen after anastomosis (20).

Consequently, transvaginal extraction is especially advocated in right colectomy. It has been widely recommended to perform the vaginal incision at the posterior vaginal fornix because of its easy access and the absence of nerve and vascular distribution in this location. Thus, sexual or bleeding complications after posterior colpotomy have not been reported yet (21). Usually, the vaginal approach is fashioned at the end of the procedure with the insertion of a wound protector to stretch the vaginal wall. Aiming to prevent gas escape, a swab may be placed in the introitus. Thus, the specimen is carefully extracted with push and pull movements. Besides this, the real impact of transvaginal access has not been fully investigated in terms of sexual function, dyspareunia, and pregnancy.

The use of wound protectors and a sterile bag aims to prevent infection and spillage of cancer cells as these devices allow an aseptic and tumor-free extraction. Another important technical care is to avoid leaving the anastomosis close to the vagina suture, as an eventual dehiscence may turn into a recto-vaginal fistula. With all these measures, the transvaginal approach has demonstrated oncological safety, improved cosmetic outcomes, and limited the effects on female's sexual function (19). Moreover, it allows the construction of either hand-sewn or mechanical intestinal anastomosis after resection. This alternative has been demonstrated to be a safe and feasible option in experienced hands (Figure 1) (22).

As this option is confined to women, the surgeon must discuss the possibility of sexual dysfunction with the patient. Technical details are presented in Figure 2.

Transanal Approach

The choice of a transanal extraction is mainly limited by the specimen size, especially the so-called maximum circumferential diameter (CDmax). Consequently, it has been applicable to extract lesions smaller than 3 centimeters (23). The methods are classified according to the procedures of specimen extraction as follows:

- Eversion-resection: transanal specimen eversion and extracorporeal resection technique (for low rectal tumors)
- extraction-resection: transluminal specimen extraction and extracorporeal resection technique (for middle rectal tumors)
- resection-extraction: the intra-abdominal specimen resection and transluminal extraction technique (for upper rectum resection and colectomy)

Similarly, rectal extraction requires a plastic extraction bag from below to involve the specimen to be pulled out through the anal canal. Thus, previous preoperative rectal cleaning and care are necessary to

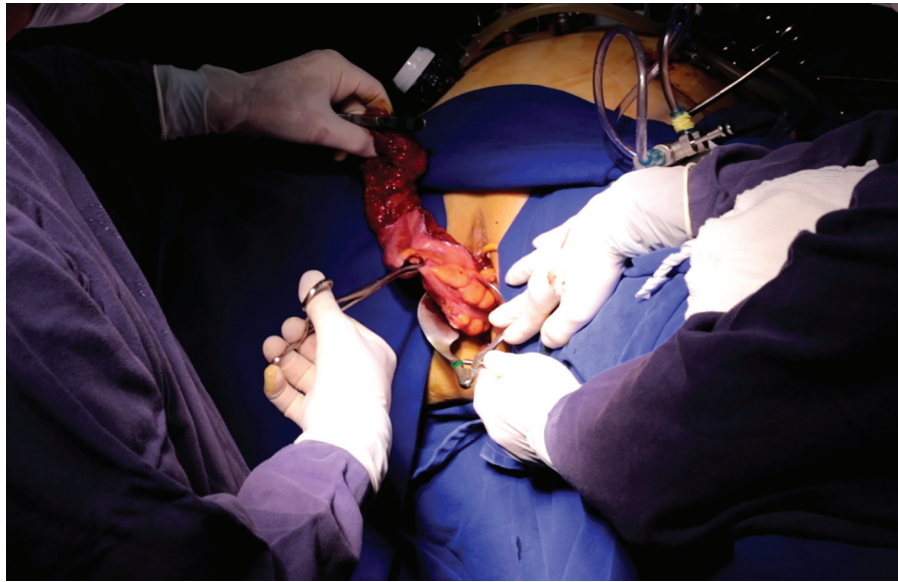


Figure 1: The surgeon resects a segment of the sigmoid and rectum through the vaginal wall (photo belongs to U.E. Sagae).

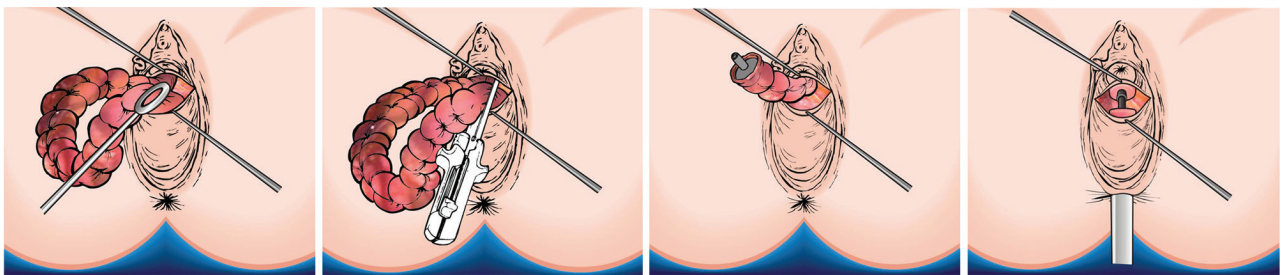


Figure 2: Schematic steps to perform rectal resection and anastomosis via the vaginal approach (Figures belong to U.E. Sagae).

avoid sphincter stretch during manipulation during the transanal approach. This choice may involve technical challenges such as the anvil insertion through the anus and performing a purse-string suture in the descending colon and the rectum to construct the anastomosis (24).

Alternative Approach

Another choice for surgical specimen extraction is the utilization of the prophylactic ileostomy site. In a retrospective study (25), the researchers evaluated the safety and feasibility of this approach in 331 consecutive patients with rectal cancer after laparoscopic low anterior resections, by comparing 155 matched patients with 176 undergoing the classical extraction via a lower abdominal incision. These authors observed shorter mean operative time, as well as less blood loss, pain, and wound infections (0 vs 4%) in the experimental group. Consequently, the researchers concluded that surgical specimen extraction via a prophylactic ileostomy procedure represents a secure and feasible approach to laparoscopic rectal cancer surgery and embodies the principle of minimally invasive surgery.

Another choice after total proctocolectomy is to retrieve the specimen through an incision enlargement of the 12 mm trocar situated in the right iliac fossa, and the temporary ileostomy is matured in the same incision. During this procedure, care

should be taken to avoid intestinal torsion around its axis (26).

In patients undergoing restorative proctocolectomy or ileorectal anastomosis, we prefer to extract the whole colon via a Pfannenstiel incision, since an alternative incision in the left quadrant doesn't offer an appropriate visualization of the ileal pedicle. Through this incision, it is possible to evaluate the mesenteric tension and also perform some correction maneuvers if necessary (27).

NOSES Results, Limitations, and Acceptance

Analysis of the effectiveness of NOSES raises many questions, such as whether it makes sense, if real benefits may be achieved with no adverse complications, if patient selection is necessary and what are the procedures in which a NOSE approach may be utilized.

Due to the technical complexity involved in specimen extraction (that may require a posterior colpotomy) or digestive reconstruction involving an intracorporeal anastomosis), NOSES adoption requires prerequisite laparoscopic skills and experience to shorten the learning curve. For these reasons, NOSES may be associated with greater costs and longer operative time.

Common selection criteria for the NOSE approach were based on disease features, site and size of tumors, and distance of colorectal lesions from the

anal verge (28, 29). For obvious reasons, patients with emergent complications (obstruction or perforation) are not good candidates.

Since it challenges minimally invasive surgery limits, NOSES outcomes may be influenced by patient selection criteria. As it avoids infection and incisional hernias, obese patients turn out to be natural candidates. In a retrospective large series of NOSE colectomy in Australia (30), an analysis of 159 patients with benign diseases demonstrated that it does not add surgical morbidity in patients $>30 \text{ kg/m}^2$.

One major concern is oncological safety and implications during tumor manipulation. For that, NOSES should preferably be indicated to resect benign, early (Tis or T1), or at least less advanced lesions (T2 and T3). Besides that, Park and colleagues (31) found no differences in the 5-years disease-free survival rate for all stages in a large prospectively collected study of 844 patients with rectal cancer (163 NOSES and 681 conventional laparoscopic patients).

Another important clinical feature is the tumor dimension. While patients with $\text{CDmax} < 3 \text{ cm}$ are ideal candidates for transanal extraction, 3-5 cm lesions may preferably be resected through the vagina. Similarly, the best approach may be chosen depending on body mass index (less than 30 kg/m^2 for transanal and less than 35 kg/m^2 for transvaginal approach).

Finally, the transanal route should be avoided in patients exhibiting any degree of sphincter dysfunction or rectal stenosis. Similarly, women who intend to have future pregnancies should not undergo a transvaginal approach.

Most evidence is retrospective, making it hard to recommend NOSES in a routine setting. Another criticism is that patient selection criteria have included favorable patients regarding BMI and specimen dimensions in comparative studies (32).

In a prospective evaluation of 277 transanal and 26 vaginal consecutive patients during 20 years, Franklin and colleagues (33) concluded that both extractions are safe and effective approaches in terms of complications. However they raise the question that a transvaginal extraction is more difficult as it needs specific extraction devices to prevent adjacent organ injuries.

Level-I evidence from randomized controlled trials (RCTs) (34, 35) and meta-analysis (36) have demonstrated NOSES effectiveness in colorectal procedures by appointing its short-term benefits. In a single-blinded randomized clinical trial with 40 patients (NOSES vs. conventional laparoscopic colectomy), Wolthuis and co-workers (34) observed less requirement for controlled epidural analgesia

opioid and non-opioid medications. The comparison also showed similar postoperative anorectal function, complications, and hospital stay, but pain scores were significantly lower in the NOSES group. Leung and colleagues (35) described the results of 70 recruited patients undergoing anus delivery using a transanal endoscopic device. They observed less pain scores during the first week and no wound infection in the study group.

Compared with conventional laparoscopic colorectal resections, numerous potential benefits have been reported such as improvement in postoperative pain, faster recovery, accelerated bowel function recovery (decline in direct bowel manipulation and mesenteric traction) with a consequent shorter hospital stay, reduced incision-related complications and cosmetic outcomes leading to less psychological stress (21).

According to these observations, NOSES justifies the avoidance of an incision. But even more than 30 years after the first report (16), general acceptance is still irregular (37). The lack of consensus for the application of this technique is based on technical issues, economic reasons, and lack of standardization that prevent it from gaining enough popularity. Future efforts should concentrate on the development of specific tools, creation of training systems, and evaluation of large-scale randomized controlled trials aiming to standardize the technique.

Conclusion

Colorectal surgeons must recognize and be aware of the advantages and limitations of Natural Orifice Specimen Extraction Surgery (NOSES) in minimally invasive procedures. Certainly, in clinical practice, an ideal candidate for this choice may appear and claim to be included in this group associated with the benefits of better cosmesis, less incisional hernia and infection, accelerated recovery, and reduced hospital stay. Although this opportunity will depend on tumor volume, body mass index, and patient sex, the surgeon has to be technically prepared to evaluate risks and to perform NOSES with excellence.

Authors' Contribution

Campos FG: conception of the work, literature research of the subject, interpretation of data, revision, final manuscript text. Bustamante-Lopez LA: literature research of the subject, interpretation of data, data acquisition. Sagae UE: surgical photo, revision, final manuscript text. Martinez CAR: interpretation of data, revision, final manuscript text.

Conflict of interest: None declared.

References

- Kaiser AM. Evolution and future of laparoscopic colorectal surgery. *World J Gastroenterol*. 2014 Nov 7;20(41):15119-24. doi: 10.3748/wjg.v20.i41.15119.
- Izquierdo KM, Unal E, Marks JH. Natural orifice specimen extraction in colorectal surgery: patient selection and perspectives. *Clin Exp Gastroenterol* 2018; 11:265-279. doi: 10.2147/CEG.S135331.eCollection 2018.
- Brown SR, Goodfellow PB. Transverse versus midline incisions for abdominal surgery. *Cochrane Database Syst Rev*. 2005 Oct 19;2005(4):CD005199. doi: 10.1002/14651858.CD005199.pub2. PMID: 16235395. PMCID: PMC8866010
- Gundogan E, Kayaalp C, Alinak Gundogan G, Sumer F. Total 102 natural orifice specimen extraction following laparoscopic colorectal resections. *The Updates Surg*. 2023 Jan;75(1):197-203. doi: 10.1007/s13304-022-01412-4. Epub 2022 Nov 1. PMID: 36319790 Clinical Trial.
- Grüter AAJ, Toorenvliet BR, Belgers EHH, Betl EJT et al. Right collaborators group. Nationwide standardization of minimally invasive right hemicolectomy for colon cancer and development and validation of a video-based competency assessment tool (the Right study). *Br J Surg* 2024 Jan 3;111(1):znad404. doi: 10.1093/bjs/znad404.
- Greeland I, Raveh G, Gavrielli S, Sadot E, Kashtan H, Wasserberg N. High Rates of Incisional Hernia After Laparoscopic Right Colectomy With Midline Extraction Site. *Surg Laparosc Endosc Percutan Tech* 2021 Jul 28;31(6):722-728. doi: 10.1097/SLE.0000000000000977.
- Al Dhaheri M, Ibrahim M, Al-Yahri O, Amer I et al. Choice of specimen's extraction site affects wound morbidity in laparoscopic colorectal cancer surgery. *Langenbecks Arch Surg*. 2022 Dec;407(8):3561-3565. doi: 10.1007/s00423-022-02701-7. Epub 2022 Oct 11.
- Benlice C, Stocchi L, Sapci I, Gorgun E, Kessler H, Liska D, Steele SR, Delaney CR. Impact of the extraction-site location on wound infections after laparoscopic colorectal resection. *Am J Surg*. 2019 Mar;217(3):502-506. Doi: 10.1016/j.amjsurg.2018.10.034.
- Campos FG. Complications and conversions in laparoscopic colorectal surgery. Results of a multicenter Brazilian Trial. *Surg Laparosc Endosc Percutan Tech* 2003; 13 (3) 173-179.
- Campos FG. Cirurgia laparoscópica assistida com a mão. Indicações e Resultados preliminares em procedimentos colo-retais. *Rev Bras Coloproct. (JCOL)* 2005;25(1):94-101.
- Choi HB, Chung D, Kim JS, Lee TH, Baek SJ, Kwak JM, Kim J, Kim SH. Midline incision vs. transverse incision for specimen extraction is not a significant risk factor for developing incisional hernia after minimally invasive colorectal surgery: multivariable analysis of a large cohort from a single tertiary center in Korea. *Surg Endosc* 2022;36(2):1199-1205. doi: 10.1007/s00464-021-08388-z.
- Lee L, Abou-Khalil M, Liberman S, Boutros M, Fried GM, Feldman LS. Incidence of incisional hernia in the specimen extraction site for laparoscopic colorectal surgery: systematic review and meta-analysis. *Endosc* 2017 Dec;31(12):5083-5093. DOI: 10.1007/s00464-017-5573-2
- Remzi FH, Kirat HT, Kaouk JH, Geisler DP. Single-port laparoscopy in colorectal surgery. *Colorectal Dis* 2008;10(08):823-826
- Clark M, Nann S, Kong J, Barker T. Effectiveness of NOTES versus traditional techniques on surgical outcomes in adults with diverticulitis: a systematic review protocol. *JBIEvid Synth*. 2023 Nov 9. doi: 10.11124/JBIES-23-00324.
- Seow-En I, Khor SN, Koo CH, Wee IJY, Tan EK. Transvaginal Natural Orifice Specimen Extraction (NOSE) in Laparoscopic Colorectal Cancer Surgery With New Insights on Technique and Patient Selection. *Surg Laparosc Endosc Percutan Tech*. 2023 Oct 1;33(5):571-575. doi: 10.1097/SLE.0000000000001208. PMID: 37523505
- Stewart EA, Liau AS, Friedman AJ. Operative laparoscopy followed by colpotomy for resecting a colonic leiomyosarcoma: a case report. *J Reprod Med* 1991;36:883-4.
- Franklin ME, Ramos R, Rosenthal D et al. Laparoscopic colonic procedures. *World J Surg* 1993;17:51-6.
- Guan X, Sheng L, Longo A, Cai JC, Chen W, Chen LC, Chun HK, Pereira JMC et al. International consensus on natural orifice specimen extraction surgery (NOSES) for colorectal cancer. *Gastroenterology Report* 2019; 7 (1): 24-31. <https://doi.org/10.1093/gastro/goy055>
- Zheng W, Zhang M, Hu X, Tan W, Liu S, Ren J. Influence of transvaginal laparoscopic surgery on sexual function, life quality and short-term efficacy of patients diagnosed with colorectal cancer. *Am J Transl Res* 2022 Jul 15;14(7):5098-5106.
- Diana M, Perretta S, Wall J, Costantino FA, Leroy J, Demartines N, Marescaux J. Transvaginal specimen extraction in colorectal surgery: current state of the art. *Colorectal Dis* 2011 Jun;13(6):e104-11. doi: 10.1111/j.1463-1318.2011.02599.x. PMID: 21564461.
- Zhang M, Liu Z, Wang X. Is natural orifice specimen extraction surgery the future direction of minimally invasive colorectal surgery? Review article. *Surgery Open Science* 2022; 10: 106-110.
- Abrao MS, Sagae UE, Gonzales M, Podgaec S, Dias Jr JA. Treatment of rectosigmoid endometriosis by laparoscopically assisted vaginal rectosigmoidectomy. *Int J Gynecol Obst* 2005; 91: 27-31.
- Si Yu , Yong Ji , Tedong Luo , Pengjie Xu, Zuojun Zhen, Jianzhong Deng. A modified technique of transanal specimen extraction in the laparoscopic anterior rectal resection for upper rectal or lower sigmoid colon cancer: a retrospective study. *BMC Surg*. 2021 Feb 12;21(1):82. doi: 10.1186/s12893-021-01085-7.
- Cheng CC, Hsu Y-R, Chern YJ, Tsai WS, Hung HY, Liao CK, Chiang JM, Hsieh PS, You JF. Minimally invasive right colectomy with transrectal natural orifice extraction: could this be the next step forward? *Tech Coloproctol* 2020 Nov;24(11):1197-1205. doi: 10.1007/s10151-020-02282-x. Epub 2020 Jul 6.
- Wang P, Liang JW, Zhou HT, Wang Z, Zhou ZX. Surgical specimen extraction via a prophylactic ileostomy procedure: A minimally invasive technique for laparoscopic rectal cancer surgery. *World J Gastroenterol* 2018 Jan 7;24(1):104-111. doi: 10.3748/wjg.v24.i1.104.
- Lee KY, Park JW, Lee KY, Cho S, Kwon YH, Kim MJ, Ryoo SB, Jeong SY, Park KJ. Safety of temporary ileostomy via specimen extraction site in rectal cancer patients who underwent laparoscopic low anterior resection. *Sci Rep*. 2019 Feb 19;9(1):2316. doi: 10.1038/s41598-019-38790-6. PMID: 30783181
- Campos FG, Real Martinez CA, Monteiro de Camargo MG, Cesconetto DM, Nahas SC, Ceconello I. Laparoscopic Versus Open Restorative Proctocolectomy for Familial Adenomatous Polyposis. *J Laparoendosc Adv Surg Tech A*.

- 2018 Jan;28(1):47-52. doi: 10.1089/lap.2017.0397.
28. Zhao Z, Chen Q, Zheng H, Jianjun Li, Zheng S, Zhao E. Retrospective Study of Natural Orifice Specimen Extraction Surgery in Resection of Sigmoid and Rectal Tumors. *Laparoendosc Adv Surg Tech A* 2021; 31(11):1227-1231. doi: 10.1089/lap.2020.0780. Epub 2020 Nov 9. PMID: 33164666 DOI: 10.1089/lap.2020.0780.
 29. Guan X, Lu Z, Wang S, Liu E et al. Comparative short- and long-term outcomes of three techniques of natural orifice specimen extraction surgery for rectal cancer. *Eur J Surg Oncol* 2020; 46(10 Pt B):e55-e61. DOI: 10.1016/j.ejso.2020.06.023.
 30. Chen MZ, Cartmill J, Gilmore A. Natural orifice specimen extraction for colorectal surgery: Early adoption in a Western population *Colorectal Dis* 2021; 23(4):937-943. DOI: 10.1111/codi.15455.
 31. Park JS, Kang H, Park SY et al. Long-term outcomes after Natural Orifice Specimen Extraction versus conventional laparoscopy-assisted surgery for rectal cancer: a matched case-control study. *Ann Surg Treat Res* 2018; 94:26–35.
 32. Fu CG, Zhou ZQ, Huang B. Low Anterior Resection with Transanal Specimen Extraction Using Rectal Eversion Technique. *Publish ahead of Print Dis Colon Rectum*, 2022. DOI: 10.1097/DCR.0000000000002497
 33. Franklin Jr ME¹, Liang S, Russek K. Natural orifice specimen extraction in laparoscopic colorectal surgery: transanal and transvaginal approaches. *Tech Coloproctol* 2013; 7 (1): S63-7. DOI: 10.1007/s10151-012-0938-y
 34. Wolthuis AM, Fieuws S, Van Den Bosch A et al. Randomized clinical trial of laparoscopic colectomy with or without natural-orifice specimen extraction. *Br J Surg* 2015; 102:630–7.
 35. Leung AL, Cheung HY, Fok BK et al. Prospective randomized trial of hybrid NOTES colectomy versus conventional laparoscopic colectomy for left-sided colonic tumors. *World J Surg* 2013; 37:2678–82.
 36. Ma B, Huang XZ, Gao P et al. Laparoscopic resection with natural orifice specimen extraction versus conventional laparoscopy for colorectal disease: a meta-analysis. *Int J Colorectal Dis* 2015; 30:1479–88.
 37. Palanivelu C, Rangarajan M, Jategaonkar PA, Anand NV. An innovative technique for colorectal specimen retrieval: a new era of “natural orifice specimen extraction” (N.O.S.E). *Dis Colon Rectum* 2008;51(07):1120–1124.