

The Impact of Ghost Ileostomy on Anastomotic Leakage: Selecting Eligible Patients for Surgery and Early Detection of Leakage; a Retrospective Case Series

Alimohammad Bananzadeh¹, MD; Amir Askari^{2*}, MD; Leila Ghahramani³, MD; Mahshid Bahadori³, MD; Sara Shojaei-Zarghani³, PhD; Seyed Vahid Hosseini³, MD

¹Laparoscopy Research Center, Shiraz University of Medical Sciences, Shiraz, Iran

²Department of General Surgery, Shiraz University of Medical Sciences, Shiraz, Iran

³Colorectal Research Center, Shiraz University of Medical Sciences, Shiraz, Iran

*Corresponding author:

Amir Askari, MD; Department of General Surgery, Shiraz University of Medical Sciences, Postal code: 7193635899, Shiraz, Iran. Tel/Fax: +98 71 32330724
Email: amiraskari.md@gmail.com

Received: 2024-02-14

Revised: 2024-03-10

Accept: 2024-03-25

Abstract

Background: Anastomotic leakage (AL) is the main complication of colorectal surgeries. Recent studies have assessed the effects of the ghost ileostomy on preventing complications related to a defunctioning stoma (DS) in high-risk anastomoses. In this study, we aimed to review patients who underwent ghost ileostomy and assess their colon leakage score (CLS) and Dutch leakage score (DULK) to evaluate their preoperative AL risk and post-operative AL diagnostic score, respectively. We examined whether the suggested cut-off points of these scores (>11 for CLS and >4 for DULK) could be appropriate criteria for determining when to insert ghost ileostomy and when to convert it to a DS.

Methods: All patients from three referral hospitals in Shiraz, Iran who underwent colorectal surgery with ghost ileostomy during 2019-2020 were enrolled in this retrospective case series. We calculated preoperative CLS and post-operative DULK scores for all patients and assessed what diagnostic and therapeutic measures were performed for them based on their scores.

Results: AL was diagnosed in two of 34 patients. Eight patients had a total CLS score of 11 and above, but only one of them experienced AL. The other case of AL had a CLS score of 10. The DULK score of these two patients increased during hospitalization.

Conclusion: Because of the importance of accurately identifying high-risk patients for ghost ileostomy, it is imperative to undertake additional research aimed at determining the optimal cut-off value for CLS or devising alternative valid scoring systems. DULK score could be an appropriate post-operative monitoring tool to reduce morbidity.

Keywords: Anastomotic leak, Ghost ileostomy, Surgical stomas, Colorectal surgery

Please cite this paper as:

Bananzadeh AM, Askari A, Ghahramani L, Bahadori M, Shojaei-Zarghani S, Hosseini SV. The Impact of Ghost Ileostomy on Anastomotic Leakage: Selecting Eligible Patients for Surgery and Early Detection of Leakage; a Retrospective Case Series. *Iran J Colorectal Res*.

Introduction

Anastomotic leakage (AL) is the main complication of colorectal surgeries (1), occurring in 3-21% of laparotomy and laparoscopic procedures (2). Despite advancements in anastomotic techniques, postoperative monitoring, and diagnostic tools, the prevalence and complications of AL have not significantly decreased in the past fifty years (3). AL refers to any defect in the intestinal wall that creates a connection between the inside and outside of the gastrointestinal tract at the site of a colorectal or colonic anastomosis (4). Pelvic abscesses near the anastomosis site are also considered AL, even if they do not connect with the gastrointestinal tract (5). Clinical signs of AL typically begin with nonspecific symptoms such as abdominal pain and distension. In some cases, extra-intestinal symptoms such as atrial fibrillation or altered consciousness may also occur (6). Some risk factors for AL include male sex, smoking, alcohol use, obesity, preoperative use of steroids and non-steroidal analgesics, longer operation duration, preoperative transfusion of blood products, contamination of the surgical site, and emergency surgeries (2, 3). While the best approach to AL is prevention, prompt diagnosis, and treatment can reduce the severity of morbidity (7). AL is often not diagnosed until the fifth to seventh day after surgery, resulting in a significant delay in diagnosis in many cases. Furthermore, the lack of comprehensive agreement on the sensitivity and specificity of diagnostic methods complicates the identification of this condition. The main reason for these problems is the unclear pathophysiology of AL (6).

One method of protecting the anastomosis from AL is by applying a defunctioning stoma (DS) proximal to the site of anastomosis. However, it is unclear whether DS effectively prevents AL or reduces its complications (3). Furthermore, previous studies have demonstrated noticeable morbidity associated with DS placement and the subsequent surgery for its closure (8). Thus, in 2007, the ghost (virtual) ileostomy technique was introduced as a means to prevent ileostomy insertion in patients who do not derive benefits from it and whose anastomoses were at risk for leakage (9). Subsequent studies have assessed the safety and efficacy of ghost ileostomy as an alternative to DS (10). However, there is currently no consensus on the priority of ghost ileostomy over DS, the appropriate conditions for choosing ghost ileostomy, and when to convert a ghost ileostomy to a DS. Therefore, we aimed to assess patients who underwent ghost ileostomy, based on the colon leakage score (CLS) criteria as a predictive measure of leakage before surgery (11) and the Dutch leakage score (DULK) criteria as an indicator of leakage in the postoperative period (12). We aimed to establish a cornerstone for identifying patients who may benefit from ghost ileostomy insertion.

Patients and Methods

This case series retrospectively examined all patients who underwent colorectal anastomosis with the insertion of a ghost ileostomy in three referral hospitals affiliated with Shiraz University of Medical Sciences during 2019-2020. This study was conducted by the Declaration of Helsinki and was approved by the Ethics Committee of Shiraz University of Medical Sciences, Shiraz, Iran (Code: IR.SUMS.MED.REC.1399.634). All included patients provided written informed consent.

There were no written criteria for patient selection for ghost ileostomy placement; however, it was considered that certain patients were not suitable candidates for ghost ileostomy, such as those with diabetes mellitus, immunodeficiency, a history of radiotherapy, malnutrition (albumin<2.5), inflammatory bowel disease, a history of corticosteroid use, and hemodynamic instability during the operation. Patients who underwent very low anterior resection or colo-anal anastomosis were also deemed unfit for the ghost ileostomy insertion. In these cases, a DS was inserted instead of a ghost ileostomy. Patients without the mentioned characteristics, who were at high risk for AL, as determined by their medical condition, the surgical procedure, and the surgeon's discretion, underwent a ghost ileostomy.

Ghost ileostomy involves encircling an elastic tape around the terminal ileum, opening the mesentery adjacent to the intestine, and extracting the elastic tape from the right iliac fossa, where the DS is typically inserted (13).

According to the protocols of the Colorectal Surgery Department at Shiraz University of Medical Sciences, patients remained admitted to the hospital for five days after the operation and were monitored daily for white blood cell (WBC) count, kidney function, vital signs, abdominal examination findings, and drainage tube output. If all these parameters were normal and no leak was suspected, the tape of the ghost ileostomy was removed from the skin and the patient was discharged with a one-week follow-up appointment. However, if an AL was suspected, diagnostic measures such as contrast-enhanced abdominal CT scan, sonography, and water-soluble contrast enema were performed (14, 15). If AL was confirmed by these tests, the ghost ileostomy was converted to a DS.

For the assessment of the risk of AL before surgery, we calculated the CLS for each patient who underwent a ghost ileostomy. This score considers 11 risk factors for AL, including age, sex, the American Society of Anesthesiologists (ASA) grade, body mass index, history of intoxication (smoking, alcohol, steroids), neoadjuvant therapy, history of emerging surgery, distance of anastomosis to the anal verge, need for additional procedures, amount of blood loss, and duration of operation. All variables

are quantified numerically, and a total score greater than 11 is considered an indicator of risk of AL and insertion of a DS (11).

Furthermore, using the DULK score, we calculated the probability of AL in each postoperative day until patients were discharged. This scoring system helps in the early detection of AL and reduces mortality and morbidity. The DULK score considers body temperature, pulse rate, respiratory rate, oliguria, agitation or lethargy, clinical deterioration, ileus, gastroparesis, evisceration, abdominal or parietal pain, elevated WBC or CRP levels, elevated blood creatinine or urea, enteral nutrition tube, parenteral nutrition. A DULK score of 4 or higher indicates a requirement for further investigation for AL diagnosis (12).

Results

Table 1 presents a summary of the characteristics of the 34 patients enrolled in this study. Of these, 14 (41.2%) were men and 20 (58.8%) were women. The CLS ranged from 4 to 15 across patients, with eight patients having a CLS score higher than 11. Furthermore, 31 patients had a DULK score of less than 4 on all admission days. Only two (5.8%)

patients experienced AL, while the remaining patients were discharged without any complications.

The first case of AL had a CLS score of 10. After surgery, this patient experienced abdominal pain and the clinical condition deteriorated, resulting in a DULK score of 4 on the fifth postoperative day. On the following day, signs of bowel obstruction developed and the DULK reached 6. At this time, an abdominopelvic CT scan with contrast was performed, which confirmed AL, leading to the patient being transferred to the operating room. During abdominal exploration, confined leakage was diagnosed and the ghost ileostomy was converted to DS. After irrigation of the pelvic cavity, the anastomosis site was repaired.

In another case of leakage, the CLS was 14 before surgery. On the third and fourth postoperative days, the DULK score reached 5. On the fifth day, it reached 10 and because of bowel content from abdominal drains, the patient was transferred to the operating room where the anastomosis was taken down and an end colostomy was created.

Figure 1 shows the DULK scores of these two patients during their hospitalization. The first and the second cases were re-operated on the 6th and 7th day after the surgery, respectively.

Table 1: Demographic and clinical features of the included patients

Characteristics	Categories	N (%)
Age, years	<60	24 (70.6)
	60-69	6 (17.6)
	70-79	1 (2.9)
	>80	3 (8.8)
Sex	Male	14 (41.2)
	Female	20 (58.8)
Body mass index (kg/m ²)	19-24	15 (44.1)
	25-30	15 (44.1)
	<19 or >30	4 (11.8)
Smoking	No	26 (76.5)
	Yes	8 (23.5)
Alcohol consumption (units/day)	<3	34 (100)
	>3	0 (0.0)
ASA intake	1	13 (38.2)
	2	15 (44.1)
	3	6 (17.6)
	4	0 (0.0)
Steroid consumption	No	34 (100)
	Yes	0 (0.0)
Distance of the anastomosis to the anal verge (cm)	>10	16 (47.1)
	5-10	14 (41.2)
	<5	4 (11.8)
History of additional procedures	No	23 (67.6)
	Yes	11 (32.4)
Blood loss or transfusion (L)	<0.5	20 (58.8)
	0.5-1	10 (29.4)
	1-2	4 (11.8)
	>2	0 (0.0)
Duration of the operation (hours)	<2	1 (2.9)
	2-3	4 (11.8)
	3-4	9 (26.5)
	>4	20 (58.8)

ASA: American Society of Anesthesiologists grade

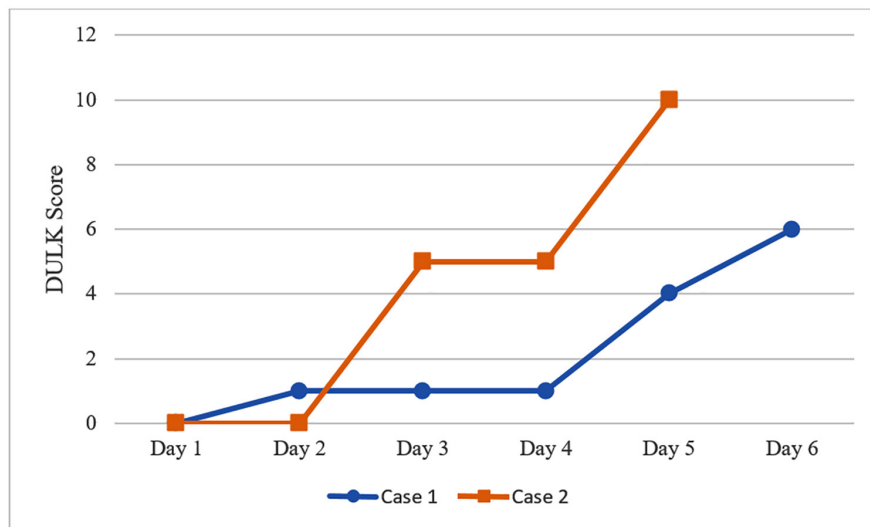


Figure 1: The trend of DULK score of two patients diagnosed with anastomotic leakage during hospitalization is shown. DULK: Dutch leakage score

Discussion

This study retrospectively examined patients who underwent ghost ileostomy following colorectal surgery at Shiraz University of Medical Sciences. Several studies have assessed the potential effectiveness of this technique compared to DS. However, a recent meta-analysis showed no differences in the prevalence of AL, major complications, short-term morbidity, and length of stay between ghost ileostomy and loop ileostomy (10). Nonetheless, this technique is relatively easy to perform and is associated with fewer episodes of dehydration, ileus after primary surgery, and readmissions after primary surgery compared with DS (16).

In our study, two (5.8%) patients experienced AL following ghost ileostomy. The pre-operative evaluation revealed that out of eight patients with a CLS score above 11, only one experienced AL, while the other case of AL had a CLS score of 10. Given the wide range of CLS scores observed in the patients (4-15), it appears that patient selection for ghost ileostomy was not performed based on appropriate criteria. We considered a CLS score above 11 as a predictor of AL, as indicated by Dekker and colleagues, who determined this threshold acceptable for inserting a DS (11). It should be noted that their study was not specifically designed to assess the application of ghost ileostomy. This score seems to be an appropriate objective measure for inserting ghost ileostomy; however, the related cut-off value requires further testing in future studies. Nevertheless, our study was conducted on a small group of patients and the results should be interpreted with caution.

Morbidity and mortality rates of AL are directly correlated with its detection time. The delayed diagnosis of complications in our population may be attributed to the absence of a scoring criterion for early AL detection. There are various clinical and laboratory criteria, including procalcitonin and

C-reactive protein levels (17-19), as well as several criteria and scores for early detection of AL. One of the scoring criteria is the DULK criteria, which has been proven to have a high positive predictive value (12). A DULK score of 4 or higher is suggested as a useful clinical tool in the early diagnosis of AL (12). According to our findings, both patients with leakage had a DULK score higher than 4 at least two days before re-operation, indicating that we were able to do earlier diagnostic and therapeutic measures on the 3rd to 5th post-operation days if this criterion was used for suspicion of AL. If we had suspected leakage earlier, this complication could potentially have been treated by converting ghost ileostomy to DS instead of re-laparotomy to give this chance for distal anastomosis to heal spontaneously. Therefore, none of the patients with leakage in our study benefited from ghost ileostomy because of the lack of proper criteria for early detection of AL. It is worth noting that in our study, one patient had a DULK score of 4 only on the sixth and ninth day following surgery, but did not experience AL. During our study, we did not encounter any complications resulting from ghost ileostomy insertion. Therefore, it seems reasonable to consider this method in cases at high risk for AL.

Conclusion

Ghost ileostomy may be a suitable option for patients at risk for AL identified by a valid screening tool. However, it is necessary to closely follow these patients after surgery using valid scoring systems such as DULK to promptly diagnose and treat AL, to minimize morbidity. To better assess the superiority of ghost ileostomy and its advantages and disadvantages, a prospective study should be conducted with appropriate patient screening and follow-up. Additionally, more accurate scoring systems and screening methods should be developed to select the best method (DS, ghost ileostomy, or none) for each patient.

Acknowledgment

The present article is derived from a thesis by Amir Askari, which was submitted to the medical school as a partial fulfillment of the requirements for the degree of Doctor of Medicine. We thank the medical school of Shiraz University of Medical Sciences for financial and scientific support.

Availability of Data and Materials

Data are available from the corresponding author upon request.

Funding

This study was supported by the Vice-Chancellor for Research and Technology of Shiraz University of

Medical Sciences (Code: 21665). The funder had no role in the study design, analysis, decision to publish, or manuscript preparation.

Authors' Contribution

Conceptualization: A.B., A.A., L.G., M.B., S.V.H.; Methodology: A.B., A.A., L.G., M.B., S.V.H.; Data curation: A.B., A.A., S.S.Z.; Project administration, Validation: A.B.; Writing – original draft: A.A., S.S.Z, Writing – review & editing: A.B., A.A., L.G., M.B., S.V.H. All authors have read and approved the final version and agreed to be accountable for all aspects of the work in ensuring that questions related to the accuracy or integrity of any part of the work are appropriately investigated and resolved.

Conflict of interest: None declared.

References

- Gulla N, Trastulli S, Boselli C, Cirocchi R, Cavaliere D, Verdecchia GM, et al. Ghost ileostomy after anterior resection for rectal cancer: a preliminary experience. *Langenbecks Arch Surg.* 2011;396(7):997-1007.
- McDermott F, Heeney A, Kelly M, Steele R, Carlson G, Winter D. Systematic review of preoperative, intraoperative, and postoperative risk factors for colorectal anastomotic leaks. *British Journal of Surgery.* 2015;102(5):462-79.
- Vallance A, Wexner S, Berho M, Cahill R, Coleman M, Haboubi N, et al. A collaborative review of the current concepts and challenges of anastomotic leaks in colorectal surgery. *Colorectal Dis.* 2017;19(1):O1-O12.
- Rahbari NN, Weitz J, Hohenberger W, Heald RJ, Moran B, Ulrich A, et al. Definition and grading of anastomotic leakage following anterior resection of the rectum: a proposal by the International Study Group of Rectal Cancer. *Surgery.* 2010;147(3):339-51.
- Kulu Y, Ulrich A, Bruckner T, Contin P, Welsch T, Rahbari NN, et al. Validation of the International Study Group of Rectal Cancer definition and severity grading of anastomotic leakage. *Surgery.* 2013;153(6):753-61.
- Ellebæk M, Qvist N. Early detection and the prevention of serious complications of anastomotic leakage in rectal cancer surgery. Springer; 2014.
- Dupré A, Slim K. Fistule anastomotique après chirurgie colorectale: peut-on la détecter plus facilement et plus tôt? : Elsevier Masson; 2012. p. 329-30.
- Rathnayake M, Kumarage S, Wijesuriya S, Munasinghe B, Ariyaratne M, Deen K. Complications of loop ileostomy and ileostomy closure and their implications for extended enterostomal therapy: a prospective clinical study. *International journal of nursing studies.* 2008;45(8):1118-21.
- Sacchi M, Legge PD, Picozzi P, Papa F, Giovanni CL, Greco L. Virtual ileostomy following TME and primary sphincter-saving reconstruction for rectal cancer. *Hepato-gastroenterology.* 2007;54(78):1676-8.
- McKechnie T, Lee J, Lee Y, Tessier L, Amin N, Doumouras A, et al. Ghost Ileostomy Versus Loop Ileostomy Following Oncologic Resection for Rectal Cancer: A Systematic Review and Meta-Analysis. *Surgical Innovation.* 2023;15533506231169066.
- Dekker JWT, Liefers GJ, van Otterloo JCdM, Putter H, Tollenaar RA. Predicting the risk of anastomotic leakage in left-sided colorectal surgery using a colon leakage score. *Journal of Surgical Research.* 2011;166(1):e27-e34.
- Den Dulk M, Witvliet M, Kortram K, Neijenhuis P, De Hingh I, Engel A, et al. The DULK (Dutch leakage) and modified DULK score compared: actively seek the leak. *Colorectal Disease.* 2013;15(9):e528-e33.
- Miccini M, Amore Bonapasta S, Gregori M, Barillari P, Tocchi A. Ghost ileostomy: real and potential advantages. *Am J Surg.* 2010;200(4):e55-7.
- Samji KB, Kielar AZ, Connolly M, Fasih N, Doherty G, Chung A, et al. Anastomotic leaks after small-and large-bowel surgery: diagnostic performance of CT and the importance of intraluminal contrast administration. *American Journal of Roentgenology.* 2018;1259-65.
- Nicksa G, Dring R, Johnson K, Sardella W, Vignati P, Cohen J. Anastomotic leaks: what is the best diagnostic imaging study? *Diseases of the colon & rectum.* 2007;50:197-203.
- Zizzo M, Morini A, Zanelli M, Tumiatì D, Sanguedolce F, Palicelli A, et al. Short-Term Outcomes in Patients Undergoing Virtual/Ghost Ileostomy or Defunctioning Ileostomy after Anterior Resection of the Rectum: A Meta-Analysis. *Journal of Clinical Medicine.* 2023;12(11):3607.
- Warschkow R, Beutner U, Steffen T, Müller SA, Schmied BM, Güllér U, et al. Safe and early discharge after colorectal surgery due to C-reactive protein: a diagnostic meta-analysis of 1832 patients. *Annals of surgery.* 2012;256(2):245-50.
- Takakura Y, Hinoi T, Egi H, Shimomura M, Adachi T, Saito Y, et al. Procalcitonin as a predictive marker for surgical site infection in elective colorectal cancer surgery. *Langenbeck's archives of surgery.* 2013;398:833-9.
- Lagoutte N, Facy O, Ravoire A, Chalumeau C, Jonval L, Rat P, et al. C-reactive protein and procalcitonin for the early detection of anastomotic leakage after elective colorectal surgery: pilot study in 100 patients. *Journal of visceral surgery.* 2012;149(5):e345-e9.