

Hypertrophic Variant of Lichen Planus in the Anogenital Area: A Clinical Case

Aleksey Alekseevich Khryanin^{1,2*}, PhD;  Asya V. Sokolovskaya¹, MD; Valentina K Bocharova³, MD

¹Novosibirsk State Medical University, Novosibirsk, Russia

²Department of Obstetrician-Gynecologists and Dermatologists, Novosibirsk, Russia

³Pavlov First Saint Petersburg State Medical University, Saint Petersburg, Russia

*Corresponding author:

Aleksey Alekseevich Khryanin, Department of Dermatovenereology and Cosmetology of the Novosibirsk State Medical University of the Ministry of Health of Russia, 52, Krasny Prospect, 630091, Novosibirsk, Russia. Tel: +7 913 9202886
Email: khryanin@mail.ru

Received: 13-02-2023

Revised: 26-03-2023

Accepted: 26-03-2023

Abstract

Introduction: Dermatoses localized to the anogenital area (AGA) are an urgent problem of modern medicine. The similar clinical pictures of most skin diseases in this area pose a challenge to clinicians as the effectiveness of treatment depends on the accuracy of the diagnosis. The article presents modern data on various forms of lichen planus in the AGA. We discuss the relationship of the disease with pathological conditions, such as dyslipidemia, hypothyroidism, and diabetes mellitus. Special attention is paid to the hypertrophic variant of lichen planus in the AGA, which has the most complex clinical picture for diagnosis and is least described in the scientific literature.

Case Presentation: The authors present a complex interdisciplinary clinical case of lichen planus in the anogenital region.

Conclusion: The joint work of a dermatovenerologist, proctologist, obstetrician-gynecologist, urologist, oncologist, pathologist, and surgeon provides a faster and more accurate diagnosis of diseases, facilitating timely and adequate treatment tactics. The presented clinical case will help practitioners better navigate the issues of diagnosing skin diseases in the anogenital area.

Keywords: Lichen planus, Risk factor, Skin diseases

Please cite this paper as:

Khryanin AA, Sokolovskaya AV, Bocharova VK. Hypertrophic Variant of Lichen Planus in the Anogenital Area: A Clinical Case. *Iran J Colorectal Res.* 2023;11(1):50-53. doi: 10.30476/ACRR.2023.98870.1178.

Introduction

Lichen planus (LP) is a chronic T-cell dermatosis of unknown etiology affecting the skin, mucous membranes, and nails (1-5). One of the main histopathological signs of LP is vacuole degeneration of keratinocytes in the basal layer, resulting from the action of T-helper lymphocytes, T-cytotoxic lymphocytes, natural killer cells, and dendritic cells

that predominate in the inflammatory infiltrate. LP's main pathogenetic mechanisms are keratinocyte apoptosis enhancement and T-lymphocyte apoptosis inhibition (2). The factors initiating these violations are still unknown.

According to epidemiological estimates, the prevalence of LP ranges from 0.22% to 5% worldwide (5, 6). LP usually affects middle-aged adults of both sexes, but data indicate the predominance of LP in

women over men in a ratio of 2:1 (5).

LP most often affects the skin of the flexor surfaces of the extremities and manifests itself in the form of small itchy purple papules in middle-aged people. LP on the mucous membranes can occur in the mouth, genital area, gastrointestinal tract, and eyes (1-5).

As a rule, three types of LP are detected in women in the anogenital area (AGA): erosive-ulcerative, classical, and hypertrophic (6, 7).

In men, clinical variants of LP have not been officially identified when localized to the AGA, but typical, circinal, and erosive-ulcerative forms of the disease are more common (4, 6).

Controversy continues regarding the link between LP and skin squamous cell carcinoma (SCC). Some studies indicate a link between the hypertrophic form of LP and malignant transformation into SCC, explaining this by chronic inflammation, a known risk factor for developing SCC (8, 9). At the same time, other studies show little evidence of malignant transformation of both hypertrophic and erosive forms of LP (10, 11).

The hypertrophic variant of LP in the AGA has the most difficult clinical picture for diagnosis and is the least described in the scientific literature, which may explain the low rates of its prevalence. The hypertrophic variant of LP is usually devoid of the porcelain-white (Wickham) mesh on the surface of the papules. Instead, it presents as erythematous papules and edema of the surrounding skin and mucosa. The papules often have a macerated or skin-like uneven surface, sometimes located against the background of lichenification (12).

The manifestation of papulosquamous and hypertrophic variants of vulvar LP is similar to the corresponding subtypes of the oral form of LP. In most cases (43–100%) of vulvar LP, concomitant damage to the oral mucosa is seen, whereas about 25% of patients with oral LP also have vulvar damage (13). Simultaneous damage to the mucous membrane of the oral cavity, vulva, and vagina is known as vulvovaginal-gingival syndrome (14). Skin lesions in this syndrome occur in 17–22% of cases (15, 16). Therefore, if there is a suspicion of vulvar LP, an examination of the skin, nail plates, and oral mucous membranes is necessary.

It is assumed that LP is associated with certain pathological conditions, such as autoimmune diseases, malignant neoplasms, stress, and viral infections, the most significant of which is viral hepatitis C (16). Also interesting is the relationship between the incidence of LP and the presence of dyslipidemia and diabetes mellitus. The development of LP in the oral mucosa may be associated with hypothyroidism. Therefore, it is necessary to screen for dyslipidemia and type II diabetes mellitus in all patients with LP (17).

Differential diagnoses of the hypertrophic form of LP include psoriasis of the anogenital area, nodular pruritus, lichenoid cutaneous amyloidosis,

Kaposi's sarcoma, and chronic lichen simplex (18). However, these dermatoses are extremely difficult to differentiate since they all demonstrate papillary fibrosis of the skin and pronounced acanthosis. The only factor distinguishing the hypertrophic variant of LP is the degeneration of the basal layer, which can be masked by inflammatory infiltration (19). In addition, the hypertrophic variant of LP can be confused with microinvasive SCC, and granulomatous infiltrates can be misinterpreted as systemic autoimmune or infectious diseases (20).

Case Presentation

A 31-year-old woman visited a proctologist in November 2022, complaining of a significant increase in size and a change in the consistency of the labia majora with a transition to the perineum and perianal area. She had no pain, itching, burning, or abnormal vaginal discharge. The signs appeared about four years ago and began with the swelling of one labia. Gradually, the process spread to the second labia, as well as to the perianal area and the perineum area. The woman noted a significant deterioration after pregnancy and natural childbirth in 2021.

The patient had previously been managed by obstetricians-gynecologists, allergologists/immunologists, oncologists, and endocrinologists, though the diagnosis was yet to be established, and a cure had not been achieved. In 2019, a biopsy was performed; initially, the oncologist assumed the diagnosis of "giant warts of Buschke-Levenstein," but this diagnosis was not confirmed histologically. In December 2022, a second biopsy was performed. Histology again did not give an unambiguous result, concluding on a fibroepithelial polyp of the skin in the form of a fibrous stromal rod and a hyperplastic multilayer flat keratinizing epithelium without atypia and without any inflammatory infiltration.

On examination, the labia majora were significantly enlarged, swollen, slightly hyperemic, and pigmented. On palpation, the labia majora were soft-elastic, edematous, and painless, without areas of compaction. There was a similar picture in the perineum, perianal skin, and external hemorrhoids in the area where fibrous changes and edema were determined (Figures 1A and B). Palpation was painless.

A colonoscopy revealed no specific pathologies. Magnetic resonance imaging (MRI) of the pelvic organs did not indicate varicose veins or volumetric formations but revealed lymphadenopathy of the iliac lymph nodes (probably of inflammatory origin). Through consultation with a dermatovenerologist, a repeat biopsy was planned from the most altered and elevated area.

According to the results of the third biopsy (January 2023), the diagnosis was made: the hypertrophic form of lichen planus. The histological examination

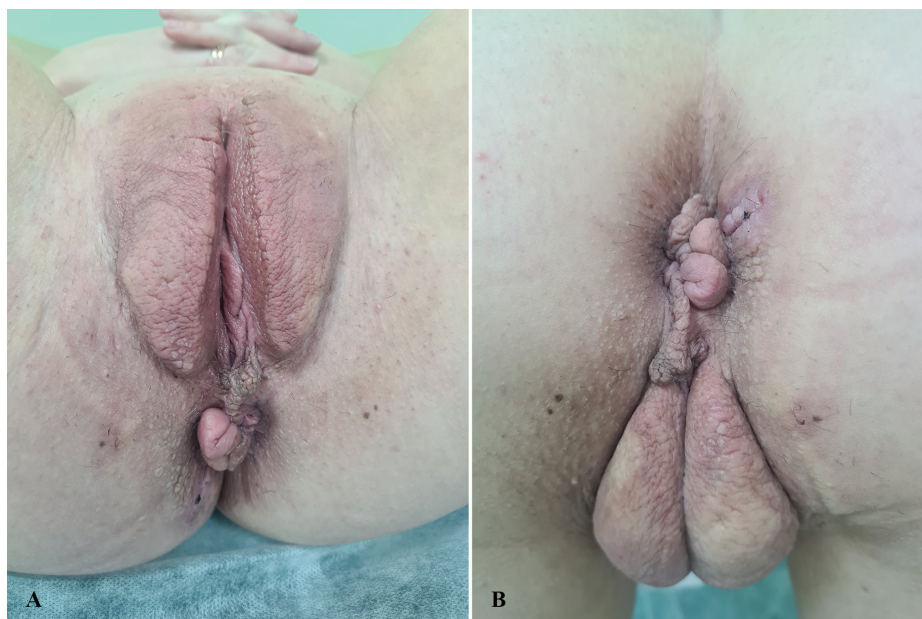

Figure 1: The external genitalia of the patient: A) Enlargement, swelling, and hyperemia of the labia majora; B) Perianal area, showing fibrous changes and edema of the external hemorrhoidal catch.

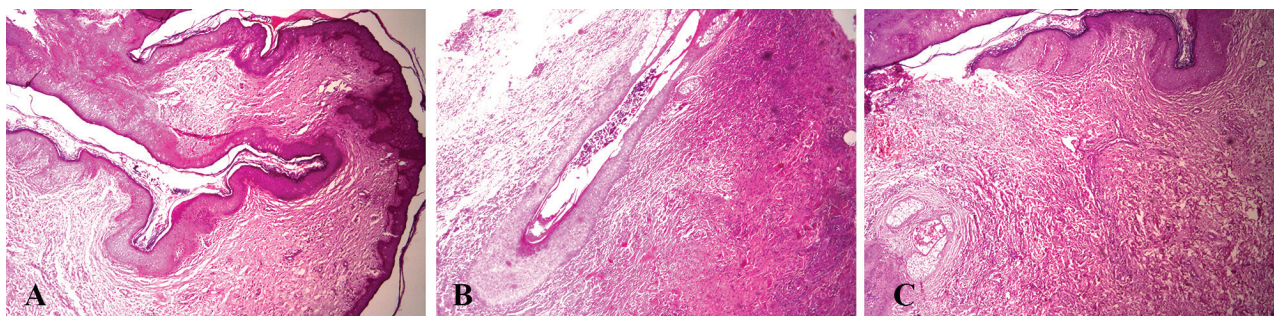


Figure 2: Histological examination of a skin biopsy. Staining with hematoxylin and eosin: A) In the epidermis, there are signs of vacuole dystrophy in epithelial cells, acanthosis, and papillomatosis with hyperkeratosis. Magnification $\times 100$. B) In the epidermis, corneal matter accumulates at the mouth of the follicle. Magnification $\times 100$. C) In the epidermis, signs of vacuole dystrophy of epithelial cells (including basal layer cells) are evident. Hemorrhage foci are detected in the dermis, with diffuse moderately pronounced inflammatory lymphocyte/macrophage infiltration and the presence of plasmacytes. Sclerosis is seen in the upper dermis. Magnification $\times 200$.

of the epidermis revealed signs of vacuole dystrophy in epithelial cells (including cells of the basal layer), acanthosis, and papillomatosis (Figure 2A), with hyperkeratosis and accumulation of corneal matter at the mouth of the follicles (Figure 2B). Hemorrhage foci were detected in the dermis, along with diffuse moderately pronounced inflammatory infiltration from lymphocytes, macrophages, with the presence of plasmacytes and sclerosis (Figure 2C). Findings in the deep parts of the dermis were fullness and focal inflammatory infiltration from lymphocytes and macrophages.

Laboratory examination confirmed the patient's insulin resistance. Hepatitis B and C viruses were not detected. The lipid profile was normal. Syphilis, HIV infection, and STIs were not detected.

Our final diagnosis was the hypertrophic form of lichen planus associated with insulin resistance. The patient was managed as per federal clinical guidelines. We prescribed 0.1% betamethasone ointment twice daily (morning and evening) on the skin in the area of rashes for 12 weeks. After 12 weeks, we plan a second consultation with the

dermatovenerologist to assess the effectiveness of local treatment and, if necessary, decide on the appointment of systemic therapy. We also referred the patient to an endocrinologist.

Discussion

Difficulties often arise in the treatment of LP in the AGA. Firstly, this is due to the persistent course of LP of this localization; secondly, a relatively small number of randomized placebo-controlled studies on LP therapy in the AGA exist, causing a low level of credibility and reliability of recommendations (the level of credibility of recommendations C) (1). The first-line drugs in treating LP in the AGA are ultra-strong topical glucocorticosteroids with a further transition to weaker topical glucocorticosteroids. Topical calcineurin inhibitors, recommended in the case of the ineffectiveness of topical glucocorticosteroids, serve as an alternative treatment option (1, 6). Systemic therapy of LP is carried out in combination with local therapy or in the absence of a response to topical glucocorticosteroids

and calcineurin inhibitors. Systemic options include glucocorticosteroids (oral or injectable dosage forms), methotrexate, cyclosporine, and hydroxychloroquine (6). However, unlike systemic glucocorticosteroids, the latter drugs lack a convincing evidence base in treating LP in the AGA (1, 6).

Conclusion

Dermatoses of AGA are often found in clinical practice, posing a diagnostic challenge due to similar clinical presentations, with the effectiveness of treatment depending on the accuracy of the diagnosis. Dynamic observation, involvement of related specialists, and the use of various diagnostic methods, such as laboratory tests, dermatoscopy, histological examination, and transdermal imaging methods (ultrasound, MRI), are often required. The joint work of a dermatovenerologist, proctologist, obstetrician-gynecologist, urologist, oncologist, pathologist, and surgeon provides a faster and more accurate diagnosis, facilitating timely and adequate treatment.

References

1. Khurana A, Tandon S, Marfatia YS, Madnani N. Genital lichen planus: An underrecognized entity. *Indian journal of sexually transmitted diseases and AIDS*. 2019;40(2):105-12.
2. Day T, Wilkinson E, Rowan D, Scurry J. Clinicopathologic Diagnostic Criteria for Vulvar Lichen Planus. *Journal of lower genital tract disease*. 2020;24(3):317-29.
3. Amsellem J, Skayem C, Duong TA, Bagot M, Fouéré S, Dauendorffer JN. Male genital lichen planus: A retrospective study of 89 cases. *Annales de dermatologie et de venerologie*. 2022;149(1):28-31.
4. Cassol-Spanemberg J, Blanco-Carrion A, Rodriguez-de Rivera-Campillo ME, Estrugo-Devesa A, Jané-Salas E, López-López J. Cutaneous, genital and oral lichen planus: A descriptive study of 274 patients. *Medicina oral, patologia oral y cirugía bucal*. 2019;24(1):e1-e7.
5. Ioannides D, Vakirlis E, Kemeny L, Marinovic B, Massone C, Murphy R, et al. European S1 guidelines on the management of lichen planus: a cooperation of the European Dermatology Forum with the European Academy of Dermatology and Venereology. *Journal of the European Academy of Dermatology and Venereology : JEADV*. 2020;34(7):1403-14.
6. Chew A, Stefanato CM, Savarese I, Neill SM, Fenton DA, Lewis FM. Clinical patterns of lichen planopilaris in patients with vulvar lichen planus. *The British journal of dermatology*. 2014;170(1):218-20.
7. Goldstein AT, Metz A. Vulvar lichen planus. *Clinical obstetrics and gynecology*. 2005;48(4):818-23.
8. Weston G, Payette M. Update on lichen planus and its clinical variants. *International journal of women's dermatology*. 2015;1(3):140-9.
9. Regauer S, Reich O, Eberz B. Vulvar cancers in women with vulvar lichen planus: a clinicopathological study. *Journal of the American Academy of Dermatology*. 2014;71(4):698-707.
10. Day T, Otton G, Jaaback K, Weigner J, Scurry J. Is Vulvovaginal Lichen Planus Associated With Squamous Cell Carcinoma? *Journal of lower genital tract disease*. 2018;22(2):159-65.
11. Ramos-e-Silva M, Jacques C, Carneiro SC. Premalignant nature of oral and vulvar lichen planus: facts and controversies. *Clinics in dermatology*. 2010;28(5):563-7.
12. Moyal-Barracco M, Edwards L. Diagnosis and therapy of anogenital lichen planus. *Dermatologic therapy*. 2004;17(1):38-46.
13. Khryanin AA, Sokolovskaya A, Bocharova VK. Lichen planus associated with viral hepatitis C: clinical case. *%J Iranian Journal of Colorectal Research. Iranian Journal of Colorectal Research*. 2022;10(3):110-4.
14. Ramer MA, Altchek A, Deligdisch L, Phelps R, Montazem A, Buonocore PM. Lichen planus and the vulvovaginal-gingival syndrome. *Journal of periodontology*. 2003;74(9):1385-93.
15. Eisen D. The clinical features, malignant potential, and systemic associations of oral lichen planus: a study of 723 patients. *Journal of the American Academy of Dermatology*. 2002;46(2):207-14.
16. Cooper SM, Wojnarowska F. Influence of treatment of erosive lichen planus of the vulva on its prognosis. *Archives of dermatology*. 2006;142(3):289-94.
17. Rodriguez-Zúñiga MJM, García-Perdomo HA. Systematic review and meta-analysis of the association between psoriasis and metabolic syndrome. *Journal of the American Academy of Dermatology*. 2017;77(4):657-66.e8.
18. Gorouhi F, Davari P, Fazel N. Cutaneous and mucosal lichen planus: a comprehensive review of clinical subtypes, risk factors, diagnosis, and prognosis. *TheScientificWorldJournal*. 2014;2014:742826.
19. Patterson JW HG. Tissue reaction patterns, Section 2, and The dermis and subcutis, Section 4. . *Weedon's Skin Pathology*: Elsevier; 2014.
20. Ashton KA, Scurry J, Rutherford J, Otton G, Scott RJ, Bowden NA. Nodular prurigo of the vulva. *Pathology*. 2012;44(6):565-7.

Ethics Approval

Authors state that written informed consent by the patient was obtained. Authors state, that identifying information (including patient's name, initials, or hospital numbers) is not included in recordings, written descriptions, or photographs.

Authors' Contribution

Study concept and design: Khryanin A.A. Analysis and interpretation of data: Sokolovskaya A.V., Bocharova V.K. Drafting of the manuscript: Khryanin A.A., Bocharova V.K. Critical revision of the manuscript for important intellectual content: Khryanin A.A., Sokolovskaya A.V. All authors read and approve the final version. All authors agree to be accountable for all aspects of the work in ensuring that questions related to the accuracy or integrity of any part of the work are appropriately investigated and resolved.

Conflict of interest: None declared.