

## Sigmoid Diverticular Perforation in a 23-year-old Patient: A Case Report

Taygun Gülşen<sup>1\*</sup>, MD;  Tolga Dericî<sup>1</sup>, MD; İlker Sücüllü<sup>2</sup>, MD

<sup>1</sup>Department of General Surgery, Istanbul Sultanbeyli State Hospital, Istanbul, Turkey

<sup>2</sup>Department of General Surgery, Pendik Medipol University Hospital, Istanbul, Turkey

### \*Corresponding author:

Taygun Gülşen,  
Department of General Surgery, Istanbul Sultanbeyli State Hospital, Istanbul,  
Turkey. Tel: +531 5840059  
Email: taygun1538@hotmail.com

Received: 16-02-2023

Revised: 04-03-2023

Accepted: 04-03-2023

### Abstract

**Introduction:** Diverticulitis is inflammation of one or more adjacent diverticulums and the surrounding colon. Patients with diverticulitis typically present with acute or subacute abdominal pain in the left lower quadrant. Most patients are over 50; however, the disease is increasingly common in the younger. Diverticulitis may present with an acute abdomen by causing intra-abdominal perforation. Although it is infrequent, diverticulitis perforation should be considered when diagnosing young patients with acute abdomen.

**Case Presentation:** We present the case of a 23-year-old male with an acute abdomen secondary to diverticulitis perforation. The patient's physical examination and computed tomography scan were interpreted as perforation. We performed explorative laparotomy. During the operation, the stomach and other lumen organs were intact. There were diverticula in the sigmoid colon, intense inflammation in the colon serosa in the region of the diverticula, and a perforation area of 1 cm in diameter.

**Conclusion:** Diverticulitis usually presents with abdominal pain in the left lower quadrant of the elderly patient. However, it may present with an acute abdomen by causing intra-abdominal perforation. Although it is infrequent, diverticulitis perforation should be considered in the differential diagnosis of young patients presenting with acute abdomen.

**Keywords:** Diverticulitis, Acute abdomen, Diverticular disease, Young Adult

Please cite this paper as:

Gülşen T, Dericî T, Sücüllü İ. Sigmoid Diverticular Perforation in a 23-year-old Patient: A Case Report. *Iran J Colorectal Res.* 2023;11(1):46-49. doi: 10.30476/ACRR.2023.98109.1169.

### Introduction

Diverticulitis is inflammation of one or more adjacent diverticulums and the surrounding colon. Patients with diverticulitis typically present with acute or subacute abdominal pain in the left lower quadrant. Other common signs and symptoms include nausea without vomiting, low-grade fever, altered bowel habits, leukocytosis, and elevation

of inflammatory markers (1). Most patients are over 50; however, it is increasingly common in younger individuals (2). While most patients with diverticulosis are asymptomatic, 1-4% of them develop diverticulitis (3). One or more recurrent episodes of diverticulitis occur within ten years in 20% of patients who develop diverticulitis (4).

An acute abdomen is a common situation in surgical practice. Although there are many causes,

it can occur due to the perforation of hollow organs (5-7). Acute abdomen secondary to diverticulitis perforation is less common in young patients (8). Herein, we present the case of a 23-year-old male with an acute abdomen secondary to diverticulitis perforation.

### Case Presentation

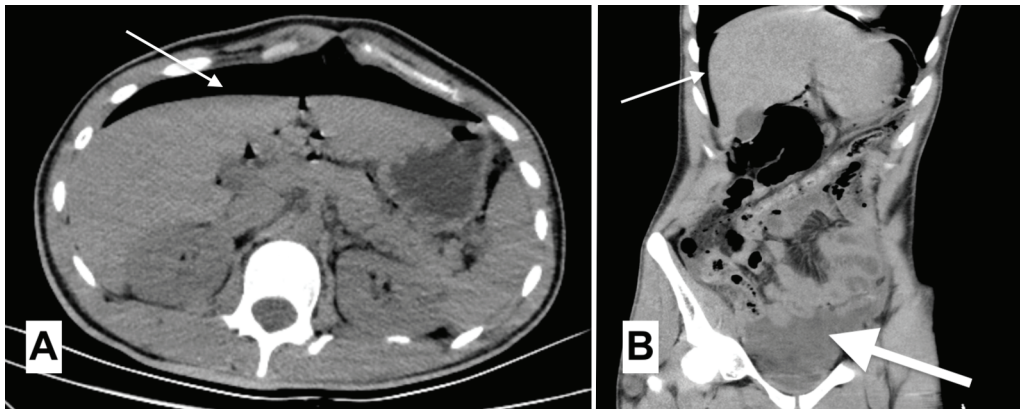
A 23-year-old male presented with severe abdominal pain commencing six hours earlier. Abdominal guarding and rebound tenderness were detected during the physical examination. The white blood cell count was  $12.2 \times 10^3/\mu\text{l}$ , C-reactive protein 10.2 (0-5 mg/l), and other laboratory parameters were in the normal range. Abdominal computed tomography (CT) revealed free air and fluid in the abdomen (Figure 1). After written informed consent was obtained, he was taken for an emergency operation with the preliminary diagnosis of intra-abdominal perforation.

Explorative laparotomy was performed, and the stomach and other lumen organs were intact. It was observed that there were diverticula in

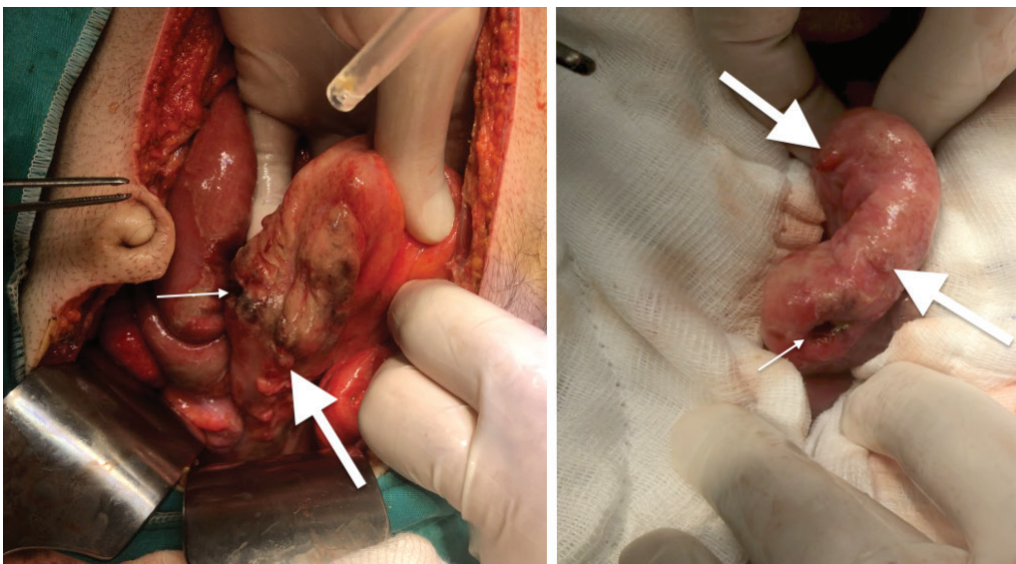
the sigmoid colon, intense inflammation in the colon serosa in the region of the diverticula, and a perforation area of 1 cm in diameter (Figure 2). Due to the patient's limited disease and young age, it was decided to perform a primary repair for the diverticulitis perforation. The perforation area was repaired primarily, omentopexy was performed on it, and the abdomen was washed with plenty of saline and aspirated. A drain was placed in the pelvis. The patient was started on antibiotic therapy in the postoperative period as ceftriaxone 2 x 1 g intravenous (IV) and metronidazole 3 x 500 mg IV. The patient's drain was removed on the fourth postoperative day, and he was discharged with a surgical cure on the fifth postoperative day. No additional pathology was observed in the colonoscopy performed on the third month postoperatively except for sigmoid diverticulosis (Figure 3).

### Ethics Approval

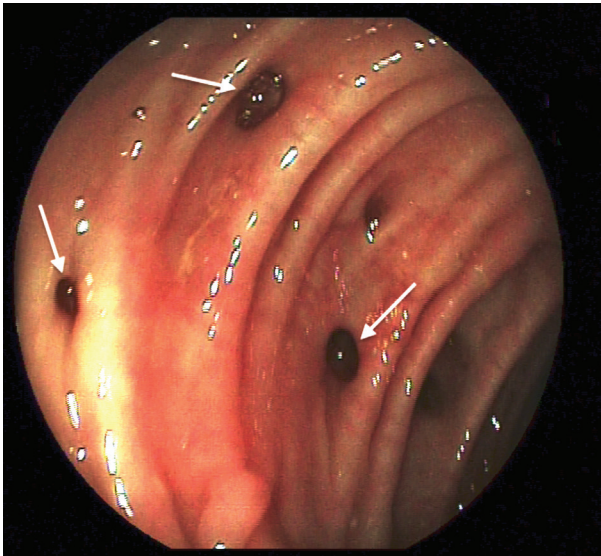
Written informed consent to publish potentially identifying information, such as details of the case and photographs, was obtained from the patient.



**Figure 1:** Abdominal computed tomography (CT) images of the intraabdominal perforation. (A): Axial image of the abdominal CT scan showing free air under the diaphragm (thin arrows). (B): Coronal reconstructed image of abdominal CT scan showing free air (thin arrows) and pelvic free fluid (thick arrow).



**Figure 2:** Intraoperative images of diverticular perforation. Intraoperative images of the sigmoid colon showing the point of perforation (thin arrows) and diverticula (thick arrows).



**Figure 3:** Colonoscopy view showing multiple diverticula in the sigmoid colon (white arrows).

### Discussion

The treatment approach for a patient with diverticulitis is planned according to the severity of the disease, the presence of complications, and the comorbid diseases in the patient. While outpatient medical treatment is usually required in uncomplicated diverticulitis, more aggressive treatment and often surgery may be necessary for complicated diverticulitis (9).

Surgical procedures to choose from include colectomy with end colostomy or colectomy, anastomosis, and protective ileostomy (10). In our case, we chose the primary repair and drainage procedure after omentopexy. Thus, we saved the patient from a stoma. We did not burden the patient with anastomosis as the abdomen was dirty with a high volume of purulent fluid. Our biggest motivation for this choice was that the patient was young and had no comorbidities.

For many years, diverticulosis was accepted as an elderly disease, with an incidence of just 5% in patients under 50. Recently, the incidence of

diverticulosis has increased in young patients and has been reported to range from 18% to 34% (11). Diverticulitis reportedly has a more aggressive course in younger patients or requires emergency surgery more often than in older patients (12). Leaks after anastomosis can cause morbidity and mortality (13). The primary repair method can prevent this in suitable patients. However, the disease tends to be more aggressive in younger patients and has a high recurrence rate (12). For this reason, if the primary repair method is chosen for a young patient who underwent emergency surgery due to perforation of diverticulitis, the diverticulosis status of the colon should also be evaluated. In the case of extensive diverticulosis, the resection option should also be considered due to the possibility of recurrence.

### Conclusion

Diverticulitis usually presents with abdominal pain in the left lower quadrant of an elderly patient. However, it may present with an acute abdomen by causing intra-abdominal perforation. Although infrequent, diverticulitis perforation should be considered in the differential diagnoses of young patients presenting with an acute abdomen.

### Authors' Contribution

All authors agree to be accountable for all aspects of the work in ensuring that questions related to the accuracy or integrity of any part of the work are appropriately investigated and resolved. All authors contributed to the study conception and design. Material preparation, data collection and analysis were performed by Taygun Gülşen, Serhat Tolga Derici and İlker Sücüllü. The first draft of the manuscript was written by Taygun Gülşen and all authors commented on previous versions of the manuscript. All authors read and approved the final manuscript.

**Conflict of interest:** None declared.

### References

1. Laurell H, Hansson LE, Gunnarsson U. Acute diverticulitis--clinical presentation and differential diagnostics. *Colorectal disease : the official journal of the Association of Coloproctology of Great Britain and Ireland.* 2007;9(6):496-501; discussion -2.
2. Wheat CL, Strate LL. Trends in Hospitalization for Diverticulitis and Diverticular Bleeding in the United States From 2000 to 2010. *Clinical gastroenterology and hepatology : the official clinical practice journal of the American Gastroenterological Association.* 2016;14(1):96-103.e1.
3. Shahedi K, Fuller G, Bolus R, Cohen E, Vu M, Shah R, et al. Long-term risk of acute diverticulitis among patients with incidental diverticulosis found during colonoscopy. *Clinical gastroenterology and hepatology: the official clinical practice journal of the American Gastroenterological Association.* 2013;11(12):1609-13.
4. Bharucha AE, Parthasarathy G, Ditah I, Fletcher JG, Ewelukwa O, Pendlimari R, et al. Temporal Trends in the Incidence and Natural History of Diverticulitis: A Population-Based Study. *The American journal of gastroenterology.* 2015;110(11):1589-96.
5. Mayumi T, Yoshida M, Tazuma S, Furukawa A, Nishii O, Shigematsu K, et al. The Practice Guidelines for Primary Care of Acute Abdomen 2015. *Japanese journal of radiology.* 2016;34(1):80-115.
6. Muhammer Ergenç TKU. Laparoscopic treatment of a rare cause of acute abdomen; primary omental torsion. *Laparosc Endosc Surg Sci.* 2021;28(2):125-7.
7. Ergenç M, Uprak TK. Appendiceal



- Diverticulitis Presenting as Acute Appendicitis and Diagnosed After Appendectomy. *Cureus*. 2022;14(3):e23050.
8. Pautrat K, Bretagnol F, Hutten N, de Calan L. Acute diverticulitis in very young patients: a frequent surgical management. *Diseases of the colon and rectum*. 2007;50(4):472-7.
  9. Swanson SM, Strate LL. Acute Colonic Diverticulitis. *Annals of internal medicine*. 2018;168(9):Itc65-itc80.
  10. Regenbogen SE, Hardiman KM, Hendren S, Morris AM. Surgery for diverticulitis in the 21st century: a systematic review. *JAMA surgery*. 2014;149(3):292-303.
  11. Faria GR, Almeida AB, Moreira H, Pinto-de-Sousa J, Correia-da-Silva P, Pimenta AP. Acute diverticulitis in younger patients: any rationale for a different approach? *World journal of gastroenterology*. 2011;17(2):207-12.
  12. Lahat A, Menachem Y, Avidan B, Yanai H, Sakhnini E, Bardan E, et al. Diverticulitis in the young patient- is it different ? *World journal of gastroenterology*. 2006;12(18):2932-5.
  13. Koo V, Strange J, Lam CY, Epanomeritakis M. Young patients with diverticular disease: a preliminary quality of life study. *International journal of surgery (London, England)*. 2007;5(4):244-9.