

The Use of Inferior Gluteus Perforator (IGAP) Flap Reconstruction for Vaginal Metastasis of Rectal Cancer: A Case Report

Adianto Nugroho^{1*}, PhD Candidate;  Elisabet Kinanthi², MD; Sara Triatmoko³, MD; Indah Jamtani¹, MD

¹Digestive Surgery Division, Department of Surgery, Fatmawati Central General Hospital, Jakarta, Indonesia

²Department of Surgery, Fatmawati Central General Hospital, Jakarta, Indonesia

³Plastic Surgery Division, Department of Surgery, Fatmawati Central General Hospital, Jakarta, Indonesia

*Corresponding author:

Adianto Nugroho,
Digestive Surgery Division, Department of Surgery, Fatmawati Central General
Hospital, Jl. RS Fatmawati Raya 4, Jakarta, Indonesia
Email: adiyusuf97@gmail.com

Received: 10-01-2023

Revised: 04-02-2023

Accepted: 15-02-2023

Abstract

Introduction: Colorectal adenocarcinoma metastasis to the vagina can occur months after the primary tumor resection. Most of the time, bleeding is the main alarming symptom. The optimal treatment involves surgical excision followed by reconstruction to prevent the lymphatic networks in the rectovaginal septum from serving as a potential route of spread. Several successful vaginal reconstruction options have been reported.

Case Presentation: We describe a 32-year-old woman who had previously undergone an abdominoperineal resection for rectal cancer and was now suffering from rectal adenocarcinoma vaginal metastasis. An inferior gluteus perforator flap (IGAP) repair was carried out following posterior vaginectomy after a comprehensive multidisciplinary examination. This flap can address perineal dead space and reconstruct the neovaginal area, eliminating the need for a second flap and significantly reducing donor morbidity. The lesson from this case is that vaginal metastases can still develop even after removing the primary colorectal tumor.

Conclusion: One-step surgical excision and perineal repair can result in an enhanced quality of life and a good prognosis.

Keywords: Colorectal Neoplasms, Vagina, Perforator Flap

Please cite this paper as:

Nugroho A, Kinanthi E, Triatmoko S, Jamtani I. The Use of Inferior Gluteus Perforator (IGAP) Flap Reconstruction for Vaginal Metastasis of Rectal Cancer: A Case Report. *Iran J Colorectal Res.* 2023;11(1):42-45. doi: 10.30476/ACRR.2023.97169.1163.

Introduction

Colorectal cancer can metastasize to various organs, including the vagina. Despite being uncommon, rectosigmoid colon cancers are the direct cause of most vaginal metastases (1). Vaginal bleeding is the most frequent symptom of vaginal metastasis from colorectal cancers. Since resection would eliminate the lymphatic systems in the rectovaginal septum as a potential mode of spread,

infiltrating lesions in the vagina should be treated with posterior vaginectomy (2). Several options for vaginal reconstruction have been reported with good outcomes (3). We present a case of uneventful vaginal metastasis removal and defect closure with an inferior gluteus perforator flap (IGAP).

Case Presentation

A 32-year-old female patient was hospitalized due to

persistent vaginal bleeding. Twelve months before her symptoms, she underwent abdominoperineal resection due to rectal cancer, followed by FOLFIRI chemotherapy. The patient had normal vital signs and was fully awake. The midline scar from the previous surgery was in good condition, and no nodules were seen. The end colostomy on the left abdomen was functional with positive fecal production (Figures 1 and 2).

According to a PET scan, the projection of the vaginal tube had irregular hypermetabolic nodules, indicating metastasis. Hypermetabolic lesions were absent from other organs, including the colon wall and the surgical site. A contrast-enhanced abdominal-pelvic MRI showed a solid mass at the upper two-thirds of the posterior vaginal wall with dimensions of 3.5×3.4×3.6 cm, extending to the iliococcygeal muscle (levator ani muscle). The pathology examination result of the vaginal mass was metastatic rectal adenocarcinoma.

With the patient in the lithotomy position, we performed a posterior vaginectomy, followed by IGAP due to its proximity and flap thickness, which could cover the remaining dead space. The inferior gluteal artery, located at the intersection of the lower and mid 1/3 parts of the line drawn from the posterior superior iliac spine to the ischial tuberosity, appeared to be the most proximal to the vagina and perineal area. Perforator was confirmed using a hand-held Doppler. Distance from the perforator to the furthest defect (fornix area) added 2 cm was marked and illustrated to mark the distance between the perforator to the distal tip of the flap. The pinch test was used to define the maximum width of the flap to ensure primary closure. Incision began on the superior side, beveled to the outside, and cut through the fascia. Sub-fascial dissection was continued using bipolar to avoid bleeding; extra care was taken near the marked perforator. The largest caliber of perforator

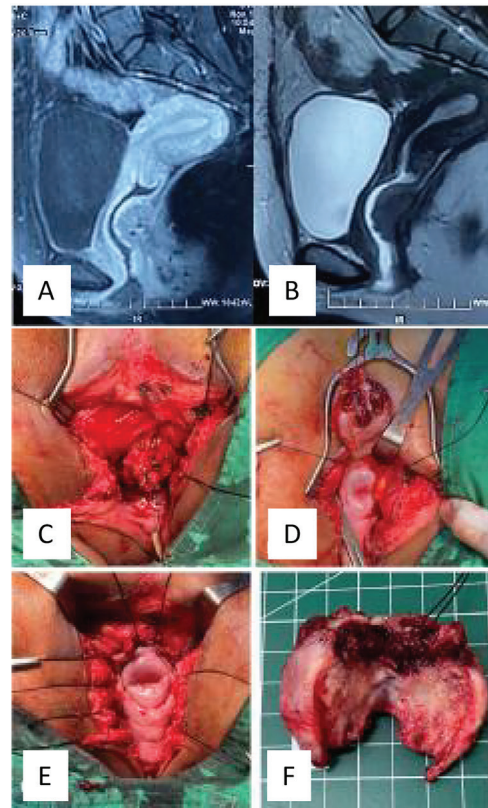


Figure 1: (A,B) Coronal magnetic resonance imaging section showing a metastatic vaginal mass. Posterior vaginectomy: (C) initial step; (D) the mass shown from the superior aspect; (E) post-resection defect; (F) resected specimen.

was chosen, strong pulsation was confirmed with the hand-held Doppler, and the perforator was dissected to the main branch (approximately 3 cm) to achieve a loose pedicle and twisting-free propeller flap. An inferior incision was carried on until the flap was isolated. The flap was then rotated 180 degrees to reach the defect. The secondary defect was then closed primarily. A total of 100 ml of blood was lost throughout the 175-minute operation.

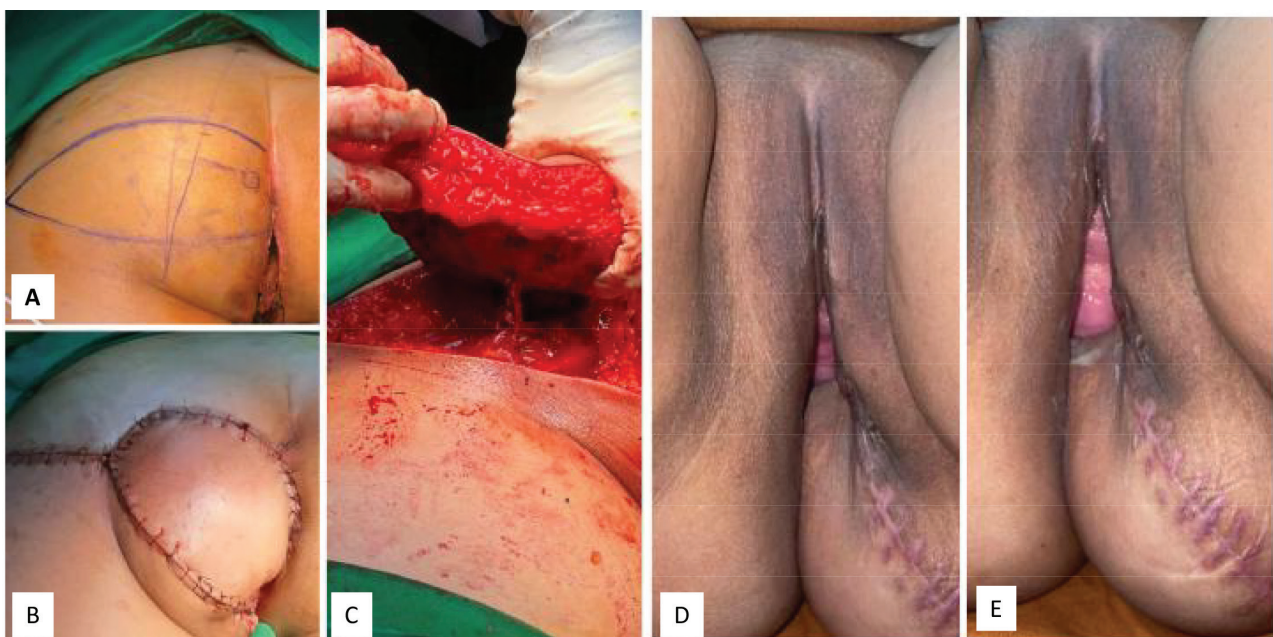

Figure 2: Reconstruction: (A) flap design; (B) final result; (C) raised flap; (D,E) follow-up three months after surgery.

The postoperative process proceeded smoothly. The patient was asked not to put pressure on the flap area for about three weeks. No recurrence was noted at the six-month follow-up. Flap durability, cosmetic outcomes, and sexual function all appeared satisfactory.

Ethics

Written informed consent was obtained from the patients.

Discussion

Colorectal adenocarcinoma metastases can appear in the vagina even after months of primary tumor removal and chemotherapy (1). Our patient had vaginal bleeding, one of the most frequent signs of metastasis (2). Surgical resection was our first choice for managing the vaginal metastasis of colorectal adenocarcinoma. We performed posterior vaginectomy, flap harvesting, and reconstruction in the prone position, maintaining this position for perineal reconstruction.

Sadatomo et al (4). described an isolated vaginal metastasis with primary rectal cancer. Low anterior resection with transvaginal tumor resection was carried out. Although malignancies were in both organs, there was no direct contact between the rectum and vagina intraoperatively. Funada and Fujita (5) described similar cases of tumors in the rectum and vagina with no direct invasion. Following abdominal perineal resection and partial vaginal resection, there was no local recurrence or distant metastases after a year of follow-up.

Our case is comparable to a vaginal metastasis case described by Korkmaz et al. (6). After laparoscopic low anterior resection, the patient was given twelve rounds of adjuvant mFOLFOX-6 treatment. A vaginal lesion was discovered two years later, and the pathology result was colon adenocarcinoma metastasis. After the tumor was removed, twelve cycles of mFOLFOX-6 were administered.

In our case, the perineal defect following posterior vaginectomy was larger than the upper 2/3 circular vaginal tube, with a large hollow space posteriorly. We chose a perforator-based flap for reconstruction from the same region to get a well-vascularized flap that mimics the skin color and thickness with normal tissue around. We decided to use an IGAP flap because of the proximity of the perforator to the defect and the possibility of primary closure for the donor area. Perforators were marked using a hand-held Doppler ultrasound prior to surgery. The largest perforator with a position nearest to the area of defect was chosen. The flap was designed oblique considering the skin-relaxed tension line of the gluteal area. The dimension of the flap was defined by two things: The flap length was devised according to the distance between the perforator and the innermost part of the defect (portio),

while the width was decided by the pinching test, as we wanted to achieve primary closure. The fasciocutaneous flap was harvested with extra care during the dissection surrounding the perforator.

Other common types of flaps are the gluteus maximus flap, rectus abdominis flap, adductor muscles of the thighs, and gracilis flap (7-9). However, several risks must be considered, such as flap necrosis, donor site morbidity, additional duration of surgery, and changes in the patient's position (supine to prone). In most cases, flap reconstruction is the best technique for repairing the perineal skin and filling the defect area. This kind of reconstruction also minimizes the risk of unnecessary total vaginectomy and hysterectomy, which can be devastating for a woman as it leads to a sense of body mutilation, lack of menstruation, and decreased sexual activity. In our study, the flap was vital, durable, and aesthetically satisfying after one week. The patient was released from the hospital after we ensured the flap was vital. After six months, the patient expressed satisfaction with the flap result, especially in terms of aesthetic value.

Achauer et al (10). documented several pedicled flaps for perineal reconstructions. The majority of the techniques used involved the posterior gluteal myocutaneous thigh flap, bilateral posterior thigh flap, and inferior gluteal thigh flap, with varying degrees of success. Using an IGAP flap for the posterior wall of the vagina and a superior gluteal artery perforator (SGAP) flap for posterior perineal skin defect, Albano et al. (11) described a case of delayed wound closure following abdominoperineal resection. Necrosis of the IGAP flap and a portion of the SGAP flap were found during follow-up. After an extralevator abdominoperineal excision, Chasapi et al (7). used a pedicled flap with an internal pudendal artery for defect reconstruction. There were no instances of flap loss in the mean 14 months of follow-up, and the final aesthetic result was excellent.

In our case, surgical excision for the vaginal metastases by posterior vaginectomy was suitable because the main tumor had previously been excised. The IGAP flap can be considered an alternative vaginal and perineal reconstruction treatment that produces functional defect closure and acceptable aesthetic results. The prone jackknife position could be used for both procedures in a single-operation setting. Both tumor removal and reconstruction required a multidisciplinary team and effective workgroup communications.

Conclusion

In conclusion, even after the primary colorectal tumor is removed, vaginal metastases can still develop. With surgical excision and reconstruction of vaginal and perineal tissues, a favorable prognosis,

acceptable aesthetic results, and improved quality of life, including sexual function, can be attained.

Authors' Contribution

All authors have contributed to this manuscript and reviewed and approved the final form of the

manuscript. All authors agree to be accountable for all aspects of the work in ensuring that questions related to the accuracy or integrity of any part of the work are appropriately investigated and resolved.

Conflict of interest: None declared.

References

1. Ng HJ, Aly EH. Vaginal metastases from colorectal cancer. *International journal of surgery (London, England)*. 2013;11(10):1048-55.
2. Green JD, Evans JT, Ger R. Posterior vaginectomy as a practice parameter in rectal carcinoma. *Diseases of the colon and rectum*. 1994;37(5):513-4.
3. Angeles MA, Martínez-Gómez C, Martínez A, Meresse T, Gangloff D, Ferron G. Vaginal reconstruction after pelvic exenteration with a vertical deep inferior epigastric perforator flap in 10 steps. *International journal of gynecological cancer : official journal of the International Gynecological Cancer Society*. 2020;30(12):2015-6.
4. Sadatomo A, Koinuma K, Horie H, Lefor AK, Sata N. An isolated vaginal metastasis from rectal cancer. *Annals of medicine and surgery (2012)*. 2016;5:19-22.
5. Funada T, Fujita S. A case of vaginal metastasis from a rectal cancer. *Japanese journal of clinical oncology*. 2010;40(5):482.
6. Korkmaz M, Eryılmaz MK, Kerimoğlu Ü, Karaağaç M, Demirkıran A, Demir ET, et al. Vaginal metastasis in solid tumours: our four cases and review of the literature. *Journal of the Egyptian National Cancer Institute*. 2021;33(1):3.
7. Chasapi M, Maher M, Mitchell P, Dalal M. The Perineal Turnover Perforator Flap: A New and Simple Technique for Perineal Reconstruction After Extralevator Abdominoperineal Excision. *Annals of plastic surgery*. 2018;80(4):395-9.
8. Brodbeck R, Horch RE, Arkudas A, Beier JP. Plastic and Reconstructive Surgery in the Treatment of Oncological Perineal and Genital Defects. *Frontiers in oncology*. 2015;5:212.
9. Cordeiro PG, Pusic AL, Disa JJ. A classification system and reconstructive algorithm for acquired vaginal defects. *Plastic and reconstructive surgery*. 2002;110(4):1058-65.
10. Achauer BM, Braly P, Berman ML, DiSaia PJ. Immediate vaginal reconstruction following resection for malignancy using the gluteal thigh flap. *Gynecologic oncology*. 1984;19(1):79-89.
11. Nico Albano M, Louro JM, Brito I, Ramos S. Perineal reconstruction using an inferior gluteal artery perforator flap after abdominoperineal resection. *BMJ case reports*. 2019;12(9).