

## An Interesting Case of a Rare, Isolated, Non-communicating Enteric Duplication Cyst

Azharuddin<sup>1</sup>, MS;  Mohd Salman Khan<sup>1</sup>, MS; Shyamendra Pratap Sharma<sup>1</sup>, MCh; Singh Sandesh Bharat<sup>1</sup>, MCh 

<sup>1</sup>Department of General Surgery, Maya Institute of Medical Sciences (MIMS), Barabanki, India

### \*Corresponding authors:

Singh Sandesh Bharat,  
Department of General Surgery, M.I.M.S, Barabanki, India. Tel: +91 6296209358  
Email: dr.sndsh@gmail.com

Received: 06-08-2022

Revised: 29-09-2022

Accepted: 29-09-2022

### Abstract

**Introduction:** A very uncommon type of gastrointestinal duplication known as a completely isolated duplication cyst lacks communication with the rest of the normal intestine segment and has its own blood supply. Here, we present a case of an adult male with a non-communicating ileal duplication cyst.

**Case Presentation:** A 40-year-old male was admitted to our hospital with the chief complaint of lower abdominal pain, distension, and a palpable mass that had been more evident within the last month. On physical examination, there was tenderness and a semi-mobile mass in the right lower abdomen. On abdominal contrast-enhanced computed tomography, a large cystic mass lesion measuring approximately 22.9×13.4 cm (average HU=18) with multiple enhancing septae was seen on the right side of the abdomen. Without altering the normal bowel or mesenteric anatomy, the entire cyst was removed. The patient was monitored after the procedure and showed no signs of any postoperative problems.

**Conclusion:** When determining a differential diagnosis for abdominal cystic lesions, duplication cysts should be considered. As shown in our example, the resection of completely isolated duplication cysts can be safely performed without the need for intestinal resection.

**Keywords:** Small intestine, Congenital abnormalities, Cyst

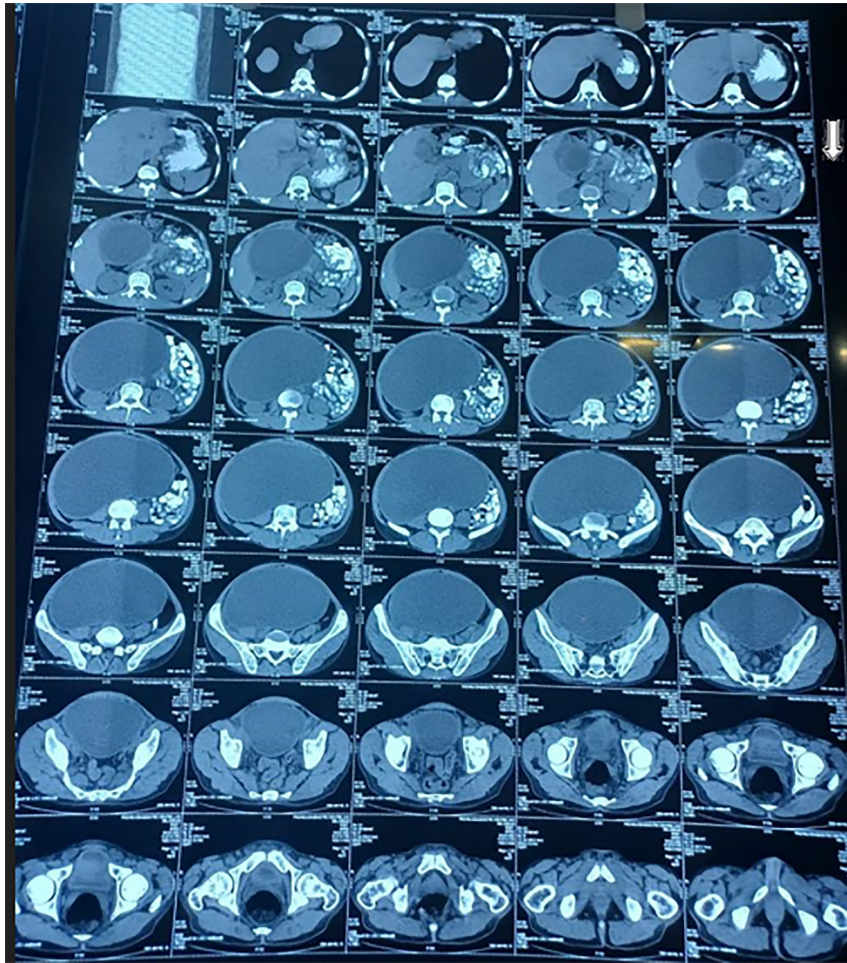Please cite this paper as:

Azharuddin, Khan MS, Sharma SP, Sandesh Bharat S. An Interesting Case of a Rare, Isolated, Non-communicating Enteric Duplication Cyst. *Iran J Colorectal Res.* 2022;10(3):115-118. doi: 10.30476/ACRR.2023.97439.1162.

### Introduction

Rare congenital anomalies called enteric duplication cysts can develop anywhere along the gastrointestinal tract, from the tongue to the anus. The ileum is the most typical site for a small bowel duplication cyst, which is the most prevalent kind of enteric duplication cyst (1, 2). Women have a two-fold higher prevalence of duplication cysts than men, and there is no evidence of family aggregation (3).

Due to the symptomatology of duplication cysts in young children, diagnosis is made in more than half of cases during this period. On the other hand, during adulthood, these cysts are typically asymptomatic, and the diagnosis is usually accidental. In about half of the cases, additional anomalies accompany duplication cysts, typically found in the esophagus and vertebrae. Duplication cysts are linked with complications like hemorrhage, fistulization, and potentially malignant degeneration (4).



**Figure 1:** Computed tomography images of the abdomen show a large cystic mass lesion measuring approximately 22.9×13.4 cm (average HU=18) with multiple enhancing septae on the right side of the abdomen.

A very uncommon type of gastrointestinal duplication known as a completely isolated duplication cyst lacks communication with the rest of the normal intestine segment and has its own blood supply (5-7). Here, we present the case of an adult male with a non-communicating ileal duplication cyst.

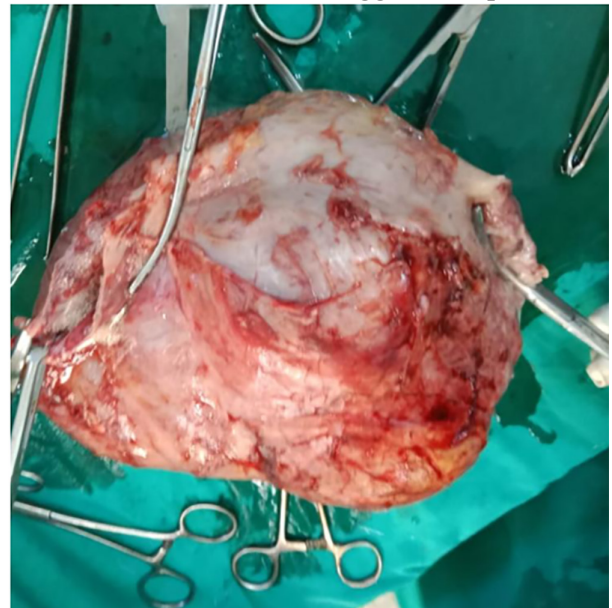
### Case Report

A 40-year-old male was admitted to our hospital with a chief complaint of lower abdominal pain, distention, and a palpable mass that had been more evident within the last month. On physical examination, there was tenderness and a semi-mobile mass in the right lower abdomen.

On abdominal contrast-enhanced computed tomography (Figure 1), a large cystic mass lesion measuring approximately 22.9×13.4 cm (average HU=18) with multiple enhancing septae was seen on the right side of the abdomen. The lesion caused a mass effect in the form of posterior displacement of small and large bowel loops. Anteriorly, the lesion closely abutted the abdominal wall muscles, resulting in outward bulging; however, there was no evidence of infiltration of the subcutaneous plane. Posteriorly, the lesion closely abutted the rectum with loss of the perirectal fat pad but no evidence of intraluminal

extension. Laterally, the lesion reached up to bilateral iliac blades. However, fat planes were well maintained. The lesion closely abutted the common, internal, and external iliac vessels bilaterally, with loss of planes at places but no evidence of luminal compromise or thrombosis.

The mentioned features suggested a peritoneal



**Figure 2:** Gross appearance of the excised specimen



inclusion cyst. Without altering the normal bowel or mesenteric anatomy, the entire cyst was removed. The ileal and cystic lumens had no link to one another. Grossly (Figure 2), the mucosal layer was intact after the cyst was removed, although there was a tiny defect in the serosal layer. An intestinal duplication cyst was discovered after the tissue underwent a histopathologic evaluation. The patient was monitored after the procedure and showed no signs of postoperative problems.

## Discussion

Wendel originally characterized duplication cysts in 1911; since then, only a small number of cases have been documented (3). Basically linked to the wall of the digestive system (sometimes sharing the serosa), enteric duplication cysts are hollow, epithelium-lined, cystic, spherical, or tubular structures that receive their blood supply from shared mesenteric blood arteries (7). Removing the neighboring bowel segment together with the duplication cyst is necessary because enteric duplication cysts typically share a similar wall and blood supply with the normal intestine (5, 7). In our situation, the isolated duplication cyst was isolated from the surrounding alimentary segments, had a separate vascular pedicle, and rested on the mesentery. Within the first year of life, intestinal blockage or a palpable mass is typically present together with intestinal duplication symptoms. Similar symptoms can occur in adults, and acute presentations have been linked to ulcer-related bleeding or a malignant change within the duplication (4, 8). Adenocarcinoma in adults can develop from unnoticed, asymptomatic cysts. Malrotation and the intestinal duplication cyst can coexist (7). There are accompanying deformities in 50% of instances, with esophageal duplications being the most common, followed by vertebral abnormalities (3). In our situation, there was no malrotation or deformities such as esophageal duplications or spinal abnormalities.

Duplication cysts are difficult to identify and

are poorly characterized by imaging techniques like computed tomography (CT) and magnetic resonance imaging. However, according to recent studies, endoscopic ultrasonography (EUS), which has greater accuracy rates than conventional imaging methods, may be crucial in diagnosing this illness (3). Duplication cysts' cystic nature may be confirmed by CT scanning and ultrasound. An echogenic mass caused by bleeding with inspissated material within the duplication is visible on ultrasound as a hypoechoic mass with strong posterior wall echoes and good through transmission. In our instance, the cyst contained a clear fluid. The diagnosis of a duplication cyst can be made if the usual inner echogenic mucosal and outer hypoechoic muscle layers are visible on ultrasonography (4, 9). On a CT scan, duplication cysts can be identified as fluid-filled, smoothly rounded cysts or as tubular entities with thin, slightly enhancing walls in or near the wall of a portion of the gastrointestinal system (4). In our case, a small intestinal duplication cyst was tentatively identified based on CT and sonographic features. However, all cystic intraabdominal masses, including mesenteric and omental cysts, pancreatic pseudocysts, and ovarian cysts(4, 8), should be included in the differential diagnosis.

There is no consensus on the treatment plan for duplication cysts. While surgery is advised for symptomatic or complicated cases, there is no agreement on the standard care of asymptomatic cases (3). In our situation, the patient underwent surgical excision for a symptomatic duplication cyst.

## Conclusion

When determining a differential diagnosis for abdominal cystic lesions, duplication cysts should be considered. As shown in our example, the resection of completely isolated duplication cysts can be safely performed without needing intestinal resection.

**Conflict of interest:** None declared.

## References

1. Kim YJ, Kim YK, Jeong YJ, Moon WS, Gwak HJ. Ileal duplication cyst: Y-configuration on in vivo sonography. *Journal of pediatric surgery*. 2009;44(7):1462-4.
2. Cheng G, Soboleski D, Daneman A, Poenaru D, Hurlbut D. Sonographic pitfalls in the diagnosis of enteric duplication cysts. *AJR American journal of roentgenology*. 2005;184(2):521-5.
3. Seijo Ríos S, Lariño Noia J, Abdulkader Nallib I, Lozano León A, Vieites Pérez-Quintela B, Iglesias García J, et al. [Adult gastric duplication cyst: diagnosis by endoscopic ultrasound-guided fine-needle aspiration (EUS-FNA)]. *Revista española de enfermedades digestivas : organo oficial de la Sociedad Española de Patología Digestiva*. 2008;100(9):586-90.
4. Kim SK, Lim HK, Lee SJ, Park CK. Completely isolated enteric duplication cyst: case report. *Abdominal imaging*. 2003;28(1):12-4.
5. Sinha A, Ojha S, Sarin YK. Completely isolated, noncontiguous duplication cyst. *European journal of pediatric surgery : official journal of pediatric surgery* : official journal of Austrian Association of Pediatric Surgery [et al] = *Zeitschrift für Kinderchirurgie*. 2006;16(2):127-9.
6. Lund DP, Grosfeld JL, JAON, E. W. Fonkalsrud, A. G. Coran E. "Alimentary tract duplications," in *Pediatric Surgery In: Mosby SL, Mo, editor. 6th ed 2006. p. 1389-98.*
7. Srivastava P, Gangopadhyay AN, Kumar V, Upadhyaya VD, Sharma SP, Jaiman R, et al. Noncommunicating isolated enteric duplication cyst in childhood. *Journal of pediatric surgery*. 2009;44(7):e9-e10.
8. Macpherson RI. Gastrointestinal

tract duplications: clinical, pathologic, etiologic, and radiologic considerations. Radiographics : a review publication of the Radiological

Society of North America, Inc. 1993;13(5):1063-80.

9. Kangaroo H, Sample WF, Hansen G, Robinson JS, Sarti

D. Ultrasonic evaluation of abdominal gastrointestinal tract duplication in children. Radiology. 1979;131(1):191-4.