

Rectal Arteriovenous Malformation: A Report of Two Cases, Review of Literature, and Management Algorithm

Somanath Malage¹, MD; Ashok Kumar^{1*}, MD; Rajan Saxena¹, MD; Ram Nawal Rao², MD

¹Departments of Surgical Gastroenterology, Sanjay Gandhi Post Graduate Institute of Medical Sciences, Lucknow, India

²Departments of Pathology, Sanjay Gandhi Post Graduate Institute of Medical Sciences, Lucknow, India

*Corresponding authors:

Ashok Kumar,
Department of Surgical Gastroenterology, SGPGIMS, Lucknow-226014, India
Tel: +94 15578278
Email: doc.ashokgupta@gmail.com

Received: 14-07-2022

Revised: 26-08-2022

Accepted: 26-08-2022

Abstract

Background: Diffuse cavernous hemangioma of the rectum (DCHR) is very rare. Despite the many diagnostic modalities available, achieving a correct diagnosis is difficult. Management of these cases has evolved over the years; still, it poses a challenge because of the nature of the disease and extent of involvement. Herein we present two cases of rectal arteriovenous malformation (AVM) managed surgically. We also review the literature and propose a management algorithm for rectal AVM.

Case Presentation: Two young patients presented with recurrent intermittent bleeding per rectum. One of them was misdiagnosed with a rectal polyp and underwent polypectomy without success elsewhere prior to referral to our hospital. The other patient presented with a history of recurrent bleeding since childhood. Patients were evaluated with colonoscopy, contrast-enhanced computed tomography, and magnetic resonance imaging as diagnostic tools and also for localization. DCHR was noted in both patients, extending from the dentate line up to the rectosigmoid in one patient and to the mid-sigmoid colon in the other. After preparation, both of them were taken up for surgery. Ultra-low anterior resection with stapled coloanal anastomosis was performed in both. One of them had an uneventful postoperative recovery; the other developed a presacral abscess with spontaneous per rectal drainage.

Conclusion: DCHR can be successfully managed surgically without sacrificing the anal canal, avoiding a permanent stoma. A management algorithm was proposed.

Keywords: Rectal arteriovenous malformation, Evaluation, Surgical management

Please cite this paper as:

Malage S, Kumar A, Saxena R, Rao RN. Rectal Arteriovenous Malformation: A Report of Two Cases, Review of Literature, and Management Algorithm. *Iran J Colorectal Res.* 2022;10(3):103-109. doi: 10.30476/ACRR.2022.94515.1150.

Introduction

Diffuse cavernous hemangioma of the rectum (DCHR) is a rare entity with different presentations ranging from episodic intermittent bleeding to massive lower gastrointestinal bleeding,

mainly affecting children and young adults. Diffuse cavernous hemangioma is most commonly seen in the rectosigmoid region and tends to involve adjacent structures (1). Symptoms usually begin at an early age with intermittent painless rectal bleeding, sometimes associated with systemic syndromes like Bean's

syndrome and Klippel-Trenaunay syndrome (KTS) (2, 3). As the symptoms are nonspecific, they are commonly misdiagnosed and treated as hemorrhoids (4). Management options include sclerotherapy, endoscopic resection, transarterial embolization (TAE), and surgical procedures. However, there are no large-volume studies to prove the efficacy of one treatment over the other. We herein report two cases of DCHR and review the literature, emphasizing disease management.

Case 1

A 23-year-old male with no known comorbidities presented with intermittent bleeding per rectum since age five. Initially, the bleeding was in small quantity (8-10 drops/day) and infrequent. The frequency and amount of bleeding had increased in the past two years. There was no history of hematemesis, bleeding diathesis, or underlying liver disease.

Blood investigation revealed hemoglobin of 10.4 g/dl, total leukocyte count of 3,400/ μ l, and platelets of 1.8 lakhs/ mm^3 . Liver and renal functions were within normal limits. A digital rectal examination revealed no mass. Proctoscopy showed a circumferential bluish-red lesion within the mucosa in the lower third of the rectum, which bled on contact.

A full colonoscopy revealed reddish purple rectal mucosa starting from the anal canal and extending proximally up to 24 cm over the entire circumference, with dilated vessels at the proximal end (Figure 1).

A triple-phase computed tomography (CT) scan showed circumferential diffuse long segment wall thickening of the rectum and sigmoid colon, progressive enhancement of the bowel mucosa in the portal venous phase, and thickening starting 2 cm above the anal verge and extending for a length of 21 cm. The affected part of the rectum and sigmoid colon had feeding vessels from the superior rectal artery. Additionally, there was a 1x1 cm hemangioma in segment 6 of the liver.

Surgery

With the diagnosis of arteriovenous malformation (AVM) of the rectum and sigmoid colon, the patient was taken up for surgical resection. At surgery, there

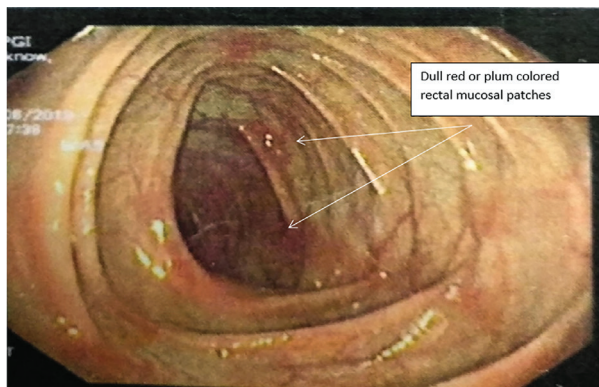


Figure 1: Colonoscopic image of AVM - dull red mucosal lesions.

was diffuse vascular malformation extending from 1 cm above the dentate line to the mid-sigmoid colon with involvement of the mesorectum. A 6x6 cm hemangioma was also noted at the dome of the urinary bladder (Figure 2). There was no evidence of chronic liver disease (CLD) or portal hypertension. The patient underwent ultra-low anterior resection with stapled coloanal anastomosis and a covering loop ileostomy. The hemangioma of the bladder was not resected as the patient was asymptomatic. Postoperative recovery was uneventful.

Histopathology was consistent with AVM (Figure 3). Sections from proximal and distal doughnut margins also showed focal areas of irregular, variable-sized, thin and thick-walled blood vessels in the adventitia. The ileostomy was closed four months after primary surgery, and the patient remains asymptomatic after 24 months.

Case 2

A sixteen-year-old male complained of painless, intermittent small bleeding (5-10 ml/day) per rectum since childhood (from the age of three months) at an interval of 15 days to 1 month with episodes of anemia. He was initially diagnosed with rectal polyp and had undergone polypectomy and later argon plasma coagulation (APC) for recurrent bleeding before being referred to our hospital.

At presentation to our hospital, he was anemic. His blood investigation revealed a hemoglobin of 3.6 g/dl, a platelet count of 1.8 lakh/ mm^3 , and a total leukocyte count of 5,300/ μ l. Barium enema was suggestive of a sessile plaque-like lesion in the posterior wall of the rectum. A colonoscopy revealed a circumferential mass lesion with multiple hemorrhagic spots and friability at the rectosigmoid region extending proximally for a length of up to 8 cm. Rest of the colon was normal. The biopsy was inconclusive. Endorectal coil magnetic resonance imaging (MRI) showed features of vascular malformation starting from the anorectal junction to the rectosigmoid.

Surgery

He underwent ultra-low anterior resection and

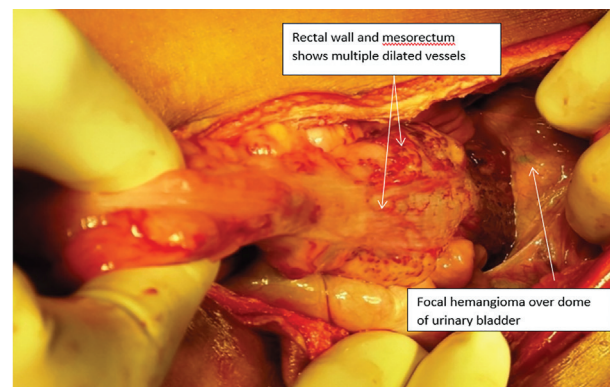


Figure 2: Intraoperative images – rectum and sigmoid colon thickened with multiple dilated vessels along with hemangioma over dome of urinary bladder.

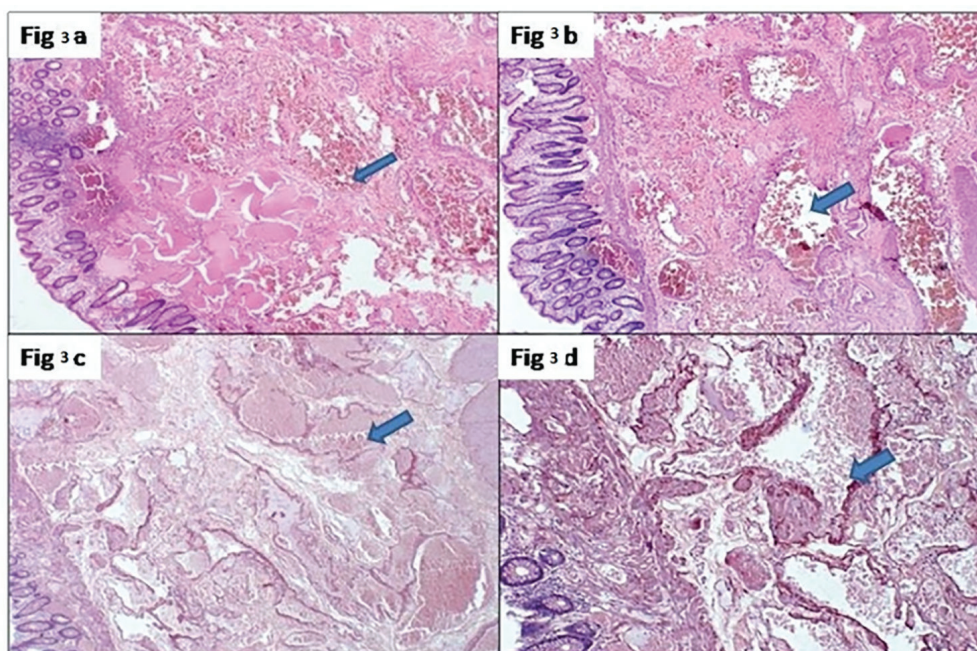


Figure 3: a, b) Sections from rectum and sigmoid colon shows bit of colonic mucosa and maintained architecture. submucosa shows irregular variable sized thick and thin walled blood vessels lined by endothelial cells with areas of congestion and haemorrhage (blue arrow). c, d) orcin staining the arteriovenous malformation (blue arrow).

coloanal anastomosis with a covering loop ileostomy. Intraoperatively, the entire rectal wall was thickened, and engorged blood vessels were visible on the subserosal aspect, extending into adjacent perirectal fat. The hemangioma extended from the dentate line to the rectosigmoid junction, involving the seminal vesicles and prostate. On the cut section, multiple nodular mucosal elevations were seen in the rectum, with bunches of enlarged blood vessels involving the full thickness of the rectum and extending into the adjacent perirectal fat.

On histopathological examination, there were multiple irregularly dilated and congested vascular channels and arterialized veins with irregularly thickened walls and fragmented elastic lamina seen in the submucosa, extending into the muscularis as well as the mesorectum. The rectal and colonic margins showed similar changes. The patient had a presacral abscess postoperatively with spontaneous discharge per anum but later required incision and drainage under anesthesia, after which he recovered. The ileostomy was reversed five months later. Four years later, the patient was diagnosed with chronic myeloid leukemia and was treated with chemotherapy. Five years later, the patient had recurrent episodes of bleeding per rectum. A deep posterior ulcer with bleeding vessels was found in the anal canal on proctoscopy. Suture ligation of the bleeder was done, and APC was later performed for bleeding from the ulcerated mucosa. Later, the patient was found to be HBsAg and HCV positive and developed right-sided hydronephrosis requiring double J stenting.

Informed consent was obtained from both patients for publishing this paper with de-identified data.

Discussion

The most common site of diffuse cavernous hemangioma of the gastrointestinal tract is the rectosigmoid (5). Bleeding in AVMs is secondary to thin-walled vascular channels, increased smooth muscle fibers, and an inherited lack of elastic tissue with thrombus and fibrinoid necrosis within the capillaries (6). Hemangiomas of the colon and rectum can involve intestinal mesentery and retroperitoneum and can infiltrate the surrounding organs like the uterus and urinary bladder (7).

The most commonly utilized diagnostic modalities in this era are colonoscopy, CT, MRI, and angiography. On colonoscopy, rectal AVM appears as multiple bluish-purple submucosal masses, which helps assess the lesion's proximal extent and the presence or absence of other synchronous lesions in the proximal bowel (8). The drawback of colonoscopy is its low diagnostic and therapeutic utility in acute severe bleeding in an emergency—a situation where radiological imaging is advantageous as it is less time-consuming, needs no colon preparation, and can also deliver therapy by embolization (9). CT angiography is a rapid procedure that identifies the source of bleeding and also aids in choosing the appropriate therapeutic procedure, which may be therapeutic fluoroscopic angiography with embolization or surgical resection (10). CT angiography can detect extravasation at a rate of 0.3–0.5 ml/min, which is more sensitive than fluoroscopic angiography. Multiphase CT enterography and MRI can be used for diagnosis on an outpatient basis (11).

Small, asymptomatic, and non-progressive hemangiomas can be observed with follow-up every

Table 1: Published cases on rectal arteriovenous malformations: presenting symptoms and management options

Study series	Age (years) / sex	Symptoms	Segment of bowel involved / diagnostic modalities used	Management
P. J. Jeffery et al. 1976 ¹⁴	18-31 years / 10 patients: 6 males, 4 females	Intermittent rectal bleed	Rectum, sigmoid colon / sigmoidoscopy, colonoscopy	Coloanal sleeve anastomosis (mucosectomy done)
Candace L. Wilson et al. 2001 ⁹	19 years / male	Intermittent bleeding	Rectosigmoid (KTS syndrome) / barium enema, CT of abdomen+pelvis, visceral angiography	APR (extensive perianal vascular malformations, so anastomosis was not done)
	38 years / male	Intermittent bleeding	Rectum / sigmoidoscopy, angiogram, CT	LAR, mucosal proctectomy, and coloanal anastomosis (handsewn)
	20 years / female	Intermittent bleeding	Sigmoid, rectum, up to anal verge (KTS syndrome) / visceral angiogram, MRI of pelvis and extremity	Ultra-LAR, mucosectomy, coloanal anastomosis (handsewn)
Patricia Sylla et al. 2008 ¹⁸	23 years / male	Recurrent rectal bleeding	Rectum, sigmoid colon / proctosigmoidoscopy, CT of abdomen & pelvis	Resection of rectosigmoid and coloanal anastomosis
	38 years / male	Recurrent rectal bleeding	Arteriovenous hemangioma / sigmoidoscopy, CT	Very low LAR with coloanal anastomosis
Nicolas Rotholtz et al. 2009 ¹⁵	25 years / male	Intermittent bleeding	Distal sigmoid to the anal canal (KTS syndrome) / colonoscopy, MRI of pelvis, visceral angiography	Laparoscopic ultra-LAR + handsewn colopouch anal anastomosis
Han Tao Wang et al. 2010 ¹⁴	16-51 years / 17 patients: 12 males, 5 females	Intermittent bleeding	Rectum / colonoscopy, CT, MRI, angiography	2 APR, 1 transverse colostomy, 1 Hartmann's procedure, 6 coloanal sleeve anastomosis, 7 pull-through transection and coloanal anastomosis
Hiroyuki Fujikawa et al. 2014 ¹⁹	52 years / female	Intermittent rectal bleeding	Rectum and sigmoid colon (KTS syndrome) / colonoscopy, angiography, Doppler transrectal USG	Anterior resection and coloanal anastomosis (mucosectomy done)
Our series	23-year-old male 16-year-old male	Intermittent rectal bleeding	Rectum and sigmoid colon / colonoscopy, MRI, CT	Ultra-LAR (stapled anastomosis)

APR: Abdominoperineal resection; CT: Computed tomography; KTS: Klippel-Trenaunay syndrome; LAR: Low anterior resection; MRI: Magnetic resonance imaging; USG: Ultrasonography

6-12 months, with therapeutic interventions being reserved for patients with progressively increasing lesions becoming symptomatic in the form of cardiac failure, bleeding per rectum, or genitourinary bleeding because of involvement of pelvic organs (12).

Treatment options for DCHR include minimally invasive sclerotherapy, mesenteric ligation, local excision, and abdominoperineal resection (APR). Mesenteric ligation and local excision are considered suboptimal therapeutic modalities as DCHR involves all the rectal wall layers, rendering it difficult to treat with such procedures. Complete resection of the lesion has been claimed as the only treatment that controls bleeding (13). As diffuse rectal AVMs mostly originate from the dentate line, it is challenging to perform a complete excision.

Multiple procedures described in the literature include modified Parks coloanal pull-up, coloanal sleeve anastomosis, proctosigmoidectomy with coloanal anastomosis, and APR. There are reports of total proctocolectomy with ileal pouch-anal anastomosis for patients with diffuse colon and rectum involvement (14). APR carries low morbidity

and mortality, but permanent colostomy is usually not acceptable to a young patient with a benign disease.

Jeffery et al., in 1976, proposed coloanal sleeve anastomosis as the procedure of choice for diffuse rectal AVM. In this procedure, the upper part of the rectum and sigmoid colon are resected, leaving behind the distal 10 cm of the rectal muscular cuff after stripping the mucosa and submucosa (15). The disadvantages are that it is a difficult procedure and does not completely eradicate the lesion, leaving the possibility of the remnant lesion invading the inner colon with a recurrence of symptoms (16).

Since 1986, low anterior resection (LAR) has been performed for diffuse rectal AVM, made possible with expertise and advanced stapling techniques. But as the lesion originates from the dentate line, LAR does not achieve complete resection in all cases. Han Tao Wang et al. performed pull-through transection and coloanal anastomosis in 13 out of 17 patients with diffuse rectal AVM. They observed better outcomes than coloanal sleeve anastomosis in terms of decreased blood loss, operative time, and blood transfusion requirement. In the pull-

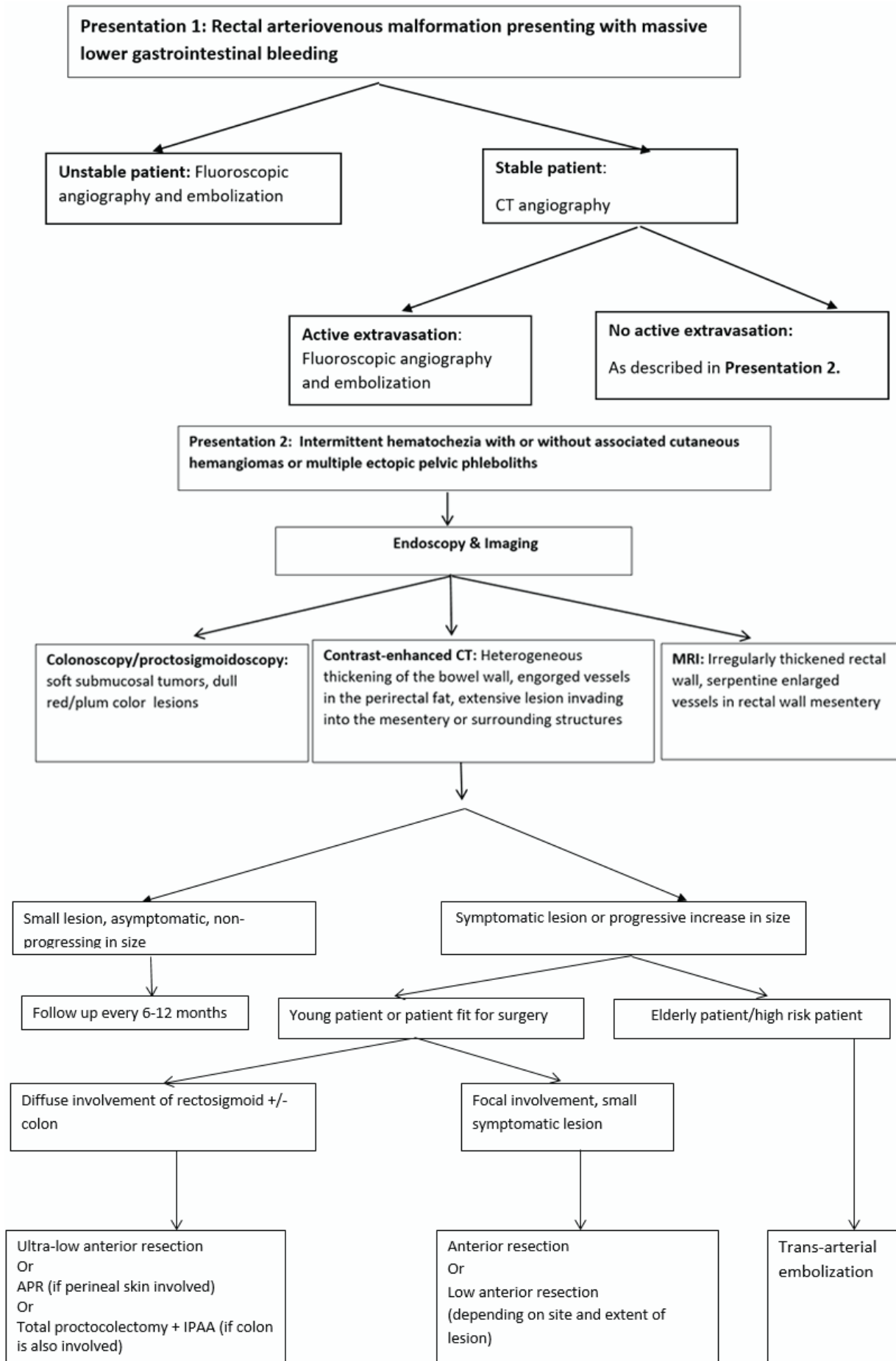


Figure 4: Proposed algorithm for managing rectal arteriovenous malformations. APR: Abdominoperineal resection; CT: Computed tomography; IPAA: Ileal pouch-anal anastomosis; MRI: Magnetic resonance imaging

through transection procedure, the rectum is dissected further distally between the internal and external anal sphincters. The division is done at the level of the dentate line with stapled coloanal anastomosis (16).

Ultra-low anterior resection for rectal AVM was first performed by Rotholtz et al. laparoscopically with handsewn anastomosis and good postoperative functional outcomes (3, 17, 18). Rectal AVMs are difficult to treat because of their extent; with modern stapling devices, rectal anastomosis can be performed even in low rectal lesions.

Both of our patients had lesions starting from the dentate line. Ultra-low anterior resection with stapled coloanal anastomosis is a suitable surgical option with good outcomes, although there is a possibility of leaving part of the lesion just above the dentate line. But as the vascular supply of the lesion is disrupted completely, the chances of bleeding per rectum are low, with a good functional outcome, as seen in one of our cases. The other case had intraoperative difficulty because of seminal vesicles and prostate involvement and was complicated in the postoperative period by perirectal abscess, which was managed by drainage. With the advent of modern staplers, it is now possible to perform ultra-low resections and avoid APR for a benign disease in young patients.

Recently, transarterial embolization (TAE) has gained significance because it avoids invasive surgery and can be repeated when there is a recurrence (19). TAE alone can help control symptoms for a

brief period but is subsequently associated with neovascularization and recanalization, fairly commonly leading to relapse of symptoms. TAE has also been used commonly in older patients who present with massive bleeding and are not fit for surgery, with a high recurrence rate.

The presentation and management of AVM have varied in different series (Table 1). Based on the literature and our experience, we propose an algorithm for managing rectal AVM in Figure 4.

Conclusion

Rectal or rectosigmoid AVM can present with small and recurrent bleeding with or without anemia. Diagnosis may be fallacious at times. A careful history, clinical examination, and typical endoscopy findings help arrive at the correct diagnosis. CT angiography is advisable before planning treatment. Ultra-low resection is a good surgical option with acceptable outcomes.

Authors' Contribution

Somanath malage- data analysis & collection, manuscript writing. Ashok kumar- project development, data analysis, manuscript writing. Rajan Saxena- project development, data analysis, manuscript writing. Ram Nawal Rao- data analysis & collection

Conflicts of interest: None declared.

References

1. Yorozyua K, Watanabe M, Hasegawa H, Baba H, Imai Y, Mukai M, et al. Diffuse cavernous hemangioma of the rectum: report of a case. *Surgery today*. 2003;33(4):309-11.
2. Kaiser AM, Spanos C. An unusual cause of rectal bleeding. *The British journal of radiology*. 2005;78(928):373-5.
3. Sylla P, Deutsch G, Luo J, Recavarren C, Kim S, Heimann TM, et al. Cavernous, arteriovenous, and mixed hemangioma-lymphangioma of the rectosigmoid: rare causes of rectal bleeding--case series and review of the literature. *International journal of colorectal disease*. 2008;23(7):653-8.
4. Komekani Y, Konishi F, Makita K, Mijin T, Onogawa A, Chochi T, et al. Rectal arterio-venous malformation (AVM) with bleeding of an internal hemorrhoid. *Clinical journal of gastroenterology*. 2016;9(1):22-6.
5. Wang HT, Tu Y, Fu CG, Meng RG, Cui L, Xu HL, et al. Diffuse cavernous hemangioma of the rectosigmoid colon. *Techniques in coloproctology*. 2005;9(2):145-8.
6. Maddah G, Abdollahi A, Rouhbakhshfar O, Taraz Jamshidi S, Hassanpour M. Arteriovenous malformations of the colon: A report of two cases and review of the literature. *Caspian journal of internal medicine*. 2017;8(1):52-5.
7. Topalak O, Gönen C, Obuz F, Seçil M. Diffuse cavernous hemangioma of the rectosigmoid colon with extraintestinal involvement. *The Turkish journal of gastroenterology: the official journal of Turkish Society of Gastroenterology*. 2006;17(4):308-12.
8. Kandpal H, Sharma R, Srivastava DN, Sahni P, Vashisht S. Diffuse cavernous haemangioma of colon: magnetic resonance imaging features. Report of two cases. *Australasian radiology*. 2007;51 Spec No.:B147-51.
9. Parthasarathy M, Basu A, Omer AR. Massive per rectal bleeding in a child due to caecal arteriovenous malformation treated successfully by embolisation. *BMJ case reports*. 2013;2013.
10. Wilson CL, Song LM, Chua H, Ferrara M, Devine RM, Dozois RR, et al. Bleeding from cavernous angiomatosis of the rectum in Klippel-Trenaunay syndrome: report of three cases and literature review. *The American journal of gastroenterology*. 2001;96(9):2783-8.
11. Cotzias E, Rehman SF, Arsalani Zadeh R, Smith D. Conservative management of diffuse cavernous haemangioma of the sigmoid and rectum. *Annals of the Royal College of Surgeons of England*. 2020;102(1):e1-e3.
12. Singland JD, Penna C, Parc R. [Colorectal cavernous hemangiomatosis treated by total coloproctectomy and ileo-anal anastomosis]. *Annales de chirurgie*. 1997;51(4):382-4.
13. Hervías D, Turrión JP, Herrera M, Navajas León J, Pajares Villarroya R, Manceñido N, et al. Diffuse cavernous hemangioma of the rectum: an atypical cause of rectal bleeding. *Revista española de enfermedades digestivas : organo oficial de la Sociedad Española de Patología*

- Digestiva. 2004;96(5):346-52.
14. Jeffery PJ, Hawley PR, Parks AG. Colo-anal sleeve anastomosis in the treatment of diffuse cavernous haemangioma involving the rectum. *The British journal of surgery*. 1976;63(9):678-82.
 15. Wang HT, Gao XH, Fu CG, Wang L, Meng RG, Liu LJ. Diagnosis and treatment of diffuse cavernous hemangioma of the rectum: report of 17 cases. *World journal of surgery*. 2010;34(10):2477-86.
 16. Rotholtz N, Bun ME, Laporte M, Sandra L, Carlos P, Mezzadri N. Rectal bleeding in Klippel-Trénaunay syndrome: treatment with laparoscopic ultralow anterior resection with intersphincteric dissection. *Surgical laparoscopy, endoscopy & percutaneous techniques*. 2009;19(5):e206-9.
 17. Mallios A, Laurian C, Houbballah R, Gigou F, Marteau V. Curative treatment of pelvic arteriovenous malformation--an alternative strategy: transvenous intra-operative embolisation. *European journal of vascular and endovascular surgery : the official journal of the European Society for Vascular Surgery*. 2011;41(4):548-53.
 18. Fujikawa H, Araki T, Hashimoto K, Okita Y, Tanaka K, Hiro J, et al. Sphincter-saving resection of rectal hemangioma based on Doppler transrectal ultrasonography findings: report of a case. *International surgery*. 2014;99(6):705-9.
 19. Pierce J, Matthews J, Stanley P, Panossian A, Ford H, Anselmo D. Perirectal arteriovenous malformation treated by angioembolization and low anterior resection. *Journal of pediatric surgery*. 2010;45(7):1542-5.