



## Rare Fibroadenoma of the Anal Region

Christopher Jerome Buzas<sup>1,\*</sup>, Anjali Mohan Gupta<sup>2,\*\*</sup>, Zong-Ming Chen and Jacqueline Oxenberg

<sup>1</sup>Geisinger Medical Center, Danville, United States

<sup>2</sup>Geisinger Medical Center, Wilkes-Barre, United States

\*Corresponding author: Geisinger Medical Center, Danville, United States. Email: [cjbuzas@geisinger.edu](mailto:cjbuzas@geisinger.edu).

\*\*Corresponding author: Geisinger Wyoming Valley, Wilkes-Barre, United States. Email: [amgupta@geisinger.edu](mailto:amgupta@geisinger.edu).

Received 2018 January 29; Revised 2018 August 03; Accepted 2018 August 07.

### Abstract

**Introduction:** Fibroadenomas are one of the most common benign breast lesions, however they have also been found on rare occasions elsewhere. These lesions usually arise from mammary-like glands (MLG) of the anogenital region which were first described by van der Putte.

**Methods:** This case is about a 51-year-old female who presents with symptomatic hemorrhoids and a 5 cm nodular lesion external to the anal verge. These were removed and examined histo-pathologically.

**Results:** Pathology revealed three hemorrhoidal specimens and the nodular lesion which was consistent with a fibroadenoma. Histologically, the nodular lesion demonstrated a benign process with ductal proliferation and estrogen receptors.

**Conclusions:** Fibroadenomas in anatomic locations other than the breast are very uncommon. Other sites noted in prior case reports include gallbladder, prostate, arm, eyelid and anogenital region. Most of the anogenital lesions have been found on the vulva, with only six documented cases in the anal region, making this pathology exceedingly rare.

**Keywords:** Fibroadenoma, Mammary-Like Glands, Anogenital Lesion, Perianal Lesion

### 1. Introduction

Hemorrhoids are the most common “mass” forming lesions in the anal region. Although rare, some benign and malignant neoplasms may arise in that anatomic location, mimicking hemorrhoids. Fibroadenomas are one of the most common benign breast lesions. These lesions are usually smooth, solid and well-defined. It is thought that they are related to hormonal changes as they are most commonly seen after puberty and can change in size related to pregnancy or exogenous hormone use. Diagnosis is made by fine needle aspiration or biopsy. Rare cases have been reported of fibroadenomas in locations other than the breast including gallbladder, prostate, arm, eyelid and anogenital region (1).

Herein, we report a case of fibroadenoma arising in the MLGs of the perianal region.

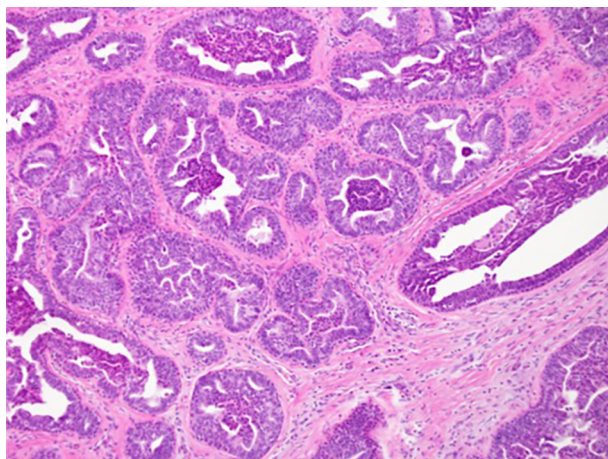
### 2. Case Presentation

A 51-year-old female presented with an eight-month-history of discomfort and pain related to hemorrhoids and a perianal lesion. These symptoms were exacerbated by sitting and defecation during which her hemorrhoids would protrude from the anus and need to be manually

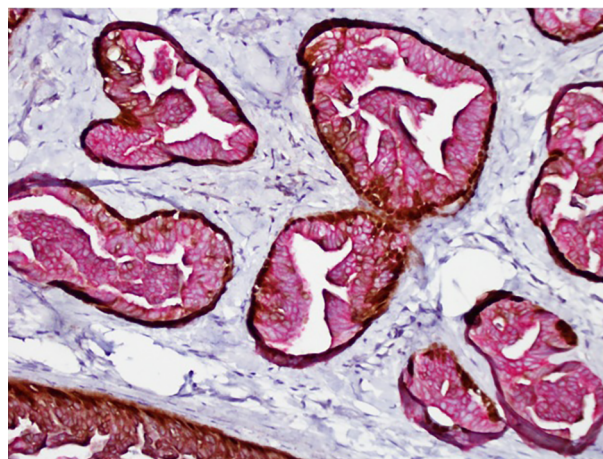
reduced. She denied constipation or any drainage but did note blood on the toilet paper when wiping. On initial presentation she was advised to increase her fiber and water intake and follow up with a colorectal surgeon.

The patient was seen by a colorectal surgeon approximately four months later at which time she continued to complain of pain and itching in the perianal area which was exacerbated with bowel movements. She noted normal consistency of her stool without bleeding or drainage. On exam she was noted to have large internal and external hemorrhoids of all three columns as well as a 2 cm nodular lesion 5 cm from the anal verge. She had a past medical history of diabetes, carpal tunnel and gastro-esophageal reflux disease. Her past surgical history included a supracervical partial hysterectomy for fibroids, tonsillectomy, nasal reconstruction, decompression of posterior tibial nerve, carpal tunnel repair with neuroplasty of the median nerve, and excision of mucous cyst from her thumb. Her family history was pertinent for diabetes, endocrine and thyroid disorders in both of her parents. She admitted to a 13-pack year history of smoking but denied alcohol or illicit drug use.

Two months later, the patient underwent a hemorrhoidectomy of complex internal and external hemor-



**Figure 1.** Dilated and tortuous glands show florid papillary epithelial hyperplasia, 10 × magnification



**Figure 2.** Specimen with immunostain BNC5 composed of a cocktail of antibodies including p63, CK5 and CK14 in brown; and CK7 and CK18 in red. This demonstrates an intact basal cell layer (brown) a mixed epithelial cell population in the lumen (red and brown). This indicates a benign process. 20 × magnification.

rhoids of all three columns as well as excision of the perianal lesion located at the left anterior anal margin.

On gross examination, three specimens were identified as hemorrhoids. The anterior anal margin excision specimen measured 1.6 × 1.1 × 0.8 cm with a 1.0 × 0.7 × 0.2 cm fibrous nodule. Microscopic examination showed a well-circumscribed tumor demonstrating florid ductal proliferation (Figure 1) with morphology akin to a nipple adenoma of the breast. A multi-marker immunostain (breast neoplasia cocktail 5, BNC5) was performed. As seen in Figure 2, p63, CK5 and CK14 are markers of basal cells and stained brown while CK7 and CK18 are markers of glandular epithelium and stained red. There is an intact basal cell layer with a mixed epithelial cell population in the lumen. This pattern is compatible with a benign proliferative process. Additionally, the tissue showed patchy positivity for estrogen receptors with a fibrous stroma. The histological characteristics indicate a diagnosis of a fibroadenoma arising from anogenital MLGs with florid ductal proliferation.

### 3. Discussion

Although rare, the literature has reported findings of fibroadenomas in the anogenital region. Initially, it was thought that these arose in ectopic breast tissue from the embryologic “milk line” that courses down the front of the body from the axilla to the groin. However, in 1991 Van der Putte introduced the concept of MLGs of the anogenital region (2). He described cutaneous glands in the anogenital region (predominantly the anus, labia and vulva), accounting for fibroadenomatous changes found beyond the extent of the milk line.

While fibroadenomas are very common in the breast, there are only about 40 cases described in the anogenital region (3) and only six of which were perianal rather than vulvar (1, 4-8). In most instances, the anogenital lesion was a well circumscribed, solitary mass that varied in size from 0.8 to 6 cm. These lesions may enlarge during pregnancy. Diagnosis was made at the average age of 38 - 39 years which is consistent with breast fibroadenomas that are related to hormonal changes.

Histologically, MLGs are identical to normal breast tissue and may arrange in ducts and lobular units. Ductal glandular epithelium is supported by a myoepithelial cell layer and usually transitions to a squamous epithelium just before opening onto the dermis (3). The most common benign neoplasms arising from MLGs are fibroadenomas. They may exhibit a spectrum of histological morphology, ranging from fibrous stroma predominant to florid glandular proliferation predominant. The stromal component may show an intra-canalicular or peri-canalicular growth pattern as well. Most of the lesions show similar immuno-histochemical staining profiles as do fibroadenomas of the breast. The epithelial layer stains with low molecular weight cytokeratins such as CK7 and CK18 while the myoepithelial cells stain with high molecular weight keratins like CK5 and CK14. The stromal cells are usually positive for vimentin, CD34 and smooth muscle actin. Both epithelial and stromal cells may be positive for estrogen/progesterone receptors (3). Very rarely, malignant neoplasms such as adenocarcinoma and phyllodes tumor may also arise from MLGs.

Rare cases of fibroadenomas in locations other than

the breast have also been reported in the gallbladder, prostate, arm, and eyelid (1). Clinical management may vary depending on location and presentation. Although surgical removal may not be necessary, it is usually curative for lesions causing symptoms.

### 3.1. Conclusion

Fibroadenomas in the anogenital region are exceedingly rare in the reported literature and are often misconstrued as other lesions until proven otherwise by pathology. Herein, we describe an uncommon location for a fibroadenoma arising in the MLGs of the perianal region.

### References

1. Solomon GJ, Shin SJ, Romanzi LJ. A 65-year-old woman with a "hemorrhoid". Fibroadenoma of the anogenital region. *Arch Pathol Lab Med*. 2006;**130**(2):e30-2. [PubMed: [16454578](#)].
2. van der Putte SC. Anogenital "sweat" glands. Histology and pathology of a gland that may mimic mammary glands. *Am J Dermatopathol*. 1991;**13**(6):557-67. [PubMed: [1666822](#)].
3. Kazakov DV, Spagnolo DV, Kacerovska D, Michal M. Lesions of anogenital mammary-like glands: an update. *Adv Anat Pathol*. 2011;**18**(1):1-28. doi: [10.1097/PAP.0b013e318202eba5](#). [PubMed: [21169735](#)].
4. Hedayat AA, Pettus JR, Marotti JD, Tafe LJ, Holubar SD, Lisovsky M. Proliferative lesion of anogenital mammary-like glands in the setting of Cowden syndrome: case report and review of the literature. *J Cutan Pathol*. 2016;**43**(8):707-10. doi: [10.1111/cup.12721](#). [PubMed: [27090873](#)].
5. Valente MA, Valente SA, Forsthoefel KF, Lee PK, Aguilar PS. Ectopic breast adenoma of the anal margin: an atypical presentation of anorectal pain. *Tech Coloproctol*. 2013;**17**(5):613-4. doi: [10.1007/s10151-012-0946-y](#). [PubMed: [23229560](#)].
6. Ahmed S, Campbell RM, Li JH, Wang LJ, Robinson-Bostom L. Adenoma of anogenital mammary-like glands. *J Am Acad Dermatol*. 2007;**57**(5):896-8. doi: [10.1016/j.jaad.2006.04.086](#). [PubMed: [17845825](#)].
7. Vella JE, Taibjee SM, Sanders DS, Stellakis M, Carr RA. Fibroadenoma of the anogenital region. *J Clin Pathol*. 2008;**61**(7):871-2. doi: [10.1136/jcp.2007.052290](#). [PubMed: [18587019](#)].
8. Doganavsargil B, Akalin T, Ylmaz M, Kandiloglu G. Perianal fibroadenoma, case report. *Am J Dermatopathol*. 2008;**30**(1):81-3. doi: [10.1097/DAD.0b013e31815f986f](#). [PubMed: [18212553](#)].