

The Role of Re-laparoscopy in the Management of Complications Following Laparoscopic Rectal Cancer Surgery: A Retrospective Case Series

Anahita Attaran¹, MD;^{ID} Fatemeh Shahabi¹, MSc; Ala Orafaie¹, PhD; Majid Ansari¹, MD; Reza Rezaei¹, MD; Abbas Abdollahi¹, MD^{ID}

¹Endoscopic and Minimally Invasive Surgery Research Center, Mashhad University of Medical Sciences, Mashhad, Iran

*Corresponding author:

Abbas Abdollahi, MD;
Endoscopic and Minimally Invasive Surgery Research Center, Mashhad University
of Medical Sciences, Postal code: 91766-99199, Mashhad, Iran. Tel: +98 51 38402972,
Fax: +98 51 38402972, Email: AbdollahiA@mums.ac.ir

Received: 2023-12-07

Revised: 2023-12-30

Accepted: 2023-12-30

Abstract

Introduction: The benefits of laparoscopy versus open surgery for patients with rectal cancer have been well established. This study evaluates the role of re-laparoscopy in patients who develop complications following laparoscopic rectal cancer surgery.

Methods: This is a retrospective case series of 22 (5.9%) re-laparoscopy cases of the 373 rectal cancer patients with rectal cancer who underwent laparoscopic primary surgery at Omid, Ghaem, and Razavi hospitals in Mashhad, Iran, between July 2011 and December 2020.

Results: Twenty-two (5.9%) eligible patients with a mean±SD age of 50.9±10.4 years were included in the study, of which 15 (68.2%) were men and 7 (31.6%) were women. After 22 primary laparoscopic surgeries, anastomosis-fail/peritonitis was the most common complication requiring re-laparoscopy (n=9, 40.9%). Other complications included obstruction (n=8, 36.4%), bleeding (n=3, 13.6%), and intestinal injury (n=2, 9.1%). The complications of all patients (n=22) who underwent re-laparoscopy were successfully managed by re-laparoscopy.

Conclusion: In the case of available facilities and the presence of an experienced surgeon in the medical center, re-laparoscopy for managing complications following laparoscopic rectal cancer surgery appears to be safe and effective in selected patients.

Keywords: Laparoscopy, Intraoperative complications, Rectal cancer, General surgery

Please cite this paper as:

Attaran A, Shahabi F, Orafaie A, Ansari M, Rezaei R, Abdollahi A. The Role of Re-laparoscopy in the Management of Complications Following Laparoscopic Rectal Cancer Surgery: A Retrospective Case Series. *Iran J Colorectal Res.* 2023;11(4):128-133. doi: 10.30476/ACRR.2023.100997.1197.

Introduction

Laparoscopic colorectal surgery is increasingly becoming the method of choice for the treatment of colorectal cancer or other related colorectal conditions. Since 1990, when the first laparoscopic colectomy was done (1), a large series of meta-analyses and randomized clinical trials have

been published to demonstrate the perception of a major improvement in postoperative results in the management of complications, recurrence of malignancy, and lateral pelvic floor dissection (2).

Since this minimally invasive procedure provides significant beneficial outcomes, it is considered the desirable approach for colorectal surgeries. However, using re-laparoscopy for treating complications after

laparoscopic colorectal surgery is still controversial (3). There are not enough supporting studies showing that re-laparoscopy in a patient with a history of recent laparoscopy would be the most appropriate treatment for complications such as intra-abdominal bleeding, intestinal obstruction, or anastomotic leakage (3, 4). The short- and long-term merits of re-laparoscopy, such as inconsiderable postoperative pain, blood loss, surgical site infection, faster intestinal function recovery, and shorter length of hospital stay in contrast with open surgery and other procedures, are argued in many studies (5, 6).

From a general perspective, when a patient is undergoing severe peritonitis symptoms or is hemodynamically unstable, laparotomy is favored by many surgeons (4). However, laparoscopy has also been used in several emergent conditions, offering favorable short-term outcomes (7). By employing this procedure, some of the open surgery-associated complications, such as organ failure, suture site infection, and ICU requirement, have been averted (5-7).

The present study aimed to describe the most competent approach to postoperative complications and evaluate the safety of re-laparoscopy in patients with a history of rectal cancer surgery.

Patients and Methods

Patients

This retrospective case series included 22 patients with locally advanced rectal cancer out of the 373 patients with rectal cancer who underwent laparoscopic curative surgery at Omid, Ghaem, and Razavi hospitals in Mashhad, Iran, between

July 2011 and December 2020. These 22 patients developed primary surgery complications during hospitalization and were managed by re-laparoscopic procedures. The final follow-up of these patients was in 2021, performed via a phone call. The patients were candidates for re-laparoscopy due to the presence of an experienced surgeon and their stable condition. All patients involved in the study scored II or III in the ASA indexing score. The ASA score is a classification system used to evaluate a patient's physical status before surgery, which ranges from 1 to 6. Higher scores indicate a greater risk of complications. Neoadjuvant chemoradiation therapy was administered for these patients, and the surgery was performed at least a month after chemoradiation. The chemotherapy treatment for our patients included Capecitabine 500 twice a day, along with a total of 28 sessions of radiation therapy, with a total radiation dose of 5400 rad. All patients received adjuvant chemotherapy after surgery. Studied patients were followed up based on standard rectal cancer surveillance till the fifth year after curative surgery.

Surgical Method

Some fundamental factors are needed for re-laparoscopy management of surgical complications, like optimal learning curve in laparoscopy and excellent laparoscopic equipment (vision, strong suction-irrigation system, etc.) (1).

In our experience, three or four laparoscopic ports are usually needed for re-laparoscopy, and a 10 mm umbilical port is needed for the camera. For primary exploration, other ports were inserted. The

Table 1: Clinical baseline information of patients with rectal adenocarcinoma who underwent re-laparoscopy.

Age at diagnosis, mean±SD		50.9±10.4
Primary Surgery time, median (Range) Minutes		215 (38)
Re-laparoscopic surgery time, median (Range) Minutes		150 (30)
Length of hospital stay, median (Range) Days		6 (1.5)
Gender, N (%)	Male	15 (68.2)
	Female	7 (31.8)
Rectal tumor location, N (%)	Lower	10 (45.5)
	Middle	7 (31.8)
	Upper	5 (22.7)
Primary surgical procedure technique, N (%)	Natural orifice specimen extraction	15 (68.2)
	Transabdominal specimen extraction	6 (27.3)
	Abdominoperineal resection	1 (4.5)
Re-laparoscopy cause, N (%)	Obstruction	8 (36.4)
	Intestinal injury	2 (9.1)
	Anastomosis-failure/peritonitis	9 (40.9)
	Bleeding	3 (13.6)
TNM staging, N (%) †	Pathologic complete response	4 (18.2)
	T1,2	2 (9.1)
	T3,4	7 (31.8)
	Node positive	6 (27.3)
	Metastatic	2 (9.1)

†The pathology data of one patient is missing.

surgeon was often on the patient's left side because some patients had an ileostomy on the right side. In obstructive cases, small bowel adhesions in the pelvis were managed better in this position. Obsessive exploration and suction-irrigation of four abdominal quadrants, sub-diaphragmatic, para-colic, pelvic, and inter-loop spaces were done in all cases. Ultimately, the decision was made case by case due to intra-operative findings and the patient's general conditions after the above steps.

Description of the Data

The normal and non-normal continuous data are reported as the mean±SD and median (IQR: inter-quartile range); categorical variables are expressed as frequency (percentage).

Results

Twenty-two eligible patients with a mean±SD age of 50.9±10.4 years were included in the study, of which 15 (68.2%) were men and 7 (31.8%) were women. The median (range) follow-up time (survival time) for all the patients was 71 (53) months. Rectal adenocarcinoma patients underwent primary laparoscopic surgery for natural orifice specimen extraction (15, 68.2%), transabdominal specimen extraction (6, 27.3%), and abdominoperineal resection (1, 4.5%). Descriptions of the data are summarized in Table 1. The patients underwent re-laparoscopy due to obstruction (8, 36.4%), internal organ injury (2, 9.1%), anastomosis-fail/peritonitis (9, 40.9%), or bleeding (3, 13.6%) (Figure 1). As reflected in Figure 1, the most common reason for the re-laparoscopy procedure was peritonitis, followed by anastomosis failure.

All patients were discharged from the hospital in good general condition after re-laparoscopy. During post-operative long-term follow-up sessions, six (27.3%) patients died due to local recurrence (3, 50%), bone/brain metastasis (1, 16.7%), and complications of cancer (1, 16.7%). In addition, one (16.7%) patient with liver metastasis died in the 29th month after primary surgery.

Discussion

Laparoscopic surgery for colorectal problems has become a promising approach worldwide. Accordingly, this minimally invasive procedure tends to be used instead of open intervention to bypass some surgical complications and can be performed safely after either open or laparoscopic surgery (8). However, despite considerable improvements in surgical techniques and patient outcomes, some difficulties continue to present and involve the patients (8). Even though this method has considerable benefits regarding postoperative recovery and outcomes, it has not been established as a definite practice for redo-surgery after laparoscopic colorectal resection till now (9). The present study investigated re-laparoscopy results in patients with a primary laparoscopy and complications of the initial procedure. Among all possible complications, some are more feared and might occur more commonly.

Peritonitis and anastomosis leakage are prevalent complications following colorectal surgery, which collaborates with increased morbidity and mortality rates. Anastomosis leakage is the most common indication for re-laparoscopy (67.7%) (9). Considering the prevalence of this complication, proper supervision is vital for reducing pressing consequences and can circumscribe treatment success (10). Secondly, other noticeable complications, including bowel obstruction, abdominal abscess, and bleeding, can be optimally handled through laparoscopy, as well (9-13). Other authors in various studies have recommended that a laparoscopic approach to diverse complications following laparoscopy or conventional laparotomy might be profitable in the surgical management of infection and intra-abdominal sepsis and, consequently, more minor postoperative septic difficulties (13, 14). The most common indication for re-laparoscopy in our patients was peritonitis/anastomosis failure (40.9%). However, 3 (13.6%) patients with bleeding and 2 (9.1%) patients with intestinal injury were managed by re-laparoscopy.

A major observational cohort study on 11,859

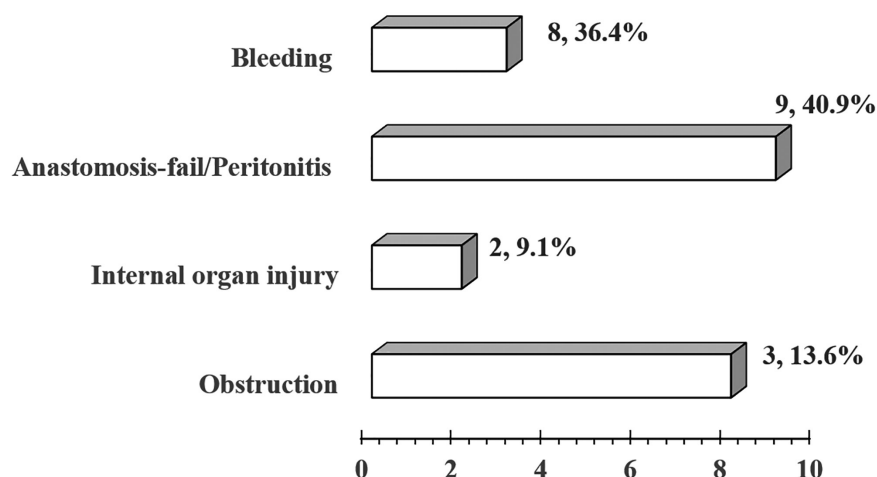


Figure 1: The frequency of re-laparoscopy indications in our patients.

patients with a history of laparoscopic surgery was performed by Vennix et al., in which 159 patients underwent a laparoscopic re-intervention. In comparison, 659 patients had an open re-operation. In this study, anastomosis leakage or anastomosis abscess accounted for most reintervention indications. This study finally concluded that laparoscopy is a feasible method of re-operation with a lower mortality rate and shorter hospital stay than open re-intervention (15).

A retrospective study by Vignali et al. was conducted regarding anastomosis leakage as the most common complication. Among 438 consecutive patients, 26 (5.8%) suffered from anastomosis leakage. Most underwent a successful re-laparoscopic procedure if they were hemodynamically stable (16). However, resuscitation followed by re-laparotomy in hemodynamically unstable patients in a postoperative setting is still the standard choice (17). Vignali's article, despite some limitations as a mono-centric study, demonstrated that the laparoscopic approach to anastomosis leakage might lead to a lower morbidity and mortality rate than an open approach (16). Another study conducted by Wind et al. investigated two groups of 10 and 15 patients with primary laparoscopy and laparotomy, respectively. Due to developing anastomosis leakage, each group underwent a re-laparoscopy or re-laparotomy based on their preceding procedures. They suggested that the re-laparoscopic approach to anastomosis leakage is associated with a lower mortality rate and fewer complications (17). Lee et al. concluded that laparoscopic re-intervention for anastomosis leakage after a minimally invasive colorectal surgery is correlated with fewer postoperative complications, including anastomotic leakage (18). The findings were confirmed by another article by Numata et al., illustrating that laparoscopic re-intervention for anastomotic leakage is feasible and safe. This study observed 3,321 patients from 2002 to 2016, and 39 patients developed anastomosis leakage after primary colorectal surgery. Re-laparoscopy was performed for 15 patients, and open surgery was conducted for those who needed an operation before April 2010 based on available techniques (19).

Obstruction was our study's second most common indication for re-laparoscopy (36.4%). Post-surgical obstructions, on the other hand, are not as prevalent as anastomosis leakage. However, they are still the number one cause of all small bowel obstruction cases, of which 50% will require surgery eventually (20). Even though many surgeons consider laparotomy the standard approach for adhesive small bowel obstruction (ASBO), studies are showing that laparoscopy can also be performed with more benefits (21). In a related study by Mancini et al. on 6,165 patients undergoing open and laparoscopic lysis of adhesions, the results revealed significant benefits in the laparoscopic approach (20). In addition, the findings of 262 patients in Valverde's study illustrated that laparoscopic management of

ASBO is associated with lower morbidity and better postoperative outcomes, particularly for patients with simple adhesion (22).

A less discussed and yet life-threatening complication of a recent surgery is postoperative bleeding, which became one of the primary evaluation purposes of this article. Holub et al. published their findings from a five-year study on six patients with intra-abdominal bleeding following laparoscopic or vaginal hysterectomy. They suggested that laparoscopic management is feasible and accompanied by more minor complications (23). In a similar study on three patients developing bleeding after laparoscopic urological surgery, re-laparoscopy led to a lower morbidity rate (24). Since there is limited data on the safety and feasibility of laparoscopy in managing post-surgical bleeding, we focused on gathering data on these patients and their outcomes.

In another analysis of sixty-four consecutive patients who underwent re-laparoscopy for possible complications of previous surgery, fifty-one (80%) had the re-operative procedures during the first 76 hours after the primary surgery. The main indications for re-exploration in these patients were severe abdominal pain (not localized at the place of surgery and port wounds) and peritonitis (25). In addition, they ascertained different possible complications, including bile or anastomotic leak, intra-abdominal hematoma, abscess, free fluid, tears, necrosis, mesh detachment, adhesion, and obstruction during re-exploration. Therefore, the authors of this study suggested avoiding diagnostic delay and unnecessary laparotomy by performing laparoscopy to endure postoperative complications after either open or laparoscopic surgery (23).

Finally, even though there have been significant advancements in the treatment of colorectal cancer, recurrence after a curative surgery has endured a considerable hurdle for surgeons (26). A 15-year publication by Park et al. showed that laparoscopic salvage has convenient benefits regarding surgical outcomes versus open surgery. This study also verified that laparoscopic salvage is a safe and feasible intervention with early advantages for chosen cases (26).

Conclusion

On condition that facilities are available at the treatment center and an experienced specialist surgeon is present, re-laparoscopy in the treatment of surgical complications that occur during the hospitalization after the primary rectal cancer surgery, even bleeding, can be a safe approach.

Ethics Approval and Consent to Participate

The information on the patients of this study was taken from the Colorectal Cancer Registry (No: 4001728). The study was approved by the Mashhad University of Medical Sciences Ethical

Committee (IR.MUMS.REC.1400.340) and was performed in accordance with the Declaration of Helsinki. Mashhad University of Medical Sciences Ethical Committee waived the need for informed consent due to the study's retrospective nature.

Availability of Data and Materials

The datasets used and/or analyzed during the current study are available from the corresponding author upon reasonable request.

Acknowledgment

The authors would like to thank Ghaem, Omid, and

Razavi Hospitals of Mashhad, where the surgeries were conducted.

Authors' Contribution

A.A.T, A.O, F.S, A.A, R.R and M.A contributed in design, data gathering, and writing the manuscript. All authors have reviewed and approved the final version and agreed to be accountable for all aspects of the work in ensuring that questions related to the accuracy or integrity of any part of the work are appropriately investigated and resolved.

Conflict of interest: None declared.

References

- Jacobs M, Verdeja JC, Goldstein HS. Minimally invasive colon resection (laparoscopic colectomy). *Surgical Laparoscopy Endoscopy & Percutaneous Techniques*. 1991;1(3):144-50.
- Halkias C, Zoikas A, Garoufalia Z, Konstantinidis MK, Ioannidis A, Wexner S. Re-Operative Laparoscopic Colorectal Surgery: A Systematic Review. *Journal of clinical medicine*. 2021;10(7).
- Angeramo CA, Schlottmann F, Laporte M, Bun ME, Rotholtz NA. Re-laparoscopy to Treat Early Complications After Colorectal Surgery: Is There a Learning Curve? *Surgical laparoscopy, endoscopy & percutaneous techniques*. 2022;32(3):362-7.
- Ibáñez N, Abrisqueta J, Luján J, Sánchez P, Soriano MT, Arevalo-Pérez J, et al. Reoperation after laparoscopic colorectal surgery. Does the laparoscopic approach have any advantages? *Cirugia espanola*. 2018;96(2):109-16.
- Chang KH, Bourke MG, Kavanagh DO, Neary PC, O'Riordan JM. A systematic review of the role of re-laparoscopy in the management of complications following laparoscopic colorectal surgery. *The surgeon : journal of the Royal Colleges of Surgeons of Edinburgh and Ireland*. 2016;14(5):287-93.
- O'Riordan JM, Larkin JO, Mehigan BJ, McCormick PH. Re-laparoscopy in the diagnosis and treatment of postoperative complications following laparoscopic colorectal surgery. *The surgeon : journal of the Royal Colleges of Surgeons of Edinburgh and Ireland*. 2013;11(4):183-6.
- Wright DB, Koh CE, Solomon MJ. Systematic review of the feasibility of laparoscopic reoperation for early postoperative complications following colorectal surgery. *The British journal of surgery*. 2017;104(4):337-46.
- McCormick JT, Simmang CL. Reoperation following minimally invasive surgery: are the "rules" different? *Clinics in colon and rectal surgery*. 2006;19(4):217-22.
- Fransvea P, Costa G, D'Agostino L, Sganga G, Serao A. Redo-laparoscopy in the management of complications after laparoscopic colorectal surgery: a systematic review and meta-analysis of surgical outcomes. *Techniques in coloproctology*. 2021;25(4):371-83.
- Cimitan A, Contardo T, Molaro R, Morpurgo E. The Role of Laparoscopy in the Treatment of Anastomotic Leaks After Minimally Invasive Colorectal Resections for Cancer. *Surgical laparoscopy, endoscopy & percutaneous techniques*. 2016;26(4):e80-4.
- McAllister I, Sagar PM, Brayshaw I, Gonsalves S, Williams GL. Laparoscopic restorative proctocolectomy with and without previous subtotal colectomy. *Colorectal disease : the official journal of the Association of Coloproctology of Great Britain and Ireland*. 2009;11(3):296-301.
- Rotholtz NA, Laporte M, Lencinas SM, Bun ME, Aued ML, Mezzadri NA. Is a laparoscopic approach useful for treating complications after primary laparoscopic colorectal surgery? *Diseases of the colon and rectum*. 2009;52(2):275-9.
- Rosin D, Zmora O, Khaikin M, Bar Zakai B, Ayalon A, Shabtai M. Laparoscopic management of surgical complications after a recent laparotomy. *Surgical endoscopy*. 2004;18(6):994-6.
- Novitsky YW, Litwin DE, Callery MP. The net immunologic advantage of laparoscopic surgery. *Surgical endoscopy*. 2004;18(10):1411-9.
- Vennix S, Bakker OJ, Prins HA, Lips DJ. Re-interventions following laparoscopic surgery for colorectal cancer: data from 818 individuals from the Dutch surgical colorectal audit. *Journal of laparoendoscopic & advanced surgical techniques Part A*. 2014;24(11):751-5.
- Vignali A, Elmore U, Aleotti F, Roberto D, Parise P, Rosati R. Re-laparoscopy in the treatment of anastomotic leak following laparoscopic right colectomy with intracorporeal anastomosis. *Surgical endoscopy*. 2021;35(11):6173-8.
- Wind J, Koopman AG, van Berge Henegouwen MI, Slors JF, Gouma DJ, Bemelman WA. Laparoscopic reintervention for anastomotic leakage after primary laparoscopic colorectal surgery. *The British journal of surgery*. 2007;94(12):1562-6.
- Lee CM, Huh JW, Yun SH, Kim HC, Lee WY, Park YA, et al. Laparoscopic versus open reintervention for anastomotic leakage following minimally invasive colorectal surgery. *Surgical endoscopy*. 2015;29(4):931-6.
- Numata M, Yamaguchi T, Kinugasa Y, Shiomi A, Kagawa H, Yamakawa Y, et al. Safety and feasibility of laparoscopic reoperation for treatment of anastomotic leakage after laparoscopic colorectal cancer surgery. *Asian journal of endoscopic surgery*. 2018;11(3):227-32.
- Mancini GJ, Petroski GF, Lin WC, Sporn E, Miedema BW, Thaler K. Nationwide impact of laparoscopic lysis of adhesions in the management of intestinal obstruction in the US. *Journal of the American College of Surgeons*. 2008;207(4):520-6.
- O'Connor DB, Winter DC. The role of laparoscopy in the management

- of acute small-bowel obstruction: a review of over 2,000 cases. *Surgical endoscopy*. 2012;26(1):12-7.
22. Sebastian-Valverde E, Poves I, Membrilla-Fernández E, Pons-Fragero MJ, Grande L. The role of the laparoscopic approach in the surgical management of acute adhesive small bowel obstruction. *BMC surgery*. 2019;19(1):40.
23. Holub Z, Jabor A. Laparoscopic management of bleeding after laparoscopic or vaginal hysterectomy. *JSLS: Journal of the Society of Laparoendoscopic Surgeons*. 2004;8(3):235-8.
24. Gong EM, Zorn KC, Gofrit ON, Lucioni A, Orvieto MA, Zagaja GP, et al. Early laparoscopic management of acute postoperative hemorrhage after initial laparoscopic surgery. *Journal of endourology*. 2007;21(8):872-8.
25. Kirshtein B, Domchik S, Mizrahi S, Lantsberg L. Laparoscopic diagnosis and treatment of postoperative complications. *The American journal of surgery*. 2009;197(1):19-23.
26. Park SY, Choi GS, Jun SH, Park JS, Kim HJ. Laparoscopic salvage surgery for recurrent and metachronous colorectal cancer: 15 years' experience in a single center. *Surgical endoscopy*. 2011;25(11):3551-8.