

New Techniques in Anal Fistula Management

Rasoul Azizi^{1,*}; Saman Mohammadipour¹

¹Department of Colorectal Surgery, Rasoul Akram Medical Center, Iran University of Medical Sciences (IUMS), Tehran, IR Iran

*Corresponding author: Rasoul Azizi, Department of Colorectal Surgery, Rasoul Akram Medical Center, Iran University of Medical Sciences, Tehran, IR Iran. Tel: +98-9121242149, Fax: +98-2166509056, E-mail: razizimd@hotmail.com

Received: January 21, 2014; Revised: February 21, 2014; Accepted: February 22, 2014

Context: The management of complicated anal fistula is a serious issue in coloproctology. Various methods have been described but the choice must be made based on the course of the fistula tract in relation to the sphincter. As anal fistulas are caused by anal gland infection, the anal gland and ducts should be removed for the process of healing to begin and for the anal sphincter preservation. The aim of this study is to briefly explain and assess three new sphincter preserving surgical treatments, including fibrin glue and anal plug techniques and the procedure of ligation of intersphincteric fistula tract (LIFT) and also to evaluate the failure and success rates of these techniques.

Evidence Acquisition: We conducted a search in the literature of the last decade, in the PubMed database, using the keywords: anal Fistula, LIFT procedure, fibrin glue and anal plug.

Results: Using anal fistula plug provides another option for the treatment of complex anal fistulas and does appear to be an effective technique in some cases. The technique of intersphincteric fistula tract ligation as a fistula treatment surgery, aims for total anal sphincter preservation and appears to be both safe and easy to perform, with encouraging early outcomes. The authors suggest further controlled studies comparing the LIFT procedure with standard therapies.

Conclusions: Fibrin sealant injection should be in the armamentarium of the specialists' surgical treatments for fistula-in-ano. The surgeons and their patient should be aware of the limited success expectations, when using fibrin glue technique as the treatment.

Keywords: Anal Fistula; Rectal Fistula; Fecal Incontinence; Anal Sphincter

1. Context

1.1. Historical Background

The management of complicated anal fistula remains a challenge for surgeons and a frustrating problem for patients. Treatment aims to cure the condition, with drainage of the associated infected gland abscess and eradication of the fistula tract. The majority of perianal infections are either idiopathic or crypto-glandular in origin. All methods of fistula repair rely on the elimination of the fistula internal opening to the anal gland (1). Anorectal abscess and the fistula that it may cause, are long-term processes, originally described at the beginning of the recorded medical history, as part of the "Corpus Hippocraticum" in a treatise termed "On Fistulae" (2).

1.2. Pathophysiology

Anorectal abscess occurs commonly in normal healthy individuals. The most widely recognized cause is described in the crypto-glandular theory; an anal crypt gland becomes obstructed with debris, which leads to infection. Anal fistulas develop in approximately one-third

to one-half of the patients undergoing an anorectal abscess drainage. There exist other notable causes of atypical/complicated abscess and fistula, including inflammatory bowel disease, fungal infection, mycobacterial infection, neoplasm and trauma. Fistulas, secondary to these processes are classified as complex and require the use of nonstandard methods of management (3).

1.3. Classification of Anal Fistula

The four main classes of fistulas are:

1) Intersphincteric: the fistula originates at the dentate line and tracks elongated between the internal and external sphincters.

The fistula opens in the perianal region, close to the anal verge. This kind is commonly seen following a perianal abscess and is typical of the ones seen in fistulizing midline anal fissures.

2) Transsphincteric: the fistula originates at the dentate line and traverses the internal and external sphincters, opening to the ischio-rectal fossa. Depending on the height of the fistula, varying degrees of sphincter involvement may be encountered. Treatment of high transsphincteric fistulas is more challenging due to the

Implication for health policy/practice/research/medical education:

The aim of this study is to briefly explain and assess three new surgical anal fistula treatment techniques, including fibrin glue, anal plug and LIFT procedure and evaluate the failure and success rates of these techniques.

Copyright © 2014, Colorectal Research Center and Health Policy Research Center of Shiraz University of Medical Sciences; Published by Safnek. This is an open-access article distributed under the terms of the Creative Commons Attribution License, which permits unrestricted use, distribution, and reproduction in any medium, provided the original work is properly cited.

increased risk of incontinence.

3) Suprasphincteric: originates at the dentate line and tracks cephalad to the external sphincter, before opening to the skin at the ischio-rectal fossa. Due to the high risk of total incontinence development, these fistulas are not amenable to simple fistulotomy.

4) Extrasphincter: transverses the entire sphincter structure including puborectalis, opening proximally either at the dentate line (secondary to supraleator abscess) or in the lower rectal wall (secondary to internal or external penetrating trauma) and distally into the ischio-rectal fossa or in the buttocks. This type of fistula is often secondary to trauma or Crohn's disease (4).

Different complex fistulas are defined as those that transverse > 30% of the external sphincter, those in patients with pre-existing continence issues or following irradiation and Crohn's disease, high transsphincteric, suprasphincteric and extrasphincteric fistulas, anterior fistulas in a female, having multiple tracks and happening recurrently (5). The most frequent presenting complaints of patients with an anal fistula are swelling, pain and discharge. The former two symptoms are usually associated with an abscess, when the external or secondary opening has closed or has failed to develop (6). Anal fistula may be confused with suppurative hidradenitis and pilonidal sinus and the doctor needs to be careful to make the right diagnosis.

1.4. Identification of the Fistula Tract

Numerous methods can be employed, the basic principles and procedures of which include the application of Goodsall's rule, careful physical examination (to find any cord like structure or external orifices, etc.), probing of the tract, endosonography and a variety of injection and radiologic techniques (7).

1.5. Principles of Surgical Treatment

The aim of surgery for anal fistula is to cure the patient with minimal or no sequel. It takes an accurate assessment of the fistula and an experienced surgeon who deals with fistulas on a daily basis to perform the appropriate operation and prevent postsurgical incontinence. To obtain this outcome, a number of principles have to be observed; the primary opening of the track has to be identified and also the relationship of the fistula to the puborectalis muscle must be distinguished. Furthermore, the least amount of muscle should be divided for the fistula management (8).

It is controversial whether fistulotomy or fistulectomy is the more appropriate surgical treatment for anal fistulas. Fistulectomy means the complete removal of the fistulous track and adjacent scar tissue, which results in appreciably larger wounds (9).

There are always concerns if the division of the muscle

below the track will impair the patient's continence. In these cases, the advancement of rectal flap technique would be appealing with less sphincter muscle to be divided. Avoidance of contour defects, experiencing less pain due to the absence of a perineal wound and a faster healing process are the AMF (advancement mucosal flap) advantages (6). Management of fistula-in ano has changed over years, from seton placement and sphincter-cutting techniques to recent muscle saving procedures. Setons can be employed as cutting and non-cutting kinds as dividers or markers (10). A few types of setons used are the Ayurveda-medicated thread (11), braided sutures (12) thread, rubber band (13), Penrose drains (14) and cable tie seton (15). Seton material should be non-absorbable, from non-slippage material, comfortable and least irritant for the patient and equally effective in causing focal reaction in the track, leading to fibrosis. In the last decade beside these procedures, fistulotomy, fistulectomy and AMF with seton have also been used as new techniques for fistula treatment. In this review of article we clarify three techniques, beside their failure results reported in the articles (4). We also introduce video-assisted anal fistula treatment (VAAFT) as an alternative modality.

1.6. New Techniques

Sphincter-sparing procedures are the standard treatment of anal fistula. The search for the effective treatments, not compromising continence has led to the development of the following techniques:

- 1) Anal fistula plug
- 2) Ligation of the intersphincteric fistula tract (LIFT)
- 3) Fibrin glue
- 4) VAAFT

1.7. Anal Fistula Plug

Small intestinal submucosa (SIS) is a natural biomaterial, harvested from porcine small intestine and fabricated into a biomedical product of various shapes and thicknesses (Figure 1) (16). The fact that it has been extensively used as a bioprosthesis material in the field of infectious diseases makes its application in fistula surgery quite reasonable.

The Surgisis anal fistula plug (AFP) has a biological configuration, suitable for fistula diseases. This material provides a matrix to allow infiltration of the patient's connective tissue.

Currently, there are two commercially available fistula plugs approved by the FDA: Cook Surgisis AFP™ anal fistula plug (Cook Surgical Inc., Bloomington, IN) and the Gore Bio-A fistula plug (a new product from W.L. Gore Corporation, Newark, DE). They vary in both design and the material, from which they are constructed (18). Indications and contraindication for the use of the plug include (19):

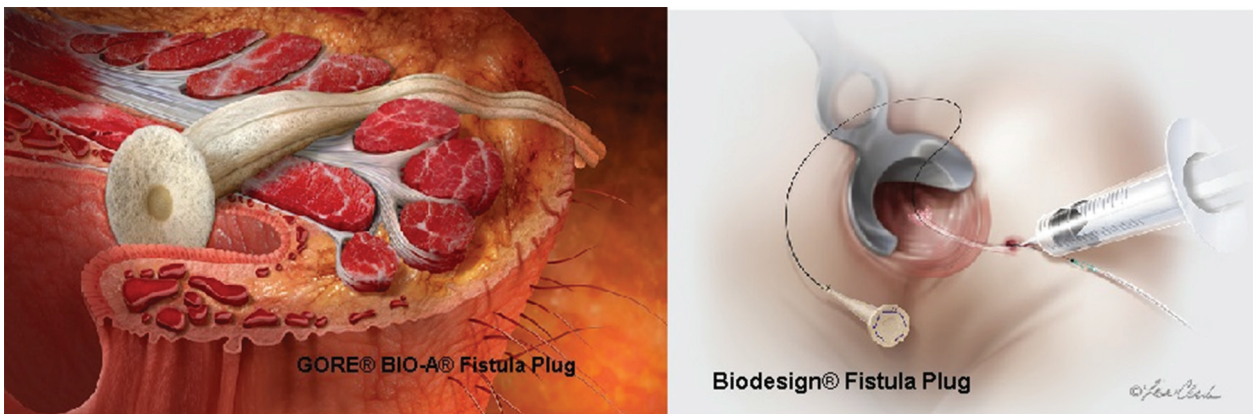


Figure 1. Anal Fistula Plug (From the Original Web Site) (17)

Indications:

- 1) Transsphincteric fistula
- 2) Anovaginal fistula
- 3) Intersphincteric fistula
- 4) Extrasphincteric fistula.

Contraindications:

- 1) Persistent abscess or infection
- 2) Intersphincteric fistula (when no contraindication to fistulotomy exists)
- 3) Inability to identify the internal and external openings
- 4) Allergy to the plug material
- 5) Rectovaginal fistula.

In the absence of data, bowel preparation and/or the use of a small-volume enema should be left to each surgeon's personal preference. A careful inspection should confirm that there is no active infection prior to preparing the fistula plug. The previously placed draining seton should be pulled out and the tract will be irrigated with saline. The plugs require rehydration, fully submerged in sterile saline for no more than two minutes. Afterwards the procedure goes as the following steps:

- 1) Gently debride the tract
- 2) Place the plug within the tract
- 3) Secure the plug to the internal opening
- 4) Leave external opening wide open to allow the drainage.

The most frequent complication, other than the fistula tract closure failure, is abscess formation. Infectious complications are managed with antibiotics or may at times require drainage procedures. Pain is generally minimal and easily managed with oral narcotics. Plug extrusion or fall out has frequently been listed among the complications or technical failures of these procedures. Ellis et al. (20) reported that posterior fistula location, tobacco smoking and a history of previous failure of the plug were independent predictors of plug failure.

1.8. Ligation of the Intersphincteric Fistula Tract

LIFT is a promising new sphincter sparing procedure,

first described by Rojanasakul et al. in 2007. A success rate of 94.4% was reported in the treatment of 18 patients (21, 22). There is no division of the sphincter muscle and theoretically, continence should be preserved. This technique has been used in low and high transsphincteric fistulas, as well as suprasphincteric and extrasphincteric fistulas (21). The current indications for the surgery are:

- 1) Low transsphincteric fistulas
- 2) High transsphincteric fistulas
- 3) Potentially suprasphincteric/extrasphincteric fistulas where the tract transverses the intersphincteric space
- 4) Recurrent fistulas
- 5) Pre-existing continence issues
- 6) Multiple tracks.

In our opinion, contraindications to this approach are few, but may include (18):

- 1) Active perineal sepsis
- 2) Active inflammatory bowel disease
- 3) Malignancy.

In author's opinion insertion of a seton, 8-12 weeks before performing the LIFT is useful for eliminating the infection in the area and maturation of the fistula tract.

The technique consists of the following steps:

- 1) Identification of the intrasphincteric fistula tract
- 2) The skin is incised in a curvilinear fashion along the intersphincteric groove. The dissection is kept close to the external sphincter to avoid cutting through the internal sphincter.
- 3) Dissection of the fistula tract
- 4) Ligation and division of the fistula tract
- 5) Addressing the fistula openings
- 6) Closure (optional).

This operation may be performed in prone jackknife or lithotomy position, under either regional or general anesthesia. Patients are administered only a single dose of appropriate peri-operative antibiotics intravenously, usually cefoxitin or ciprofloxacin/metronidazole if the patient is penicillin-allergic. The LIFT can be safely performed on any transsphincteric fistula of suitable length. The LIFT procedure is relatively easy to perform and its

advantages include preservation of the anal sphincter, minimal tissue injury and shorter healing time (23).

Performing the LIFT procedure may be technically difficult for high transsphincteric or suprasphincteric fistulas. Typically, LIFT failures fall into two broad categories: early (procedural failure) and late (recurrence). If the LIFT failure happens patients can still undergo other treatments like simple lay-open fistulotomy, salvage LIFT or various flap procedures. The LIFT technique excellence is not only due to its initial healing rates, but also based on the fact that even when unsuccessful, it may predispose the patient to subsequent healing, without the risk of incontinence.

1.9. Fibrin Glue

Fibrin glue is a tissue adhesive that simulates the terminal steps of the natural clotting cascade. The sealant degrades as the fibrotic reaction progresses, ultimately getting fully replaced by the natural tissue. Therefore, no foreign body persists and the tract scars simply closed (24). Fibrin gluing of anal fistulas is simple and repeatable. The mentioned factors make this technique a highly desirable treatment option. Fibrin tissue adhesive was first successfully used as a hemostatic agent in the early 1900s (25).

Although prior to 1998, the operative procedure for fibrin glue injection of anal fistula treatment in the United States was performed using autologous fibrin sealant, currently most surgeons utilize commercially prepared fibrin sealant when gluing anorectal fistulas. These operative procedures are typically performed in outpatient settings. Oral and/or intravenous antibiotics are not necessary. Determination of the fistula primary or internal opening location is essential in order to improve the success rate of the procedure. The tract should then be gently debrided without undue dilatation. After debridement, the tract should be irrigated with saline or hydrogen peroxide for cleansing it. The fibrin sealant is prepared according to the manufacturer's instructions.

The sealant is slowly injected at the internal opening and allowed to set. The clot is allowed to solidify for 5-10 minutes. The external orifice is then dressed with a non-adherent dressing (26).

One of the most common complications associated with the use of fibrin sealant for anorectal fistulas is the infection development, typically at the site of the external or secondary opening. Other complications or side effects may be secondary to the components that constitute the product itself.

Using fibrin glue as a first line or beside other treatments has been of controversies over the last decade. The pathophysiology of the process is likely the same as anal fistula plugging. Both materials are used to occlude the tract after the debridement to destroy and eradicate the tract, but as formerly mentioned choosing the plug or using the sealant, both depend on different factors.

1.10. Alternative Modality

VAAFT is performed as the surgical treatment of complex anal fistulas and their recurrences. (Figure 2) (27). Current surgical techniques for treating anal fistulas are based on three main principles: identification of the tract and the internal opening, excision of the fistula tract and preservation of anal sphincter function, especially in the three methods described and identification of internal and external orifice. VAAFT appears cost effective and requiring a shorter and less expensive preoperative work-up than traditional techniques.

VAAFT is also performed as a day surgery, it leaves no surgical wounds on the buttocks or in the perianal region and gives complete certainty regarding the location of the internal fistula opening (a key point in all surgical treatment of fistulas) (28). VAAFT technique is based on the concept of both tract and its internal opening detection and also the detection of any fistula branches which may be missed. The author suggests the use of this technique, for more complex fistulas as a diagnostic and therapeutic modality, beside the new techniques of treatment.

2. Evidence Acquisition

We conducted a search in the last decade literature, in the PubMed database, using the keywords: anal fistula, LIFT procedure, fibrin glue and anal plug.

3. Results

In the last decade lots of articles have been published about AFP. According to articles, there are variable success and failure rates of AFP reported (29). According to some studies from USA (30-32), China (33) and Italy (34, 35) the success rate of AFP was between 25-85%. Some studies point out that the success rate depends on factors like multiple prior attempts for closure (36), pervious surgery (37, 38), incontinence (39), complicity of fistula (40), cost

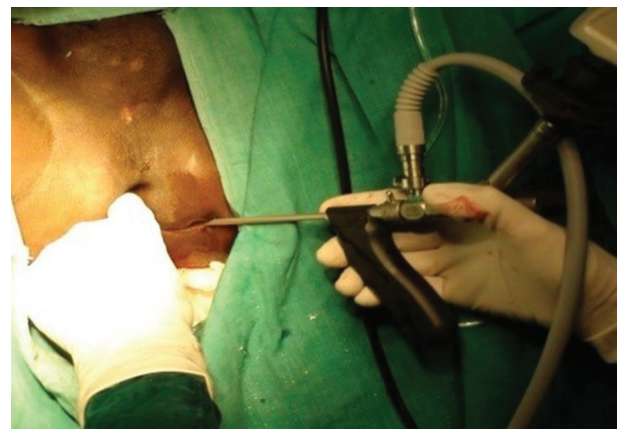

Figure 2. Fistuloscope Introduction Through External Fistula Opening During Video-Assisted Anal Fistula Treatment (27)

benefitting of the procedure (41) and texture of the plug according to the manufacturer (31).

In 2010, Garg et al. published a systematic review about anal fistula plug in India and concluded there was a moderate success rate of 35-87% for this technique. AFP is associated with low morbidity and sepsis and appears to be a safe procedure (42). Many articles did not attain proper results due to little sample sizes, assessing other techniques beside AFP and lack of data (23, 43-47).

Chung W et al. in 2009 reported that the primary fistula opening closure using biological AFP and anal flap advancement result in similar fistula healing rates in patients with high transsphincteric fistulas (48). In an unpublished experience, the author and his colleagues performed this method on eight complex fistulas using plugs from the Cook medical brand. They were followed up for 6 to 12 months. In this period except for one case of recurrence and one case of a plug falling out, all patients were fully cured. Finally we were able to report that regarding the mentioned factors, there is not a definite result for failure or success rate of the AFP. Although there is a great variability of results among different groups in the articles (30-35), with preserving the anal anatomy and function, the safety of this procedure is generally not questioned. While initial enthusiasm has subsequently been tempered, anorectal fistula plugs do appear to be effective in some individuals.

As mentioned before, LIFT is a new technique, as quite as we cannot definitely announce its exact success rate but in few articles published after Rojanasakul et al. study, all the short term results (49, 50) were meaningful. In 2011, Azizi and colleagues reported that LIFT is a novel treatment method for complicated fistula-in-ano. The procedure success rate is comparable with other sphincter sparing procedures. Furthermore, LIFT is easy to learn, very cost effective and more importantly, appears to be a safe procedure. Durability and efficacy of the procedure must be confirmed by long-term follow ups and randomized control clinical trials. In one study the procedure was performed on 23 patients with a 32 month follow up. Successful fistula closure was achieved in 74% of the patients (17 out of 23) (50).

In 2013, Liu et al. (51) and Sileri et al. (52) demonstrated favorable long-term results for the LIFT procedure and considered it a proper choice for patients affected by complex anal fistula. Some studies combined LIFT with other techniques like plug or bioprosthetic graft (BioLIFT) and promoted the healing rate (53-55). The BioLIFT technique is a variation of the LIFT technique, in which a bioprosthetic graft is placed in the intersphincteric plane to reinforce the closure of the fistula tract. Compared to the LIFT, the BioLIFT technique has two potential disadvantages: it requires more extensive dissection in the intersphincteric space because the bioprosthetic graft must cover the closure of the fistula tract by at least 1 to 2 cm in all directions and it is relatively costly, due to the use of bioprosthetic materials. LIFT appears to be both safe and easy to

perform, with encouraging early outcomes and authors suggest further controlled studies, comparing the LIFT procedure with the standard treatments. The success rate of using fibrin glue is also variable due to different published articles: as low as reported by Buchanan (56) to as high as 70% reported by Jurczak (57) and Tinay (58). This difference indicates that healing rates of this method depend on factors necessitating further studies.

No advantage was found for fibrin glue over fistulotomy for simple fistula treatment, but fibrin glue healed more complex fistulas than the conventional treatment, with higher patients' satisfaction (2). In one meta-analysis of fibrin glue vs. surgery for treatment of fistula-in-ano in 2010, no significant statistical difference was detected between fibrin glue treatment and the conventional surgical treatment (59).

Beside moderate success rates, safety of the fibrin glue use in the treatment of anal fistulas (60), sphincter function preservation with minimal adverse side effects (61, 62) and extensive surgery preclude (63) are noted in articles. Chung et al. (48) in 2009 and Johnson et al. (44) in 2006 reported greater efficacy for biological plug than fibrin glue, due to two reasons: 1- Ability to suture the plug in the primary opening, 2- Low morbidity and relative simplicity of the procedure. In one study in 2010 Papavramidis and the colleagues (64), mentioned not everybody believes in the effectiveness of fibrin glue application, however we consider this solution in cases of complex fistulas, at least as a primary procedure in special populations like the immunosuppressed.

The wide variation in the results may be partially attributable to differences in technical factors, inclusion criteria, definitions of healing and follow-up duration. However, surgeon and the patient should be aware of the limited expectations for success when fibrin glue is used as the treatment.

4. Conclusions

AFPs have been an extremely popular option due to this technique indications and good safety profiles. AFP provides one more option for surgeons for the treatment of complex anal fistulas and does appear to be effective in some patients. The success rate depends on factors like multiple prior attempts for closure, previous surgery, incontinence, fistula complicity, cost benefitting of the procedure and texture of the plug according to the manufacturer. Although there is a great variability among the results of different articles, with preserving the anal anatomy and function, the safety of this procedure is generally not questioned.

The LIFT procedure is a new technique that can be used for managing the complicated issue of fistula-in-ano. It is simple, inexpensive, quick and has a success rate at least as good or better than all current sphincter-preserving methods. The rate of closure remains anywhere near 40-60%. The LIFT procedure allows using other types of

approaches (including another LIFT) in patients with recurrence. The use of the LIFT procedure for fistula treatment, aims for the total anal sphincter preservation and appears to be both safe and easy to perform, with encouraging early outcomes and author suggest further controlled studies, comparing the LIFT procedure with standard therapies. Fibrin sealant injection carries essentially no risk of incontinence, as there is no division of sphincter muscle. The available data, even in the long-term, suggest a moderate success rate, at best. Given its safety profile, ease of application and repeatability, fibrin sealant injection should be in the armamentarium of the specialists' surgical treatments for fistula-in-ano. Surgeons and their patients should be aware of the limited success expectations, when fibrin glue is used as the treatment technique.

Fistula-in-ano remains a complex condition, for the treatment of which there have been evolved a variety of sphincter-preserving techniques (46).

Acknowledgements

Special thanks go to Dr. Saman Mohammadi Pour with Dr. Azizi supporting.

Authors' Contribution

The main idea of article goes to Dr. Azizi. All collecting data base, writing and editing has done by Dr. Mohammadipour.

Financial Disclosure

No financial interest to report.

Funding/Support

The manuscript has been supported by the Colorectal Center of Iran University of Medical Sciences.

References

- Muellerleile K, Sultan A, Groth M, Steven D, Hoffmann B, Adam G, et al. Velocity encoded cardiovascular magnetic resonance to assess left atrial appendage emptying. *J Cardiovasc Magn Reson*. 2012;**14**:39.
- Loffler T, Welsch T, Muhl S, Hinz U, Schmidt J, Kienle P. Long-term success rate after surgical treatment of anorectal and rectovaginal fistulas in Crohn's disease. *Int J Colorectal Dis*. 2009;**24**(5):521-6.
- Julie A, Rizzo MD, Anna L, Naig MD. Anorectal Abscess and Fistula-in-Ano: Evidence-Based Management. *Surg Clin N Am*. 2010;**90**(1):45-68.
- Anal Fistula: Principles and Management*. Abcarian H editor. New York: Springer; 2014.
- Whiteford MH, Kilkenny J, 3rd, Hyman N, Buie WD, Cohen J, Orsay C, et al. Practice parameters for the treatment of perianal abscess and fistula-in-ano (revised). *Dis Colon Rectum*. 2005;**48**(7):1337-42.
- Marvin L. Corman and Roberto. In: Bergamaschi CM editor. *Corman's colon and rectal surgery*. 6th ed. Philadelphia: LIPPINCOTT Williams & Wilkins; 2013. p. 385.
- Goodsall DH, Miles WE. *Diseases of the anus and rectum*. England: Longmans, Green; 1900.
- Surgery of the Colon, Rectum and Anus*. Hawley PR, Fielding LP, Goldberg SM editors. Oxford: Butter-worth- Heinemann; 1988.
- Lange J, Molle B, Girona J. *Chirurgische Proktologie*. Heidelberg: Springer; 2006.
- Pearl RK, Andrews JR, Orsay CP, Weisman RI, Prasad ML, Nelson RL, et al. Role of the seton in the management of anorectal fistulas. *Dis Colon Rectum*. 1993;**36**(6):573-7.
- Ho KS, Tsang C, Seow-Choen F, Ho YH, Tang CL, Heah SM, et al. Prospective randomised trial comparing ayurvedic cutting seton and fistulotomy for low fistula-in-ano. *Tech Coloproctol*. 2001;**5**(3):137-41.
- Abcarian H. Anorectal infection: abscess-fistula. *Clin Colon Rectal Surg*. 2011;**24**(1):14-21.
- Hanley PH. Rubber band seton in the management of abscess-anal fistula. *Ann Surg*. 1978;**187**(4):435-7.
- Culp CE. Use of Penrose drains to treat certain anal fistulas: a primary operative seton. *Mayo Clin Proc*. 1984;**59**(9):613-7.
- Memon AA, Murtaza G, Azami R, Zafar H, Chawla T, Laghari AA. Treatment of complex fistula in ano with cable-tie seton: a prospective case series. *ISRN Surg*. 2011;**2011**:636952.
- Ellis CN. Bioprosthetic plugs for complex anal fistulas: an early experience. *J Surg Educ*. 2007;**64**(1):36-40.
- Biodesign@ Fistula Plug . 2014. Available from: https://www.cookmedical.com/product/catalog/?ds=sur_afp_webds.
- Steven D, Wexner JF. *Colon and rectal surgery: anorectal operations*. Philadelphia: Lippincott Williams & Wilkins; 2012.
- Abcarian H. *Anal Fistula: Principles and Management*. New York: Springer; 2014.
- Ellis CN, Rostas JW, Greiner FG. Long-term outcomes with the use of bioprosthetic plugs for the management of complex anal fistulas. *Dis Colon Rectum*. 2010;**53**(5):798-802.
- Rojanasakul A, Pattanaarun J, Sahakitrungruang C, Tantiphlachiva K. Total anal sphincter saving technique for fistula-in-ano; the ligation of intersphincteric fistula tract. *J Med Assoc Thai*. 2007;**90**(3):581-6.
- Rojanasakul A. LIFT procedure: a simplified technique for fistula-in-ano. *Tech Coloproctol*. 2009;**13**(3):237-40.
- Song KH. New techniques for treating an anal fistula. *J Korean Soc Coloproctol*. 2012;**28**(1):7-12.
- Singer M, Cintron J. New techniques in the treatment of common perianal diseases: stapled hemorrhoidopexy, botulinum toxin, and fibrin sealant. *Surg Clin North Am*. 2006;**86**(4):937-67.
- Radosevich M, Goubran HI, Burnouf T. Fibrin sealant: scientific rationale, production methods, properties, and current clinical use. *Vox Sang*. 1997;**72**(3):133-43.
- Singer M, Cintron J, Nelson R, Orsay C, Bastawrous A, Pearl R, et al. Treatment of fistulas-in-ano with fibrin sealant in combination with intra-adhesive antibiotics and/or surgical closure of the internal fistula opening. *Dis Colon Rectum*. 2005;**48**(4):799-808.
- Khanna S. Video endoscopic treatment of complex anal fistula-A new emerging treatment modality. *Clarion*. 2012;**1**(1):14-20.
- Meinero P, Mori L. Video-assisted anal fistula treatment (VAAFT): a novel sphincter-saving procedure for treating complex anal fistulas. *Tech Coloproctol*. 2011;**15**(4):417-22.
- Steven D, Wexner JF. *Colon and rectal surgery: anorectal operations*. Philadelphia: Lippincott Williams & Wilkins; 2012.
- Cintron JR, Abcarian H, Chaudhry V, Singer M, Hunt S, Birnbaum E, et al. Treatment of fistula-in-ano using a porcine small intestinal submucosa anal fistula plug. *Tech Coloproctol*. 2013;**17**(2):187-91.
- Buchberg B, Masoomi H, Choi J, Bergman H, Mills S, Stamos MJ. A tale of two (anal fistula) plugs: is there a difference in short-term outcomes? *Am Surg*. 2010;**76**(10):1150-3.
- Champagne BJ, O'Connor LM, Ferguson M, Orangio GR, Schertzer ME, Armstrong DN. Efficacy of anal fistula plug in closure of cryptoglandular fistulas: long-term follow-up. *Dis Colon Rectum*. 2006;**49**(12):1817-21.
- Han JG, Yi BQ, Wang ZJ, Zheng Y, Cui JJ, Yu XQ, et al. Ligation of the intersphincteric fistula tract plus a bioprosthetic anal fistula plug (LIFT-Plug): a new technique for fistula-in-ano. *Colorectal Dis*. 2013;**15**(5):582-6.
- Lenisa L, Espin-Basany E, Rusconi A, Mascheroni L, Escoll-Rufino J, Lozoya-Trujillo R, et al. Anal fistula plug is a valid alternative option for the treatment of complex anal fistula in the long term.

- Int J Colorectal Dis.* 2010;**25**(12):1487-93.
35. Heydari A, Attina GM, Merolla E, Piccoli M, Fazlalizadeh R, Melotti G. Bioabsorbable synthetic plug in the treatment of anal fistulas. *Dis Colon Rectum.* 2013;**56**(6):774-9.
 36. Chan S, McCullough J, Schizas A, Vasas P, Engledow A, Windsor A, et al. Initial experience of treating anal fistula with the Surgisis anal fistula plug. *Tech Coloproctol.* 2012;**16**(3):201-6.
 37. Ommer A, Herold A, Joos A, Schmidt C, Weyand G, Bussen D. Gore BioA Fistula Plug in the treatment of high anal fistulas-initial results from a German multicenter-study. *Ger Med Sci.* 2012;**10**:Doc13.
 38. Kleif J, Hagen K, Wille-Jorgensen P. Acceptable results using plug for the treatment of complex anal fistulas. *Dan Med Bull.* 2011;**58**(3).
 39. Pu YW, Xing CG, Khan I, Zhao K, Zhu BS, Wu Y. Fistula plug versus conventional surgical treatment for anal fistulas. A system review and meta-analysis. *Saudi Med J.* 2012;**33**(9):962-6.
 40. Thekkinkattil DK, Botterill I, Ambrose NS, Lundby L, Sagar PM, Buntzen S, et al. Efficacy of the anal fistula plug in complex anorectal fistulae. *Colorectal Dis.* 2009;**11**(6):584-7.
 41. Adamina M, Hoch JS, Burnstein MJ. To plug or not to plug: a cost-effectiveness analysis for complex anal fistula. *Surgery.* 2010;**147**(1):72-8.
 42. Garg P, Song J, Bhatia A, Kalia H, Menon GR. The efficacy of anal fistula plug in fistula-in-ano: a systematic review. *Colorectal Dis.* 2010;**12**(10):965-70.
 43. Safar B, Jobanputra S, Sands D, Weiss EG, Noguera JJ, Wexner SD. Anal fistula plug: initial experience and outcomes. *Dis Colon Rectum.* 2009;**52**(2):248-52.
 44. Johnson EK, Gaw JU, Armstrong DN. Efficacy of anal fistula plug vs. fibrin glue in closure of anorectal fistulas. *Dis Colon Rectum.* 2006;**49**(3):371-6.
 45. Hadzhiev B. Our first experience in treatment of ano rectal fistula with SURGISIS AFP Anal Fistula Plug. *Khirurgiia (Sofia).* 2011(1):33-8.
 46. Blumetti J, Abcarian A, Quinteros F, Chaudhry V, Prasad L, Abcarian H. Evolution of treatment of fistula in ano. *World J Surg.* 2012;**36**(5):1162-7.
 47. O'Riordan JM, Datta I, Johnston C, Baxter NN. A systematic review of the anal fistula plug for patients with Crohn's and non-Crohn's related fistula-in-ano. *Dis Colon Rectum.* 2012;**55**(3):351-8.
 48. Chung W, Kazemi P, Ko D, Sun C, Brown CJ, Raval M, et al. Anal fistula plug and fibrin glue versus conventional treatment in repair of complex anal fistulas. *Am J Surg.* 2009;**197**(5):604-8.
 49. Shanwani A, Nor AM, Amri N. Ligation of the intersphincteric fistula tract (LIFT): a sphincter-saving technique for fistula-in-ano. *Dis Colon Rectum.* 2010;**53**(1):39-42.
 50. Sileri P, Franceschilli L, Angelucci GP, D'Ugo S, Mito G, Cadeddu F, et al. Ligation of the intersphincteric fistula tract (LIFT) to treat anal fistula: early results from a prospective observational study. *Tech Coloproctol.* 2011;**15**(4):413-6.
 51. Liu WY, Aboulian A, Kaji AH, Kumar RR. Long-term results of ligation of intersphincteric fistula tract (LIFT) for fistula-in-ano. *Dis Colon Rectum.* 2013;**56**(3):343-7.
 52. Sileri P, Giarratano G, Franceschilli L, Limura E, Perrone F, Stazi A, et al. Ligation of the Intersphincteric Fistula Tract (LIFT): A Minimally Invasive Procedure for Complex Anal Fistula: Two-Year Results of a Prospective Multicentric Study. *Surg Innov.* 2013.
 53. Tan KK, Lee PJ. Early experience of reinforcing the ligation of the intersphincteric fistula tract procedure with a bioprosthetic graft (BioLIFT) for anal fistula. *ANZ J Surg.* 2014;**84**(4):280-3.
 54. Cui JJ, Wang ZJ, Zheng Y, Han JG, Yang XQ. [Ligation of the intersphincteric fistula tract plus bioprosthetic anal fistula plug (LIFT-plug) in the treatment of transsphincteric perianal fistula]. *Zhonghua Wei Chang Wai Ke Za Zhi.* 2012;**15**(12):1232-5.
 55. Ellis CN. Outcomes with the use of bioprosthetic grafts to reinforce the ligation of the intersphincteric fistula tract (BioLIFT procedure) for the management of complex anal fistulas. *Dis Colon Rectum.* 2010;**53**(10):1361-4.
 56. Buchanan GN, Bartram CI, Phillips RK, Gould SW, Halligan S, Rockall TA, et al. Efficacy of fibrin sealant in the management of complex anal fistula: a prospective trial. *Dis Colon Rectum.* 2003;**46**(9):1167-74.
 57. Jurczak F, Laridon JY, Raffaitin P, Pousset JP. [Biological fibrin used in anal fistulas: 31 patients]. *Ann Chir.* 2004;**129**(5):286-9.
 58. Tinay OE, El-Bakry AA. Treatment of chronic fistula-in-ano using commercial fibrin glue. *Saudi Med J.* 2003;**24**(10):1116-7.
 59. Cirocchi R, Santoro A, Trastulli S, Farinella E, Di Rocco G, Vendetuali D, et al. Meta-analysis of fibrin glue versus surgery for treatment of fistula-in-ano. *Ann Ital Chir.* 2010;**81**(5):349-56.
 60. Gisbertz SS, Sosef MN, Festen S, Gerhards MF. Treatment of fistulas in ano with fibrin glue. *Dig Surg.* 2005;**22**(1-2):91-4.
 61. Yeung JM, Simpson JA, Tang SW, Armitage NC, Maxwell-Armstrong C. Fibrin glue for the treatment of fistulae in ano—a method worth sticking to? *Colorectal Dis.* 2010;**12**(4):363-6.
 62. Oca J, Millan M, Jimenez A, Golda T, Biondo S. Long-term results of surgery plus fibrin sealant for anal fistula. *Colorectal Dis.* 2012;**14**(1):e12-5.
 63. Haim N, Neufeld D, Ziv Y, Tulchinsky H, Koller M, Khaikin M, et al. Long-term results of fibrin glue treatment for cryptogenic perianal fistulas: a multicenter study. *Dis Colon Rectum.* 2011;**54**(10):1279-83.
 64. Papavramidis TS, Pliakos I, Charpidou D, Petalotis G, Kollaras P, Sapalidis K, et al. Management of an extrasphincteric fistula in an HIV-positive patient by using fibrin glue: a case report with tips and tricks. *BMC Gastroenterol.* 2010;**10**:18.