

Effects of Platelet-Rich Plasma on Healing of Sphincteroplasty: An Experiment in Rabbit Model

Ahmad Izadpanah¹, Habibollah Nikzadjamrani¹, Ali Reza Safarpour^{1*}, Ahad Izadpanah², Seyed Mohammad Kazem Tadayon¹

¹Colorectal Research Center, Shiraz University of Medical Sciences, Shiraz, Iran

²Department of Anesthesiology, Shiraz University of Medical Sciences, Shiraz, Iran

*Corresponding authors:

Ali Reza Safarpour,
Colorectal Research Center, Shiraz University of Medical Sciences, Shiraz, Iran
Tel/Fax: +98 71 36281453; Email: safarpourar@gmail.com

Received: 13/03/2019

Accepted: 12/10/2019

Abstract

Background: The inability to manage stool release, fecal incontinence, is a condition with severe negative effects on quality of life. The use of platelet-rich plasma (PRP) may improve the healing of the anal sphincter after surgery. The current study investigated the healing effects of PRP application after surgical repair of the anal sphincter in rabbits as an animal model for human studies.

Methods: Twenty-four New Zealand rabbits were randomly allocated into four groups based on the time of sampling after sphincteroplasty (one or three weeks) and the use or lack of use of PRP. Sphincterotomy followed by sphincteroplasty was performed on all the animals; autologous PRP was prepared and administered at a dose of 0.5 ml per animal in the PRP groups. The healing scores of the sphincters were compared across the groups using a histological scoring system.

Results: In the rabbits sacrificed and sampled after one week, the mean histological healing score was significantly higher in the group with PRP application relative to the group for which PRP was withheld (18.6 ± 0.8 vs. 13.0 ± 1.8 , respectively; $P=0.01$). However, no significant difference was detected between the healing scores of the PRP group and the control group when sampling was performed three weeks after surgery (19.0 ± 0.0 vs. 18.5 ± 0.8 , respectively; $P=0.17$).

Conclusion: Our findings indicate that although PRP can accelerate wound healing after sphincter repair in an animal model, its effect over time, specifically after three weeks, is insignificant.

Keywords: Anal sphincter, Healing, Platelet-rich plasma, Sphincterotomy, Sphincteroplasty

Please cite this paper as:

Izadpanah A, Nikzadjamrani H, Safarpour AR, Izadpanah A, Tadayon SMK. Effects of Platelet-Rich Plasma on Healing of Sphincteroplasty: An Experiment in Rabbit Model. *Ann Colorectal Res*. 2019;7(3):2-8. doi: .

Introduction

Fecal incontinence (FI) is defined as the inability to manage stool release (1). This condition is debilitating, with negative impacts most notably on the sexual and social quality of life. Embarrassment, social isolation, and changes in family relationships are among the harsh consequences of this condition (2). Its prevalence varies from 5 to 15% within the general population, particularly depending on age and gender. These rates are most likely underestimated because less than 25% of patients with FI report it to their physicians (2, 3). Generally, female patients are more commonly evaluated for FI than their male counterparts (4, 5). Muscular injuries of the anus occur in up to 35% of women after vaginal delivery as the most common cause of FI (6). In addition, about 90% of women with FI and only risk factor for obstetric damage have an anterior defect in one or both anal sphincters. The damages are both mechanical and neurological, occurring due to muscle rupture and the stretching of the pudendal nerve (7).

There are different ways to manage FI. Anal sphincteroplasty is usually suggested when medical treatments of defects in the external anal sphincter don't seem to be successful (8-10). Repair of the anterior anal sphincter is the most effective operation for FI with excellent short-term success rates of 70-80%, which declines to 50 and 40% after 5 and 10 years, respectively (11, 12). As a new strategy, it has been reported that platelet-rich plasma (PRP) augments wound healing as a result of featuring a high growth factor content (13, 14). To prepare PRP as a surgical graft material, autologous blood is centrifuged before being combined with thrombin and calcium chloride to provide a viscous coagulum gel (15). Indeed, calcium chloride and thrombin induce the growth factor cascade through activation of platelets (16). The wound healing process is promoted by PRP through the induction of the release of many cytokines and growth factors (17). In previous studies, autologous PRP was used as an adjunct to the membrane advancement flap in the treatment of perianal fistulae; declines in recurrence, complication, and incontinence rates were reported (18, 19).

Although many studies have been published on similar interventions and surgical wound healing, and despite the fact that a systematic review and meta-analysis was published on the use of PRP gel on wound healing (20), the effects of PRP after sphincteroplasty have not previously been reported. Hence, our study was designed to evaluate the histopathological repairing effects of autologous PRP application once after sphincteroplasty.

Materials and Methods

Study Design

A sample size of 24 was calculated after

approximating the t-statistic using a z-statistic based on the reported formula (21), the following considerations were made: α (two-tailed)=0.05; β =0.2; effect size=0.8; and standard deviation (SD)=0.8. Thus, this animal-based experimental study was performed on 24 female New Zealand rabbits with a weight range of 2.5-3 kg and age of 6 months; these rabbits were obtained from the Center of Comparative and Experimental Medicine, Shiraz University of Medical Sciences, Shiraz, Iran. Animals were kept under a standard 12-hour light/dark cycle with free access to water and standard rodent food. The study protocol was approved by the Institutional Review Board (IRB) of Shiraz University of Medical Sciences and the approval of the Ethics Committee (No. 8875) was achieved before experimentation was commenced. All efforts were made to attenuate needless handling or pain induction for the rabbits. The experimental set up is presented in Figure 1 and discussed in detail in the sections that follow.

PRP Preparation

In this work, an autologous PRP preparation yield of 10-16% was achieved. Specifically, the gravitational platelet separation procedure was used to prepare 3-5 ml of PRP from 30 ml of blood depending on the baseline platelet count of the individual (22). In this procedure, blood sampling was done before the blood was mixed with 3.8% citrate dextrose anticoagulant solution at a 9:1 (v:v) ratio. To separate the PRP, centrifugation at $400 \times g$ and $20^\circ C$ was performed for 15 min. Also, the plasma was centrifuged at 3000 rpm and $20^\circ C$ for 10 min to obtain the platelet pellet. To obtain the platelet count, the Sysmex XT-1600i system was used. The platelet concentrate was dissolved in phosphate buffer saline (PBS) then pooled and incubated at room temperature for 30 min on a rotating platform to eliminate platelet agglomerates.

Surgical Procedure

Sphincterotomy and sphincteroplasty were performed similar to human surgical procedures (23) at 9.00 am in a specialized animal operation room. Animals were anesthetized with 80 mg/kg Ketamine and 12 mg/kg Xylazine, which comprises the most common animal anesthetic procedure without any effects on wound healing. During surgery, supplemental sedation was administered as required. The operation site was shaved and disinfected, with the rabbits having been fixed in lithotomy position. Pulse oximetry and esophageal temperature probes were positioned, before each rabbit underwent tracheal intubation. Sphincterotomy was performed in the posterior midline using the No. 11 blade. At first, a transverse incision was made posterior to the anus. Then, the free ends of the sphincter muscle were found and all fibers of the external and internal sphincters were cut and separated. Immediately

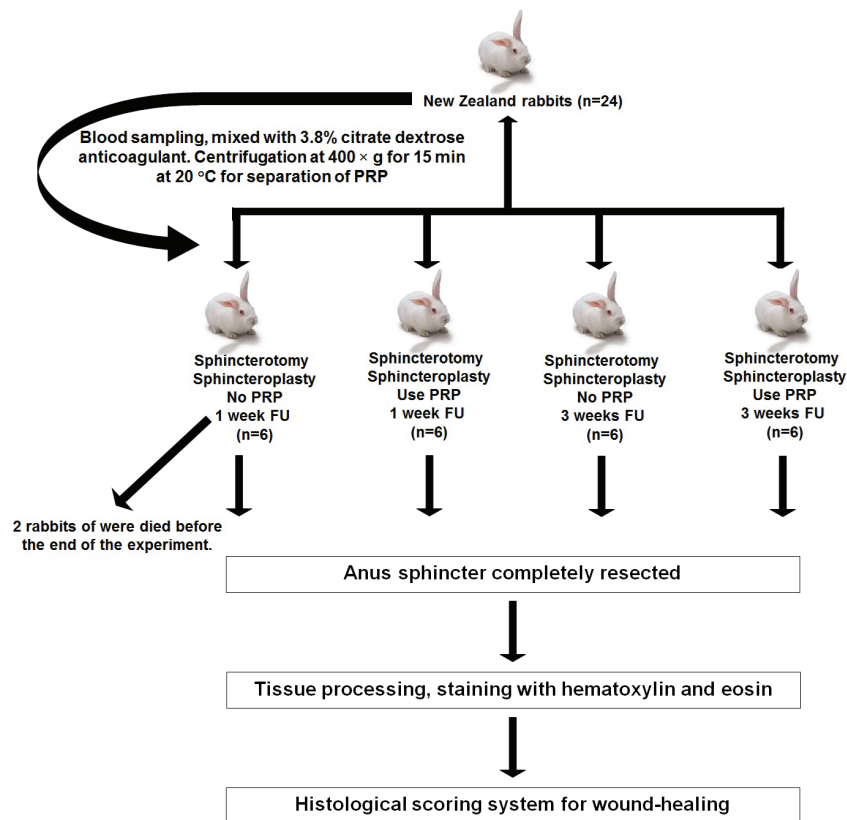


Figure 1: Experimental set-up and procedures.

afterward, sphincteroplasty was done to repair the sphincter. Simple end-to-end sphincter repair was done with 4-0 Prolene suture, before the skin over the site of repair was closed with 4-0 chromic suture.

PRP Treatment

To find the effects of PRP application over time, the rabbits were randomly allocated into four groups and each group was considered as an experimental unit. Group 1 underwent sphincteroplasty without administration of PRP, and tissues were obtained after the animals were sacrificed one week after repair; group 2 differed only in that PRP was given. In group 3, sphincteroplasty was conducted without PRP administration, and tissues were harvested three weeks after repair. Finally, group 4 had sphincteroplasty with PRP administration, and tissues were obtained three weeks after repair. Although it is known that the lifespan of the platelet is approximately 7 days and more than 80% of its alpha-granule contents are released in the first 24-48 h following platelet degranulation, only a single injection was performed to simulate human situations. Therefore, PRP was injected around the suturing site using an insulin syringe at a dose of 0.5 ml per animal. Surgeons and their assistances were blinded about the groups and treatments. To acquire the specimen, the rabbits were sacrificed with intracardiac injections of 10% KCl solution under deep general anesthesia. Then, the anal sphincter was completely resected and the repair

site was marked with a 5-0 nylon suture. The tissues were fixed in 10% buffered formalin solution for future processing.

Histopathologic Evaluation

The obtained tissues were stained with standard hematoxylin and eosin before being evaluated by a blinded expert pathologist. Histopathological findings were evaluated for each sample according to a modified scoring system (24). This scoring system is useful in defining the surgical wound-healing process and may also allow for standardizing reports on surgical wound healing following both vaginal and abdominal pelvic reconstructive and anti-incontinence operations (Table 1).

Statistical Analysis

Data were expressed as mean±SD and analyzed using SPSS version 17 (SPSS Inc., Chicago, IL, USA). Because of the non-parametric nature of this study and existence of 24 rabbits in four independent groups, the Mann-Whitney U test was used for comparison between each pair of groups. P-values below 0.05 were considered for significance.

Results

The primary mean whole blood platelet count was 6×10^5 cells/ μ L, which increased by 3-fold in PRP (18×10^5 cells/ μ L). The procedure failed in two rabbits belonging to group 1, and these animals died before

Table 1: Histological scoring system for wound-healing

Score	Epithelialization	Collagenization	Inflammation	NV	Necrosis	GT
1	None	None	Severe	None	Extensive	none
2	None	None	Moderate	None	Focal	Immature
3	Partial	Partial	Mild	<5 per HPF ^a	None	Mild mature
4	Complete, Immature	Complete, Irregular	None	6-10 per HPF	None	Moderately mature
5	Complete, Mature	Complete, Regular	None	>10 per HPF	None	Fully mature

HPF: High power field; NV: Neo-vascularization; GT: Granulation tissue

the end of the experiment. Therefore, data related to these two animals were excluded from the analysis. All other animals had good health conditions until they were sacrificed for tissue sampling. The histopathological changes and repair in the PRP-administered and control groups after one and three weeks are presented in Figure 2. Also, data related to the six different parameters that were assessed to obtain the histological healing score are presented in Figure 3. As shown, epithelialization, neovascularization, and necrosis were the healing factors in which significant differences existed between the two groups only after one week of surgery. A significant difference was detected in the histological healing score between the PRP-administered and control groups after one week (18.6 ± 0.8 vs. 13.0 ± 1.8 , respectively; $P=0.01$), but this difference was not significant after three weeks (19.0 ± 0.0 vs. 18.5 ± 0.8 , respectively; $P=0.17$). Also, although it is surprising that the presence of PRP had a positive effect on granulation tissue and negative effect on inflammation relative to the absence of PRP, these differences were not statistically significant ($P>0.05$).

Discussion

In the present study, the effects of PRP application throughout sphincteroplasty on healing of rabbit's sphincter were investigated. We found that the mean histologic healing score of the sphincters was higher in the PRP-administered group as compared to the group that did not receive PRP at both one and three weeks after surgery, but this difference was only significant between the pair of groups sampled after one week. These findings demonstrate the short-term beneficial effects of using PRP during sphincteroplasty.

Sphincteroplasty is the most frequent technique that is used for sphincter repair in patients with severe FI. However, wound complications occur in about one-third of patients (25). For treatment of this complication, some additional steps are needed. Gastrointestinal wound healing is characterized by the three phases of inflammation, proliferation, and maturation. Platelets play key roles in the inflammation step. Indeed, growth factors of platelets mediate the whole process by controlling growth, differentiation, and cell metabolism (26).

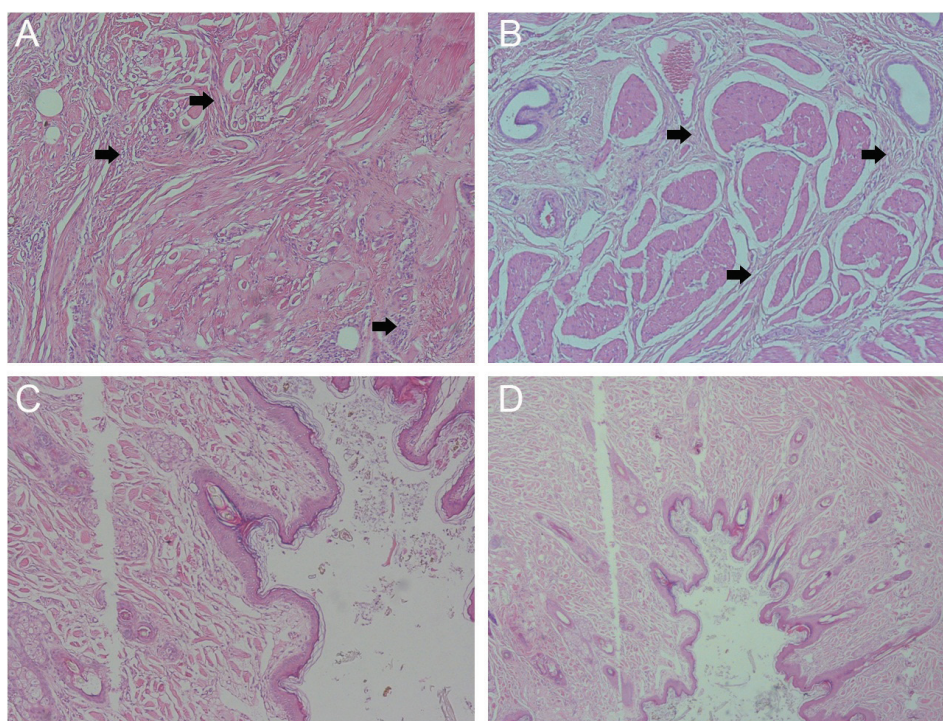


Figure 2: Histopathological features of anal tissue. A, fibroblast proliferation between muscular fibers and mild chronic inflammation after one week without use of PRP; B, traverse fibrous bands between myocyte bundles after one week with use of PRP (the histological lesions are indicated by black arrows); C and D, cross section of anal mucosa showing complete repair after three weeks without and with PRP use, respectively (stained with hematoxylin and eosin (H&E), $\times 100$).

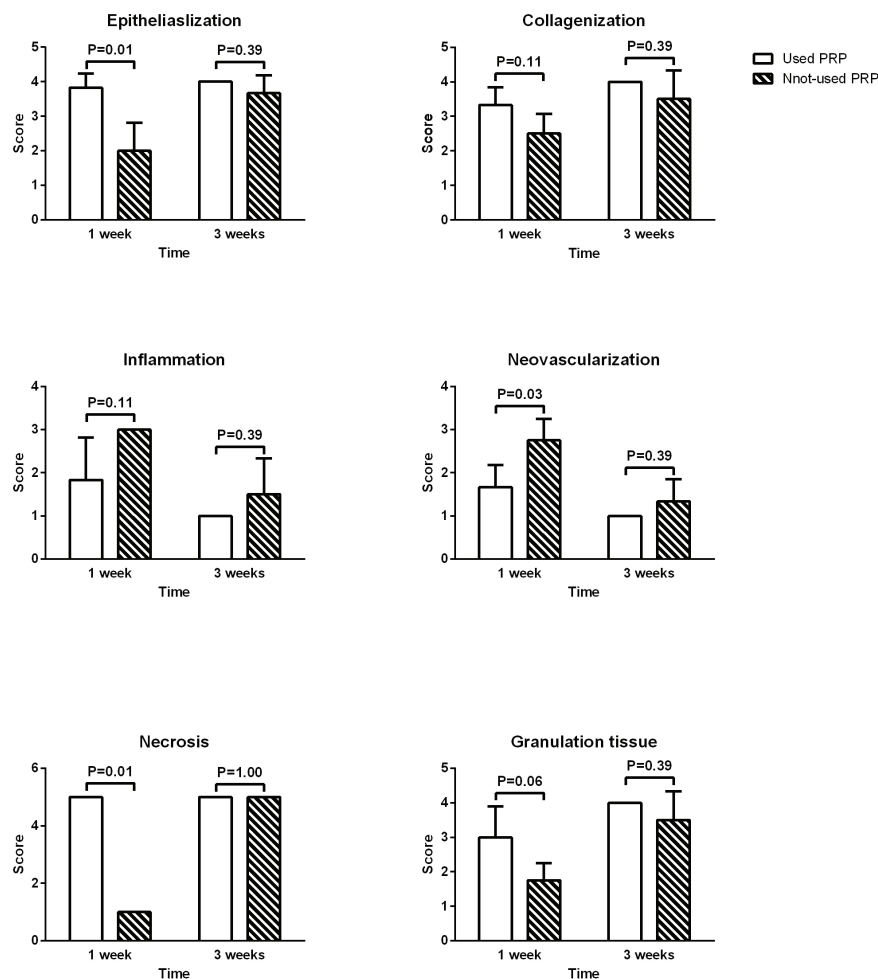


Figure 3: Histological scoring of wound-healing at different times and in different groups. The number of animals in all groups was equal (n=6) at the beginning of the study, but the procedure failed in 2 rabbits belonging to the group for which PRP was not used and the specimen was obtained after one week.

The theoretical benefit of PRP is providing an area setting for tissue regeneration that is made in growth factors and alternative cytokines (27). Based on the points mentioned, PRP application to gastrointestinal anastomosis can be used to activate fibroblasts and enhance collagen formation through different growth factors that enable a rise in anastomotic strength.

It is noted that PRP was prepared after two-steps of centrifugation of autologous blood with none commercial kits. In addition, the platelet-poor plasma (PPP) was also simply prepared, and the PRP concentration could be modified by addition of various quantities of PPP. Some authors have advocated the elimination of leukocytes (28), whereas many studies have shown that leukocytes in the buffy coat play some roles in the effects of PRP (29). Therefore, the effects of the buffy coat are unclear (30), and the PRP contained no buffy coat in our method.

To the best of our knowledge, there are few studies that have investigated the effects of PRP on wound healing in anal sphincter repair. There are certain disagreements between scientists concerning the advantages of PRP application. Variations in platelet concentration, type of clot activator, white blood

cell count and the time that the fibrin scaffold is put into place around the tissue markedly influence the biological effects (31). When we compared the effects of PRP on healing after one week, it significantly helped to accelerate wound healing. However, it had no significant effects after three weeks. Some studies on oral and maxillofacial surgery have advised that PRP application accelerated the speed and degree of bone formation in bone grafts for at least the first six months (32). Furthermore, it has been reported that PRP accelerated angiogenesis after surgical injury, subsequently resulting in soft tissue repair (33). Intestinal healing, however, is a rapid mechanism in which any improvement in the healing process by PRP application is perhaps less noticeable. The rate of turnover in the intestinal epithelium is very high, and the cell population in this tissue is replaced several times during the lifetime. Once injury happens, rapid recovery of the epithelial barrier and providing normal mucosal architecture is crucial (34). Fresno and colleagues reported that healing of intestinal lesions was accelerated with PRP in the acute phase. It can be concluded that application of PRP in musculoskeletal tissues induces cell proliferation and stimulates synthesis and secretion of angiogenic

factors that enhance healing processes (35).

Although the histological analysis in the PRP group evaluated one week after sphincteroplasty showed a significant improvement in the healing of the sphincter, electromyography for evaluation of sphincter muscle function is required for better analysis of the effects of PRP, which will be addressed in our future studies. On the other hand, despite our findings, this study had certain limitations. Although an appropriate negative control was created by withholding PRP application, the inflammatory effects of injection must be addressed by using an additional control group. Also, this work involved an animal model of a human disease, and there are certain interspecies differences. Therefore, human clinical trials are needed before our results can be generalized to the general population.

References

- Hong KD, Dasilva G, Kalaskar SN, Chong Y, Wexner SD (2013) Long-term outcomes of artificial bowel sphincter for fecal incontinence: a systematic review and meta-analysis. *Journal of the American College of Surgeons* 217 (4):718-725
- Damon H, Guye O, Seigneurin A, Long F, Sonko A, Faucheron J-L, Grandjean J-P, Mellier G, Valancogne G, Fayard M-O (2006) Prevalence of anal incontinence in adults and impact on quality-of-life. *Gastroentérologie clinique et biologique* 30 (1):37-43
- Faltin DL, Sangalli MR, Curtin F, Morabia A, Weil A (2001) Prevalence of anal incontinence and other anorectal symptoms in women. *International Urogynecology Journal* 12 (2):117-121
- Goode PS, Burgio KL, Halli AD, Jones RW, Richter HE, Redden DT, Baker PS, Allman RM (2005) Prevalence and correlates of fecal incontinence in community-dwelling older adults. *Journal of the American Geriatrics Society* 53 (4):629-635
- Quander CR, Morris MC, Melson J, Bienias JL, Evans DA (2005) Prevalence of and factors associated with fecal incontinence in a large community study of older individuals. *The American Journal of Gastroenterology* 100 (4):905-909
- Deutekom M, Dobben AC (2015) Plugs for containing faecal incontinence. *The Cochrane Library* 7:CD005086
- Burnett SJD, Spence-Jones C, Speakman CTM, Kamm MA, Hudson CN, Bartram CI (1991) Undisputed sphincter damage following childbirth revealed by anal endosonography. *The British Journal of Radiology* 64 (759):225-227
- Norton C, Whitehead WE, Bliss DZ, Harari D, Lang J (2010) Management of fecal incontinence in adults. *Neurourology and Urodynamics* 29 (1):199-206. doi:10.1002/nau.20803
- Trowbridge ER, Morgan D, Trowbridge MJ, Delancey JOL, Fenner DE (2006) Sexual function, quality of life, and severity of anal incontinence after anal sphincteroplasty. *American Journal of Obstetrics and Gynecology* 195 (6):1753-1757
- Meyer I, Richter HE (2016) Evidence-based update on treatments of fecal incontinence in women. *Obstetrics and Gynecology Clinics of North America* 43 (1):93-119
- Malouf AJ, Norton CS, Engel AF, Nicholls RJ, Kamm MA (2000) Long-term results of overlapping anterior anal-sphincter repair for obstetric trauma. *The Lancet* 355 (9200):260-265
- Gutierrez AB, Madoff RD, Lowry AC, Parker SC, Buie WD, Baxter NN (2004) Long-term results of anterior sphincteroplasty. *Diseases of the Colon & Rectum* 47 (5):727-732
- Fréchette J-P, Martineau I, Gagnon G (2005) Platelet-rich plasmas: growth factor content and roles in wound healing. *Journal of Dental Research* 84 (5):434-439
- Marx RE (2004) Platelet-rich plasma: evidence to support its use. *Journal of Oral and Maxillofacial Surgery* 62 (4):489-496
- Fabbro MD, Bortolin M, Taschieri S, Ceci C, Weinstein RL (2016) Antimicrobial properties of platelet-rich preparations. A systematic review of the current pre-clinical evidence. *Platelets* 27:276-285
- Lozada JL, Caplanis N, Proussaefs P, Willardsen J, Kammeyer G (2001) Platelet-rich plasma application in sinus graft surgery: Part I-Background and processing techniques. *Journal of Oral Implantology* 27 (1):38-42
- Esat DM, Temel S, Ozer H, Kemal UM, Kaya F, Aslan F, Celepli P, Senes M, Dogan K, Kuru S (2016) Comparison of the effects of platelet rich plasma prepared in various forms on the healing of dermal wounds in rats. *Wounds* 28 (3):99-108
- Van Der Hagen SJ, Baeten CG, Soeters PB, Van Gemert WG (2011) Autologous platelet-derived growth factors (platelet-rich plasma) as an adjunct to mucosal advancement flap in high cryptoglandular perianal fistulae: a pilot study. *Colorectal Disease* 13 (2):215-218
- Göttgens KW, Vening W, van der Hagen SJ, van Gemert WG, Smeets RR, Stassen LP, Baeten CG, Breukink SO (2014) Long-term results of mucosal advancement flap combined with platelet-rich plasma for high cryptoglandular perianal fistulas. *Diseases of the Colon & Rectum* 57 (2):223-227
- Carter MJ, Fylling CP, Parnell LK (2011) Use of platelet rich plasma gel on wound healing: a systematic review and meta-analysis. *Eplasty* 11:382-410
- Hulley SB, Cummings SR, Browner WS, Grady D, Newman TB (2013) *Designing clinical research : an epidemiologic approach*; Appendix 6A. 4th edn. PA: Lippincott Williams & Wilkins, Philadelphia
- Abbas MA, Tam MS, Chun LJ (2012) Radiofrequency treatment for fecal incontinence: is it effective long-term? *Diseases of the Colon & Rectum* 55

Conclusion

Application of PRP showed positive effects on sphincter healing in the acute phase after repair. Further investigations are required to clarify the optimum PRP concentration and time of usage that allows for maximum improvement of anastomotic wound healing.

Acknowledgement

The authors would like to express their sincere gratitude to Shiraz University of Medical Sciences for financially supporting the study.

Conflict of Interests: None declared.

- (5):605-610
23. Ghahramani L, Mohammadipour M, Roshanravan R, Hajihosseini F, Bananzadeh A, Izadpanah A, Hosseini SV (2016) Efficacy of biofeedback therapy before and after sphincteroplasty for fecal incontinence because of obstetric injury: A randomized controlled trial. *Iranian Journal of Medical Sciences* 41 (2):126-131
 24. Abramov Y, Golden B, Sullivan M, Botros SM, Miller JJR, Alshahrour A, Goldberg RP, Sand PK (2007) Histologic characterization of vaginal vs. abdominal surgical wound healing in a rabbit model. *Wound Repair and Regeneration* 15 (1):80-86
 25. Madoff RD, Rosen HR, Baeten CG, LaFontaine LJ, Cavina E, Devesa M, Rouanet P, Christiansen J, Faucheron J-L, Isbister W (1999) Safety and efficacy of dynamic muscle plasty for anal incontinence: lessons from a prospective, multicenter trial. *Gastroenterology* 116 (3):549-556
 26. Witte MB, Barbul A (1997) General principles of wound healing. *Surgical Clinics of North America* 77 (3):509-528
 27. Alsousou J, Ali A, Willett K, Harrison P (2013) The role of platelet-rich plasma in tissue regeneration. *Platelets* 24 (3):173-182. doi:10.3109/09537104.2012.684730
 28. Anitua E, Sánchez M, Orive G, Andia I (2007) The potential impact of the preparation rich in growth factors (PRGF) in different medical fields. *Biomaterials* 28 (31):4551-4560
 29. Everts PAM, van Zundert A, Schonberger JPAM, Devilee RJJ, Knape JTA (2008) What do we use: platelet-rich plasma or platelet-leukocyte gel? *Journal of Biomedical Materials Research Part A* 85 (4):1135-1136
 30. Ehrenfest DMD, Rasmusson L, Albrektsson T (2009) Classification of platelet concentrates: from pure platelet-rich plasma (P-PRP) to leucocyte-and platelet-rich fibrin (L-PRF). *Trends in Biotechnology* 27 (3):158-167
 31. Cohn CS, Lockhart E (2015) Autologous platelet-rich plasma: evidence for clinical use. *Current Opinion in Hematology* 22 (6):527-532
 32. Schliephake H (2015) Clinical efficacy of growth factors to enhance tissue repair in oral and maxillofacial reconstruction: a systematic review. *Clinical Implant Dentistry and Related Research* 17 (2):247-273
 33. Lyras DN, Kazakos K, Tilkeridis K, Kokka A, Ververidis A, Botaitis S, Agrogiannis G (2016) Temporal and spatial expression of TGF- β 1 in the early phase of patellar tendon healing after application of platelet rich plasma. *Archives of Bone and Joint Surgery* 4 (2):156-160
 34. An W-L, Cowburn RF, Li L, Braak H, Alafuzoff I, Iqbal K, Iqbal I-G, Winblad B, Pei J-J (2003) Up-regulation of phosphorylated/activated p70 S6 kinase and its relationship to neurofibrillary pathology in Alzheimer's disease. *The American Journal of Pathology* 163 (2):591-607. doi:10.1016/S0002-9440(10)63687-5
 35. Fresno L, Fondevila D, Bambo O, Chacaltana A, García F, Andaluz A (2010) Effects of platelet-rich plasma on intestinal wound healing in pigs. *The Veterinary Journal* 185 (3):322-327