

# Antioxidant and Anti-Inflammatory Effects of Gel and Aqueous Extract of *Melilotus officinalis* L. in Induced Ulcerative Colitis: A *Rattus norvegicus* Model

Ali Reza Safarpour<sup>1</sup>; Fatemeh Kaviyani<sup>2</sup>; Masood Sepehrimanesh<sup>1,\*</sup>; Nasrollah Ahmadi<sup>3</sup>; Omid Koochi Hosseinabadi<sup>4</sup>; Nader Tanideh<sup>2</sup>; Najmeh Showraki<sup>5</sup>

<sup>1</sup>Gastroenterohepatology Research Center, Shiraz University of Medical Sciences, Shiraz, IR Iran

<sup>2</sup>Transgenic Technology Research Center, Shiraz University of Medical Sciences, Shiraz, IR Iran

<sup>3</sup>Department of Pathology, School of Veterinary Medicine, Shiraz University, Shiraz, IR Iran

<sup>4</sup>Laboratory Animals Center, Shiraz University of Medical Sciences, Shiraz, IR Iran

<sup>5</sup>Department of Oral Medicine, School of Dentistry, Shiraz University of Medical Sciences, Shiraz, IR Iran

\*Corresponding author: Masood Sepehrimanesh, Gastroenterohepatology Research Center, Research Tower, Nemazee Teaching Hospital, Shiraz University of Medical Sciences, P. O. Box: 7193-51311, Shiraz, IR Iran. Tel: +98-7136281442, E-mail: sepehrimaneshmasood@gmail.com

Received: May 3, 2015; Revised: June 9, 2015; Accepted: June 12, 2015

**Background:** Ulcerative colitis (UC) is a chronic condition of intestine illness accompanied by some unknown etiology with different immune, genetic and environmental factors.

**Objectives:** The current study aimed to evaluate the antioxidant and anti-inflammatory effects of the *Melilotus officinalis* L. in the acetic acid induced UC in rats.

**Materials and Methods:** The plant aqueous extraction and high performance liquid chromatography and Ferric Reducing Antioxidant Power (FRAP) assay were performed on aqueous extract to identify its compounds and antioxidant activities. Also, 70 adult male rats were and UC was induced using 3% acetic acid solution. They received different daily doses of *M. officinalis* L. in two forms (orally, 500 and 1000 mg/kg) and gel extract (10% and 20%). On the 7th day, the colon tissues were examined regarding the macroscopic and histopathology lesions plus oxidative stress and compared to the positive and negative control groups.

**Results:** HPLC analysis revealed that five grams of the flower powder contained 9.7 mg gallic acid, 99 mg catechin, 21.9 mg caffeic acid, 0.86 mg chlorogenic acid, 1.13 mg quercetin, 548.9 mg cinnamic acid, 289 mg coumarin and 126 mg p-coumaric acid. The FRAP value of the extract was  $2.91 \pm 0.14 \mu\text{M/g}$ . There were significant differences between the group of rats which received the gel or aqueous extract of the flower compared to the negative control group using normal saline and the base gel and they had no significant differences with the positive control group using the Asacol, regarding the pathologic, malondialdehyde, and weight improvements.

**Conclusions:** It can be concluded that the *M. officinalis* L. extract can be used as an effective medicine to treat UC in animal model and also in human subjects.

**Keywords:** Colitis, Ulcerative; Inflammation; Extract; Ulcerative Colitis; Asacol

## 1. Background

Inflammatory bowel diseases (IBD), including Crohn's disease (CD) and ulcerative colitis (UC) are chronic inflammatory disease of the gastrointestinal tract. In fact, UC is a relapsing non-transmural inflammatory disease restricted to the colon and is one of the idiopathic diseases of IBD (1). The incidence of UC remained stable over the past 30 years, but, the disease become more prevalent due to the early age of onset and low mortality, albeit with significant morbidity (2-4). The etiologies of the IBD are unknown and therefore there are no causal treatments. In addition, patients with UC have substantial impairments in health-related quality of life (QoL) due to their symptoms, particularly during periods of disease activity (5). On the other hand, the current treatment is not completely successful and it is frequently connected with adverse effects (6). It is sug-

gested that the plant and its products may provide an option for the alternative or supplementary treatment of the patients with IBD (7).

There are several ways to induce UC in the animal model; they include using trinitrobenzene sulfonic acid (TNBS) (8), dextran sulfate sodium (9), and acetic acid (10, 11). Induction of UC using acetic acid had no mortality and the general health of the rats was similar to that of the controls (12). Therefore, this method is widely suggested as a useful model for the studies on the pathophysiology and treatment of UC and it was performed in the current study.

A number of traditional plants were reported in the literature, but there was little scientific effort to validate their effects. One of them is the genus of *Melilotus*, family of Fabaceae. Data regarding traditional phytotherapy

show that the *Melilotus* species (sweet clover) were used to reduce spasm, in the liver diseases and as a diuretic (13). *Melilotus officinalis* L. also named yellow sweet clover is a plant not only used as food and forage but also as a medicine. The preventive effect of the whole plant extract on the experimental atherosclerosis in rabbits was reported (14). However, the number of reports on the *M. officinalis* L. application in animal and human diseases is scarce and there are no reports on the efficacy of *M. officinalis* L. in UC treatment.

## 2. Objectives

The current study aimed to determine the healing effects of *M. officinalis* L. as dietary and gel form and compare them with that of Asacol on the tissue histopathological changes and malondialdehyde (MDA) level in male rats with experimentally acetic acid induced UC.

## 3. Materials and Methods

### 3.1. Ethical Statement

This study was approved by the animal care and use committee of Shiraz university of medical sciences, Shiraz, Iran. All efforts were made to prevent any unnecessary and harmful animal handling.

### 3.2. Plant Materials and Aqueous Extraction

*Melilotus officinalis* L. was collected from the Productive Farm of Baradan Medicinal Plant Co., Abadeh, Iran (GPS coordinates: 31.160833, 52.650556, with Altitude of 2500 m) during the spring season (May, 2013). All plants were in the flowering stage of developing and the taxonomic identification of each plant was confirmed by the Fars agriculture Jihad educational complex, Fars, Iran and the local herbarium number 14684. The plant also matched with the digital herbarium of Botanical Garden and Botanical Museum Berlin-Dahlem, Freie university, Berlin (<http://ww2.bgbm.org/herbarium/>) (Barcode: B -W 14163-01 0 / Imaged: 385175).

### 3.3. Aqueous Extraction

The provided plants were dried for five days at room temperature and then powdered by grinder. Finally, 100 g of plant powder was used for aqueous extraction based on previous reported procedures (15).

### 3.4. High Performance Liquid Chromatography (HPLC)

Phenolic acid constituents of *M. officinalis* L. were identified by high performance liquid chromatography (HPLC) according to the method reported by Kwok et al. (16), with some modifications. Briefly, 5 g of plant powder was dissolved in 50 mL of HPLC grad water and after 24 hours, the solution was filtered across 0.22 µm

filter. HPLC analyses were performed using an Agilent 1200 HPLC system (Milford, MA, USA) coupled to a photodiode array detector. The samples were separated on a reversed-phase C18 column (150 mm × 4.6 mm). The mobile phase consisted of water (solvent A) and formic acid (solvent B). At time = 0, the solvent A and B were in 1:9 (v/v) ratio. The gradient mobile phase was gradually changed to 89:11 (v/v) A to B ratio in 20 minutes. Mobile phase rate was 1 mL/minute and the column temperature was adjusted at 30°C. The eluent was monitored by a UV detector and the detection wavelength was set at 280 and 360 nm. Galic acid, chlorogenic acid, caffeic acid, quercetin, cumarin, p-cumaric acid, and carvacrol were used as internal standards.

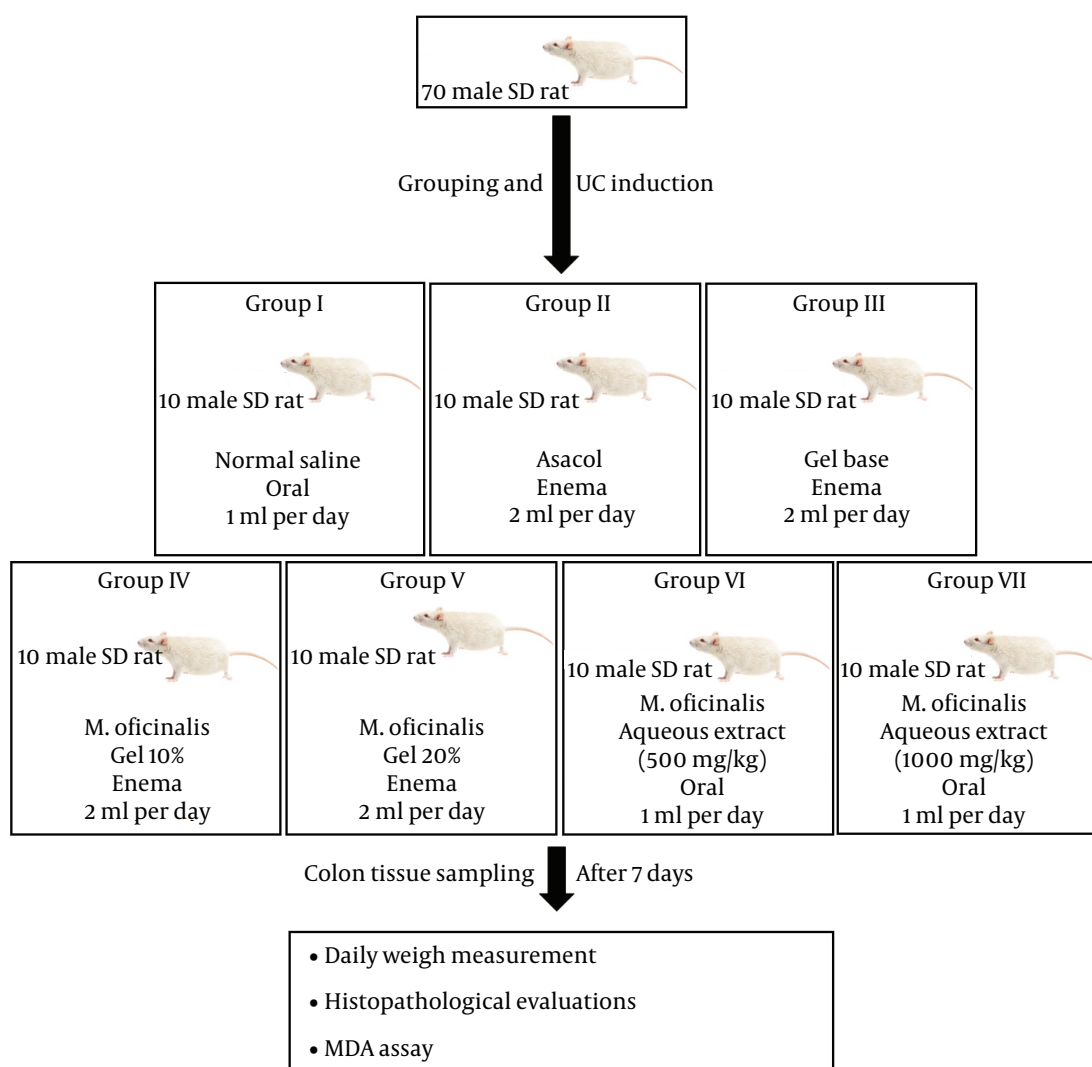
### 3.5. Ferric Reducing Antioxidant Power Assay

FRAP assay was performed on aqueous extract according to the previous methods (17, 18) with some modifications. A 20 µL sample of extract with different concentrations, 31.25, 62.5, 125, 250, 500 mM and 1 M was mixed with 180 µL of FRAP reagent in the pale wells. Blank samples also were prepared; then, both real and blank samples were incubated in water bath for 10 minutes at 37°C and the absorbance of the samples was determined against blank ones at 593 nm. Series of stock solution at 12.5, 25, 50, 100 and 200 µg/mL were prepared ( $r^2 = 0.999$ ) using aqueous solution of  $\text{FeSO}_4 \cdot 7\text{H}_2\text{O}$  as the standard curve. The values obtained were expressed as nanomole (µM) of ferrous equivalent Fe (II) per gram of freeze dried sample.

### 3.6. Animal Housing, UC Induction and Treatment

Seventy 250 - 280 g male Sprague Dawley rats were purchased from the Laboratory Animals Center, Shiraz University of Medical Sciences. Animals were randomly allocated into seven equal independent groups and treated according to the procedure shown in Figure 1.

UC was induced according to the previously reported protocols (10, 11). Briefly, all animals were fasted overnight and their bowels were cleaned before induction of colitis. A polyurethane cannula (2 mm diameter) was applied for the rectal entrance of acetic acid and the tip was inserted up to 8 cm proximal to the anus verge. Two milliliters of 3% acetic acid was administered transrectally into the colon by a cannula during 30 seconds to induce UC under ketamine and xylazine anesthesia. The main substance of gel was carboxymethyl cellulose (CMC) and the gel was produced by mixing 2% sodium CMC in 5% glycerol and it was continuously stirred with a mixer in order to prepare a gel-forming agent. In the next step, *M. officinalis* L. extracts (10%, and 20%) were added to deionized water. The mixtures were gradually added to the Na-CMC with glycerol and finally the prepared gel was homogenized for 30 minutes and all formulations were collected in an aluminum tube in the refrigerator (11).



**Figure 1.** Experimental Setup and Rat Groupings

### 3.7. Tissue Sampling, Macroscopic and Microscopic Evaluations

After seven days, rats were euthanized under deep ether anesthesia. Then, the distal 8 cm of the colon was removed and opened by longitudinal incision. The mucosal surface was washed with saline buffer and the mucosal injury was macroscopically assessed using Morris et al. (19) grading scale. Colon tissue was processed and stained according to the previously reported procedures (10, 20-25). Briefly, colon tissues were free of surrounding fat and fixed in 10% buffered formalin solution for histopathological examination. Formalin-fixed tissues were processed routinely and embedded in paraffin. Blocks were cut at 5  $\mu$ m and stained with hematoxylin-eosin. All sections were studied and photographed using a light microscope. The degree of inflammation of the colon was graded as previously described (26).

### 3.8. Malondialdehyde Measurement

Colon tissue MDA assessment was performed by measuring thiobarbituric acid reactive substances (TBARS) in PBS tissue homogenate (27); since MDA is one of the end-products of lipid peroxidation (LPO), and the extent of LPO is most frequently measured by estimating MDA levels (28).

### 3.9. Statistical Analysis

The results were presented as mean. Differences among the groups were determined using a one-way ANOVA and Duncan post-hoc test. All the statistical analyses were performed by SPSS software (version 18, Chicago, IL, USA). P value less than 0.05 was considered significant.

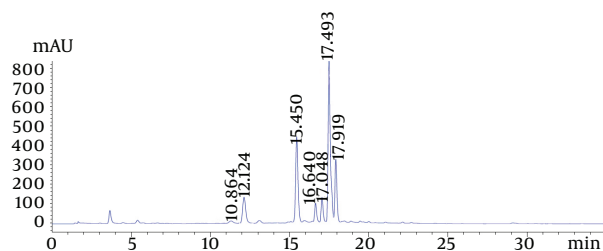
## 4. Results

The current study aqueous extraction efficiency was

39%. Chromatogram of *M. officinalis* L. in 280 nm is shown in Figure 2. As demonstrated, the comarin had the highest concentration in the *M. officinalis* L. phenolic acid constituents; and comarin levels in aqueous extract of *M. officinalis* L. are presented in Table 1. Catechin and cinnamic acid were the highest compounds in the phenolic acid and comarin constituents of *M. officinalis* L. Antioxidant activity of aqueous extract of *M. officinalis* L. was measured based on the FRAP assay.

The current study analysis demonstrated that the FRAP value for this extract was  $2.91 \pm 0.14 \mu\text{M/g}$ . Percentage of weight changes in different groups during the experimental period is shown in Figure 3. The most weight change was observed in the normal saline control group (13.67%), while, the lowest weight changes were observed in the Asacol control, 20% extract enema, and 1000 mg oral extract with 1.44%, 1.62%, and 2.31%, respectively.

Mean comparison of macroscopic and microscopic changes as quantitative values plus MDA level in different groups are presented in Table 2. As observed, normal saline control group had the highest and Asacol control, 20% extract enema, and 1000 mg oral extract showed the lowest pathological changes in both macroscopic and microscopic evaluations. Also, changes of MDA levels in response to different treatments indicated the antioxidant activity of *M. officinalis* L. extract. The lowest MDA level (highest antioxidant level) was detected in the gel 20% in enema route of administration, which was comparable to that of Asacol treatment (Table 2).

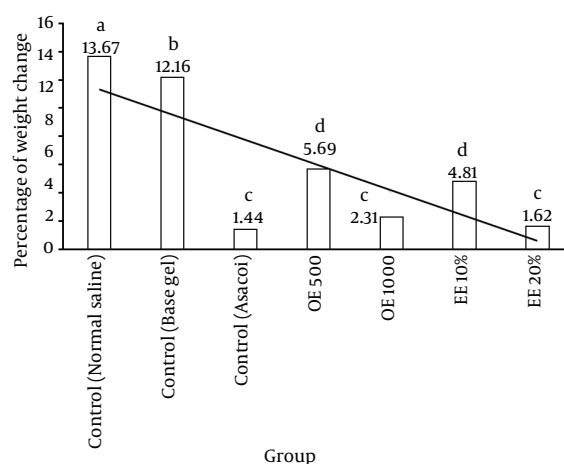


**Figure 2.** Chromatogram of Aqueous *Melilotus officinalis* Extract Provided by High Performance Liquid Chromatography

**Table 1.** Characterization of *Melilotus officinalis* Compounds by High Performance Liquid Chromatography

| Compounds                      | Level (mg/L) |
|--------------------------------|--------------|
| <b>Phenolic acid compounds</b> |              |
| Gallic acid                    | 9.75         |
| Catechin                       | 99.06        |
| Caffeic acid                   | 21.99        |
| Chloregenic acid               | 0.87         |
| Quercetin                      | 1.13         |
| <b>Comarin compounds</b>       |              |
| Cinnamic acid                  | 548.91       |
| Comarin                        | 289.00       |
| p-comaric acid                 | 126.00       |
| Rutin                          | -            |
| Carvacerol                     | -            |

**Figure 3.** Rate of Weight Change and its Trend in Different Groups During the Study Period



Differences among the groups were determined using a one-way ANOVA and Duncan post-hoc test. Significant difference between the groups is indicated by different superscript letters ( $P < 0.05$ ).

**Table 2.** Comparison Between Macroscopic and Microscopic Scores Plus Malondialdehyde Levels in Different Experimental Groups<sup>a,b</sup>

| Groups                              | Macroscopic Score | Microscopic Score b | MDA Level ( $\mu\text{M}$ ) |
|-------------------------------------|-------------------|---------------------|-----------------------------|
| <b>Control groups</b>               |                   |                     |                             |
| Normal saline                       | 19.0              | 10.7                | 1.80                        |
| Base gel                            | 18.1              | 9.9                 | 1.75                        |
| Asacol                              | 1.9               | 1.2                 | 0.93                        |
| <b><i>Melilotus officinalis</i></b> |                   |                     |                             |
| 500 mg/kg oral extract              | 8.2               | 4.7                 | 1.13                        |
| 1000 mg/kg oral extract             | 2.1               | 1.0                 | 1.00                        |
| 10% gel enema                       | 7.5               | 4.2                 | 1.13                        |
| 20% gel enema                       | 1.8               | 0.8                 | 0.93                        |

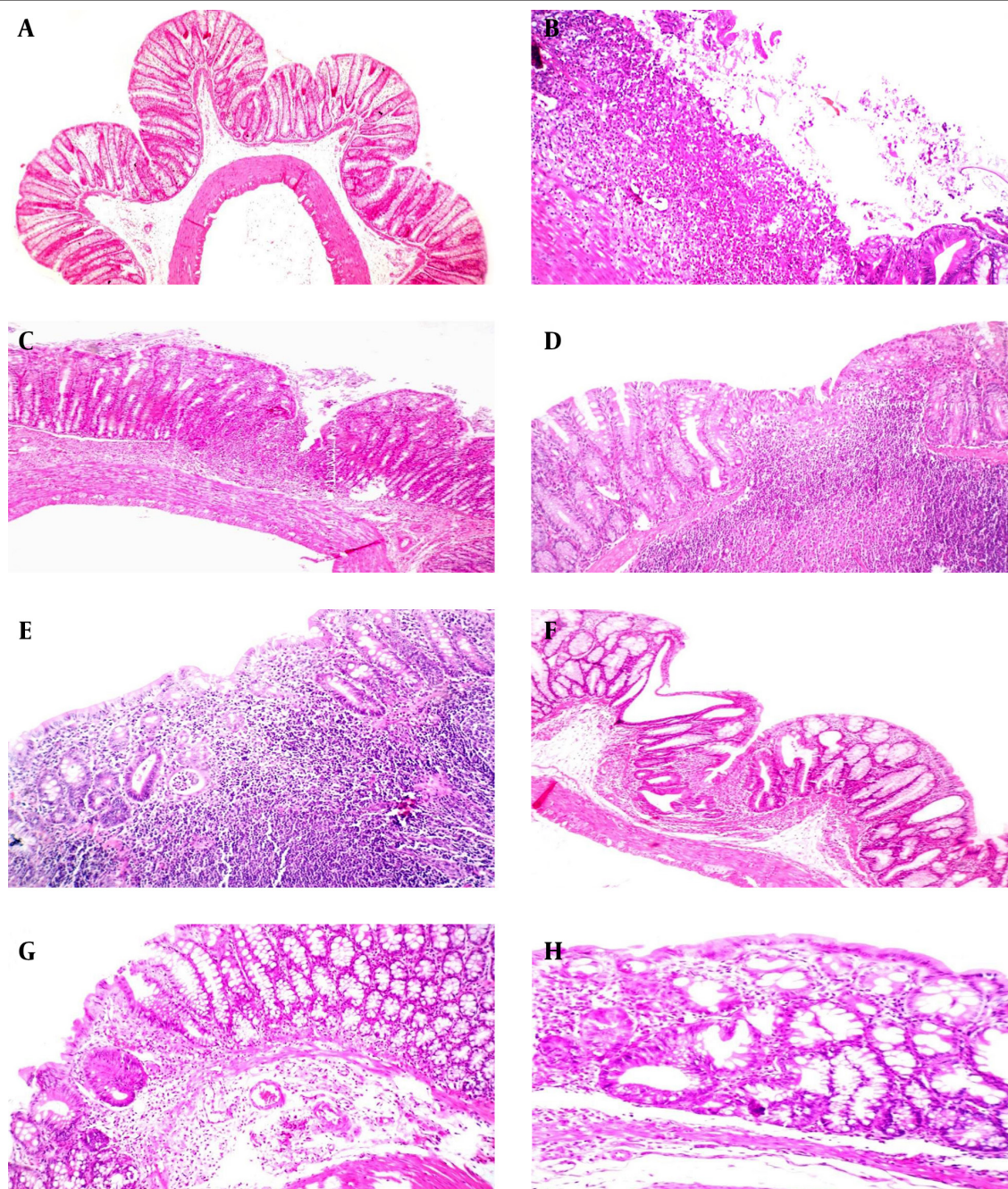
<sup>a</sup> Differences among the groups were determined using a one-way ANOVA and Duncan post-hoc test.

<sup>b</sup> Significance:  $P < 0.05$ .

Comparison of histopathological lesions in the colon tissue of healthy rats and seven different experimental groups are shown in Figure 4. As indicated, acetic acid induced UC in the colon, demonstrated by lack of epithelial cells plus infiltration of inflammatory cells in the sub-

mucosal layers. However, by administration of oral and enema of *M. officinalis* L., the healing process of the colon tissue was improved and using 1000 mg/kg oral aqueous extract or gel 20% enema can completely cure the colon tissue, comparable to Asacol treatment.

**Figure 4.** Histopathological Evaluations of the Colon Tissues



A, healthy rat colon with complete crypt, submucosal layer and muscular layer plus healthy epithelium; B, normal saline control group, lack of epithelial cells plus inflammatory cells infiltration; C, base gel control group, damage of epithelium and inflammation of subepithelial layers; D, 500 mg/kg oral aqueous extract of *Melilotus officinalis*, formation of epithelial cells but existence of inflammatory cells in the submucosal layers; E, enema of *Melilotus officinalis* L. 10% gel, formation of epithelial cells but existence of inflammatory cells in the submucosal layers; F, enema of *M. officinalis* L. 20% gel, approximately complete formation of epithelial cells plus crypts and muscularis mucosa formation, mild inflammation of the submucosal layers; G, 1000 mg/kg oral aqueous extract of *Melilotus officinalis* L., complete formation of epithelial cells, crypts and muscularis mucosa, very mild inflammation of the submucosal layers; H, Asacol control group, complete formation of epithelial cells, crypts and muscularis mucosa without any inflammation (H&E staining).

## 5. Discussion

The current study compared the healing effects of *M. officinalis* L. extract in the 500 and 1000 mg/kg orally and 10% and 20% gel forms against acetic acid induced UC by measuring tissue histopathology and MDA level in rats. Also, the phenolic acid compounds of the plant and antioxidant activity of aqueous extract were determined using HPLC and FRAP test. The analysis revealed that catechin and cinnamic acid were the highest phenolic acid and comarin constituents of this plant. Also findings of the current study demonstrated that both dietary and gel forms had significant obvious healing effects and these effects were dose dependent. However, the antioxidant activity of the 20% gel in enema rout was clearly higher than those of the other concentrations and routs of administration.

Although, the UC symptoms can sometimes reduce their own, the disease usually requires treatment to go into remission. There are several strategies to treat UC including pharmacotherapy (aminosalicylates, glucocorticoids, immunosuppressive) and surgical procedures, but the current therapies are not completely successful and frequently cause adverse effects (7). Anti-inflammatory drugs, such as aminosalicylates, corticosteroids and immunosuppressive agents, were frequently applied to treat this disease. However, there were serious side effects and the recrudescence rates of IBD were rather high (29, 30). Therefore, scientists noticed the use of medicinal plants as alternative or complementary therapies for UC. The current study authors previously reported the beneficial effects of some medicinal plants in different animal species. The plants included *Pistacia atlantica* (11), *Berberis vulgaris* (31), strawberry (32) and *Hypericum perforatum* (10) in rats and *Teucrium polium* (33) and *Calendula officinalis* (34) in dogs. However, no reports were issued on the healing effects and antioxidant properties of *M. officinalis* L. extract and its mechanism on UC until now.

Authors found that the aqueous extract of *M. officinalis* L. contained high level of catechin and cinnamic acid as the phenolic acid and comarin compounds. Catechin is a type of natural phenol and antioxidant found in medicinal plants Catechins is reported to have anti-inflammatory effects on TNBS and acetic acid induced rat colitis (35, 36). This may be through selective immunomodulatory effects mediated, at least in part, by inhibition of nuclear factor- $\kappa$ B (NF- $\kappa$ B) and activator protein-1 (37). It is clarified that catechins can exert their antioxidant activities via decreasing nitric oxide, MDA, and increasing superoxide dismutase. They also ameliorate mucosal inflammation by inhibiting the production of TNF- $\alpha$ , IFN- $\gamma$  and NF- $\kappa$ Bp65 (36). The current study findings regarding beneficial anti-colitis activities of *M. officinalis* L. are in line with the above mentioned reports. It can be concluded that catechin, with the highest amount of phenolic acid compound in the plant extract, plays antioxidant and anti-inflammatory activities due to the reported mechanisms.

Finally, MDA is frequently used to measure lipid perox-

ide levels and, exhibiting good correlation with degree of lipid peroxidation. In the present study, the MDA levels decreased in all *M. officinalis* L. treated groups compared with those of the control groups. This decrease may in fact support the protective effect of *M. officinalis* L. against lipid peroxidation in UC. Although, scientific information concerning antioxidant properties of the *M. officinalis* L. extract is still rather scarce (13), such effects against lipid peroxidation were previously reported in cell culture experiments (38).

In conclusion, the mucus layer contributes significantly to gut barrier function and protection from pathogens (39) and the current findings are interesting as a strategy to select the medicinal plants to treat UC. The antioxidant and anti-inflammatory effects of *M. officinalis* L. extract seem to be clear, especially by identifying catechin and cinnamic acid as the most phenolic acid and comarin constituents, but its molecular anti-inflammatory mechanisms are not fully investigated yet. Therefore, performing further studies to identify this mechanism in cell culture and also animal and human studies are highly recommended.

## Acknowledgements

The animals were kindly provided by Mahjoob Vahedi at the Laboratory Animals Center, Shiraz University of Medical Sciences, Shiraz, Iran. Authors wish to thank all people who kindly helped with the technical and scientific phases of this study.

## Authors' Contributions

Ali Reza Safarpour: Study concept and design, analysis and interpretation of data, critical revision of the manuscript for important intellectual content; Fatemeh Kaviyani: Gathering, analysis and interpretation of data, Drafting the manuscript; Masood Sepehrimanesh: Gathering, analysis and interpretation of data, drafting the manuscript, critical revision of the manuscript for important intellectual content, statistical analysis, administrative, technical, and material support, study supervision; Nasrollah Ahmadi: Data gathering, study supervision; Omid Koochi Hosseinabadi: Gathering, analysis and interpretation of data, drafting the manuscript; Nader Tanideh: Study concept and design, drafting the manuscript, critical revision of the manuscript for important intellectual content, study supervision.

## Funding/Support

The study was supported by Shiraz University of Medical Sciences, Shiraz, IR Iran.

## References

1. Baumgart DC, Sandborn WJ. Inflammatory bowel disease: clinical aspects and established and evolving therapies. *Lancet*. 2007;**369**(9573):1641-57.

2. Loftus CG, Loftus EJ, Harmsen WS, Zinsmeister AR, Tremaine WJ, Melton L3, et al. Update on the incidence and prevalence of Crohn's disease and ulcerative colitis in Olmsted County, Minnesota, 1940-2000. *Inflamm Bowel Dis*. 2007;**13**(3):254-61.
3. Safarpour AR, Hosseini SV, Mehrabani D. Epidemiology of inflammatory bowel diseases in Iran and Asia; a mini review. *Iran J Med Sci*. 2013;**38**(2 Suppl):140-9.
4. Taghavi SA, Safarpour AR, Hosseini SV, Noroozi H, Safarpour M, Rahimikazerouni S. Epidemiology of Inflammatory Bowel Diseases (IBD) in Iran: A Review of 740 Patients in Fars Province, Southern Iran. *Ann Colorectal Res*. 2013;**1**(1):17-22.
5. Casellas F, Arenas JI, Baudet JS, Fabregas S, Garcia N, Gelabert J, et al. Impairment of health-related quality of life in patients with inflammatory bowel disease: a Spanish multicenter study. *Inflamm Bowel Dis*. 2005;**11**(5):488-96.
6. Biasi F, Astegiano M, Maina M, Leonarduzzi G, Poli G. Polyphenol supplementation as a complementary medicinal approach to treating inflammatory bowel disease. *Curr Med Chem*. 2011;**18**(31):4851-65.
7. Vochyanova Z, Bartosova L, Bujdakova V, Fictum P, Husnik R, Suchy P, et al. Diplacone and mimulone ameliorate dextran sulfate sodium-induced colitis in rats. *Fitoterapia*. 2015;**101**:201-7.
8. Mascaraque C, Gonzalez R, Suarez MD, Zarzuelo A, Sanchez de Medina F, Martinez-Augustin O. Intestinal anti-inflammatory activity of apigenin K in two rat colitis models induced by trinitrobenzenesulfonic acid and dextran sulphate sodium. *Br J Nutr*. 2015;**113**(4):618-26.
9. Boussenna A, Cholet J, Goncalves-Mendes N, Joubert-Zakeyh J, Fraisse D, Vasson MP, et al. Polyphenol-rich grape pomace extracts protect against dextran sulfate sodium-induced colitis in rats. *J Sci Food Agric*. 2015.
10. Tanideh N, Nematollahi SL, Hosseini SV, Hosseinzadeh M, Mehrabani D, Safarpour A, et al. The Healing Effect of Hypericum perforatum Extract on Acetic Acid-Induced Ulcerative Colitis in Rat. *Ann Colorectal Res*. 2014;**2**(4):e25188.
11. Tanideh N, Masoumi S, Hosseinzadeh M, Safarpour AR, Erjaee H, Koochi-Hosseinebadi O, et al. Healing effect of pistacia atlantica fruit oil extract in acetic Acid-induced colitis in rats. *Iran J Med Sci*. 2014;**39**(6):522-8.
12. Fabia R, Willen R, Ar'Rajab A, Andersson R, Ahren B, Bengmark S. Acetic acid-induced colitis in the rat: a reproducible experimental model for acute ulcerative colitis. *Eur Surg Res*. 1992;**24**(4):211-25.
13. Plesca-Manea L, Parvu AE, Parvu M, Taamas M, Buia R, Puia M. Effects of Melilotus officinalis on acute inflammation. *Phytother Res*. 2002;**16**(4):316-9.
14. Hirakawa T, Okawa M, Kinjo J, Nohara T. A new oleanene glucuronide obtained from the aerial parts of Melilotus officinalis. *Chem Pharm Bull (Tokyo)*. 2000;**48**(2):286-7.
15. Kazempour N, Nikbin M, Davarimanes M, Sepehrmanesh M. Antioxidant activity and mineral element contents of Calotropis procera from Iran: a traditional medicinal plant in Middle East. *Comp Clin Pathol*. 2014:1-4.
16. Kwok C, Wong CN, Yau MY, Yu PH, Au ALS, Poon CC, et al. Consumption of dried fruit of Crataegus pinnatifida (hawthorn) suppresses high-cholesterol diet-induced hypercholesterolemia in rats. *J Funct Foods*. 2010;**2**(3):179-86.
17. Kazempour N, Nikbin M, Maghsoudlou MT, Sepehrmanesh M. Antioxidant properties of extracts of Scutellaria lute-caerulea In vitro. *Online J Vet Res*. 2014;**18**(2):75-81.
18. Benzie IF, Strain JJ. Ferric reducing/antioxidant power assay: direct measure of total antioxidant activity of biological fluids and modified version for simultaneous measurement of total antioxidant power and ascorbic acid concentration. *Methods Enzymol*. 1999;**299**:15-27.
19. Morris GP, Beck PL, Herridge MS, Depew WT, Szewczuk MR, Wallace JL. Hapten-induced model of chronic inflammation and ulceration in the rat colon. *Gastroenterology*. 1989;**96**(3):795-803.
20. Tamadon A, Nikahval B, Sepehrmanesh M, Mansourian M, Naeini AT, Nazifi S. Epididymis ligation: a minimally invasive technique for preparation of teaser rams. *Vet Surg*. 2010;**39**(1):121-7.
21. Sepehrmanesh M, Azarpira N, Saeb M, Nazifi S, Kazempour N, Koochi O. Pathological changes associated with experimental 900-MHz electromagnetic wave exposure in rats. *Com Clin Pathol*. 2014;**23**(5):1629-31.
22. Panahi M, Karimaghai N, Rahmanifar F, Tamadon A, Vahdati A, Mehrabani D, et al. Stereological evaluation of testes in busulfan-induced infertility of hamster. *Comp Clin Pathol*. 2014:1-6.
23. Koochi-Hosseinebadi O, Moini M, Safarpour A, Derakhshanfar A, Sepehrmanesh M. Effects of dietary Thymus vulgaris extract alone or with atorvastatin on the liver, kidney, heart, and brain histopathological features in diabetic and hyperlipidemic male rats. *Comp Clin Pathol*. 2015:1-5.
24. Rajaian H, Nazifi S, Mansourian M, Poorbaghi SL, Sepehrmanesh M, Ghezelbash A. Pathological changes associated with experimental salinomycin toxicosis in calves. *Online J Vet Res*. 2008;**12**:15-22.
25. Tafti AK, Nazifi S, Rajaian H, Sepehrmanesh M, Poorbaghi SL, Mohtarami S. Pathological changes associated with experimental salinomycin toxicosis in sheep. *Com Clin Pathol*. 2008;**17**(4):255-8.
26. Shamsa F, Ahmadiani A, Khosrokhavar R. Antihistaminic and anticholinergic activity of barberry fruit (Berberis vulgaris) in the guinea-pig ileum. *J Ethnopharmacol*. 1999;**64**(2):161-6.
27. Koochi-Hosseinebadi O, Andisheh-Tadmir A, Bahadori P, Sepehrmanesh M, Mardani M, Tanideh N. Comparison of the therapeutic effects of the dietary and topical forms of Zizyphus jujuba extract on oral mucositis induced by 5-fluorouracil: a golden hamster model. *J Clin Exp Dent*. 2015;**7**:e304-9.
28. Lata H, Ahuja GK, Narang AP, Walia L. Effect of immobilisation stress on lipid peroxidation and lipid profile in rabbits. *Indian J Clin Biochem*. 2004;**19**(2):1-4.
29. Abdallah DM, Ismael NR. Resveratrol abrogates adhesion molecules and protects against TNBS-induced ulcerative colitis in rats. *Can J Physiol Pharmacol*. 2011;**89**(11):811-8.
30. Liu X, Wang J. Anti-inflammatory effects of iridoid glycosides fraction of Folium syringae leaves on TNBS-induced colitis in rats. *J Ethnopharmacol*. 2011;**133**(2):780-7.
31. Tanideh N, Afaridi E, Mehrabani D, Azarpira N, Hosseinzadeh M, Amini M, et al. The Healing Effect of Berberis vulgaris in Acetic Acid-Induced Ulcerative Colitis in Rat. *Middle East J Sci Res*. 2014;**21**(8):1288-94.
32. Tanideh N, Akbari Baseri F, Jamshidzadeh A, Ashraf MJ, Kuhi O, Mehrabani D. The healing effect of strawberry extract on acetic acid-induced ulcerative colitis in rat. *World Appl Sci J*. 2014;**31**(3):281-8.
33. Mehrabani D, Bahrami F, Hosseini SV, Ashraf MJ, Tanideh N, Rezaianzadeh A, et al. The Healing Effect of Teucrium polium in Acetic Acid-Induced Ulcerative Colitis in the Dog as an Animal Model. *Middle East J Dig Dis*. 2012;**4**(1):40-7.
34. Mehrabani D, Ziaei M, Hosseini SV, Ghahramani L, Bananzadeh AM, Ashraf MJ, et al. The effect of calendula officinalis in therapy of acetic Acid induced ulcerative colitis in dog as an animal model. *Iran Red Crescent Med J*. 2011;**13**(12):884-90.
35. Sato K, Kanazawa A, Ota N, Nakamura T, Fujimoto K. Dietary supplementation of catechins and alpha-tocopherol accelerates the healing of trinitrobenzene sulfonic acid-induced ulcerative colitis in rats. *J Nutr Sci Vitaminol (Tokyo)*. 1998;**44**(6):769-78.
36. Ran ZH, Chen C, Xiao SD. Epigallocatechin-3-gallate ameliorates rats colitis induced by acetic acid. *Biomed Pharmacother*. 2008;**62**(3):189-96.
37. Abboud PA, Hake PW, Burroughs TJ, Odoms K, O'Connor M, Mangeshkar P, et al. Therapeutic effect of epigallocatechin-3-gallate in a mouse model of colitis. *Eur J Pharmacol*. 2008;**579**(1-3):411-7.
38. Braga PC, Dal Sasso M, Lattuada N, Marabini L, Calo R, Antonacci R, et al. Antioxidant activity of Melilotus officinalis extract investigated by means of the radical scavenging activity, the chemiluminescence of human neutrophil bursts and lipoperoxidation assay. *J Med Plant Res*. 2013;**7**(7):358-65.
39. Yazdani A, Poorbaghi SL, Habibi H, Nazifi S, Rahmani Far F, Sepehrmanesh M. Dietary Berberis vulgaris extract enhances intestinal mucosa morphology in the broiler chicken (Gallus gallus). *Comp Clin Pathol*. 2013;**22**(4):611-5.